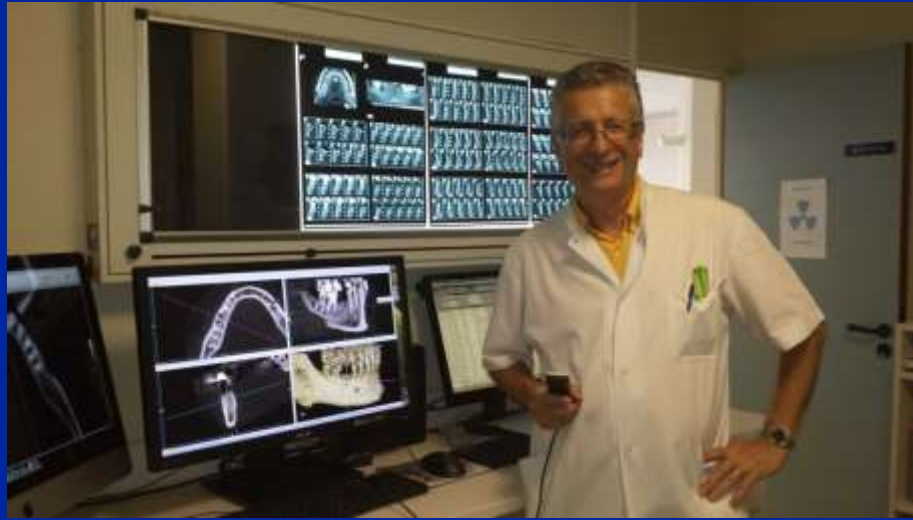

CONE BEAM EN ODONTOSTOMATOLOGIE: 100 IMAGES CLES



En Médecine, on ne trouve que ce que l'on cherche
et l'on ne cherche que ce que l'on connaît....

Toute connaissance vient de l'expérience,
le reste n'est qu'information (A. Einstein)

Toute exploration radiologique exige un commentaire;
toute image pathologique doit être confrontée à la clinique.

2016. 1^{ère} PARTIE

Dr Norbert BELLAICHE
Radiologue, Paris
www.conebeamparis.com

100 images clés en CBCT

- Implantologie
- Pathologie des 3èmes molaires
- Pathologie ODF
- Pathologie endodontique
- Pathologie parodontale
- Ostéites des maxillaires
- Pathologie traumatique dento-alvéolaire
- Pathologie des ATM
- Pathologie dentosinusienne
- Images claires et denses des maxillaires

IMPLANTOLOGIE ORALE

TECHNIQUES DISPONIBLES

.PANORAMIQUE DENTAIRE: approche de la hauteur disponible

.CONE BEAM: méthode de référence :

- . plus précise

- . moins irradiante, artéfactante, coûteuse que la TDM.

.SCANNER (TDM): 4 indications en imagerie dentaire

- .Artéfacts cinétiques en Cone Beam

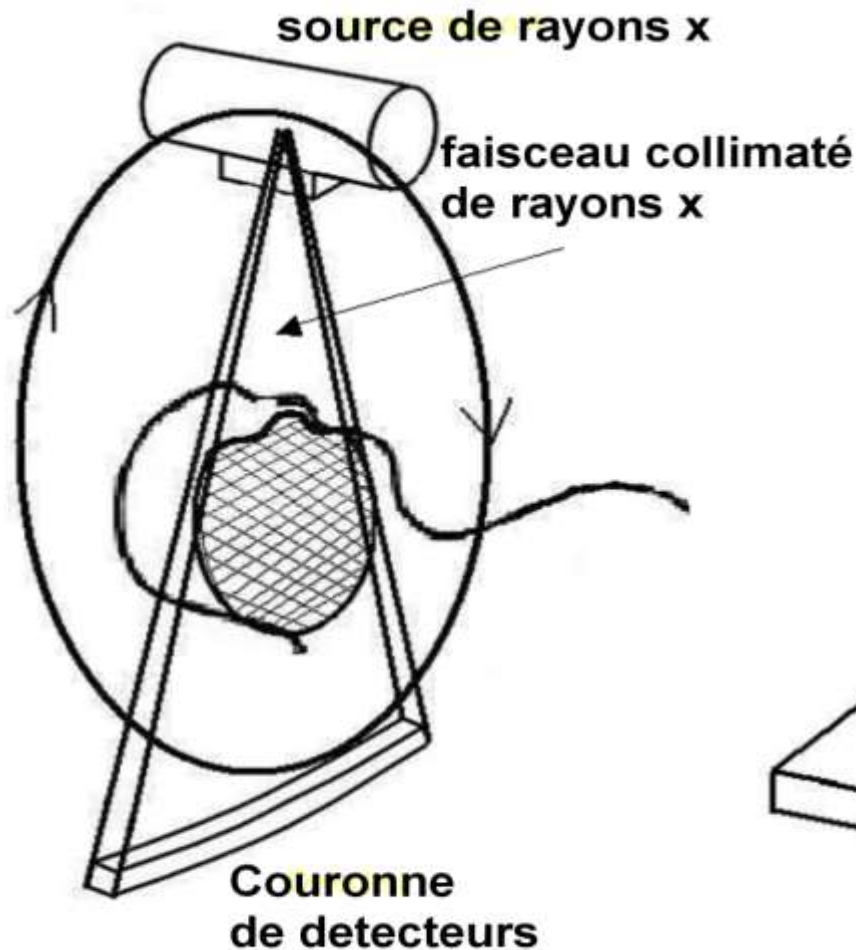
- .Etude des parties molles

- .Traumatismes graves

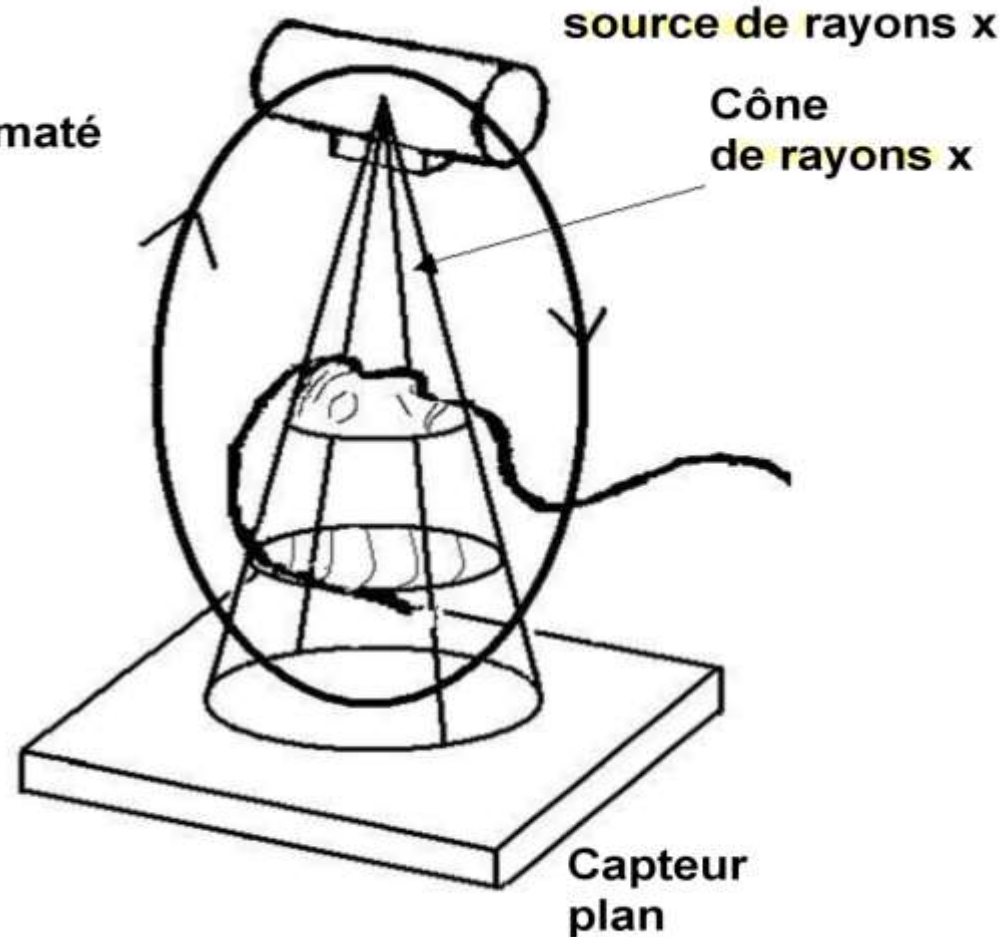
- .Suspicion de pathologie tumorale maligne

TOMOGRAPHIE A FAISCEAU CONIQUE et SCANNER: PRINCIPES

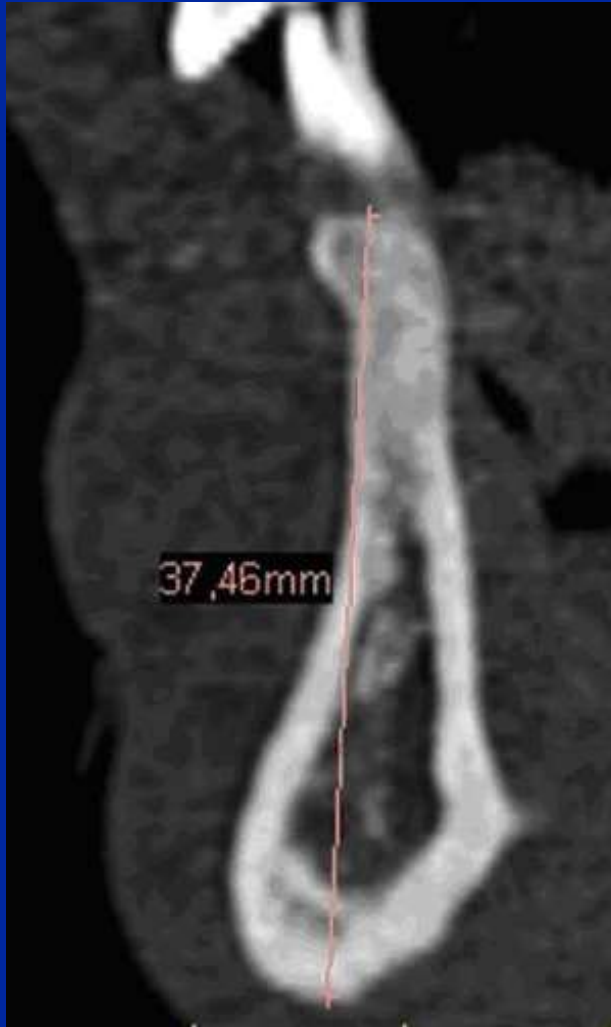SCANNER



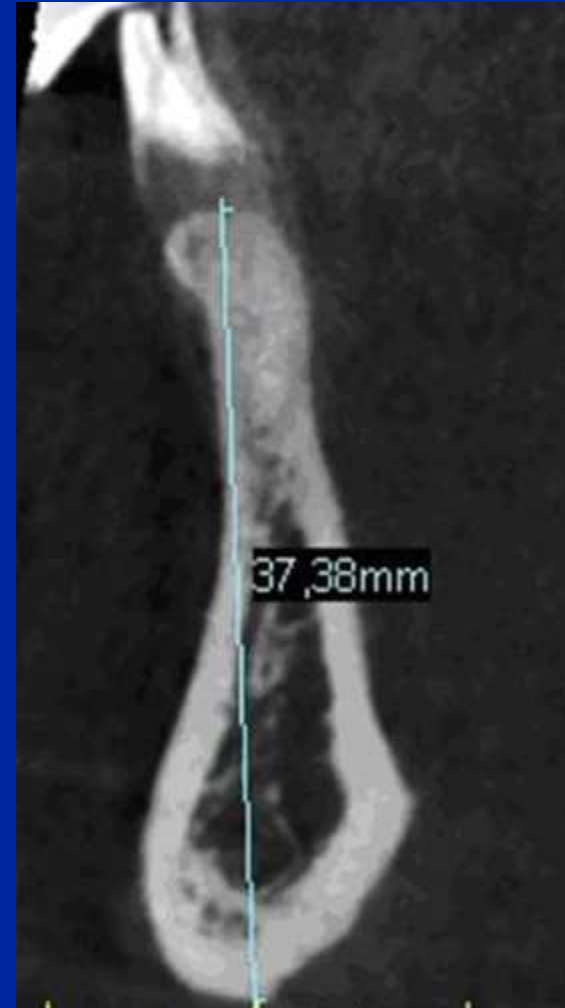
CONE BEAM



TOMOGRAPHIE A FAISCEAU CONIQUE RESOLUTION SPATIALE SUPERIEURE



SCANNER



NEWTOM VG

IMPLANTOLOGIE ORALE

BUTS de l'imagerie 3D

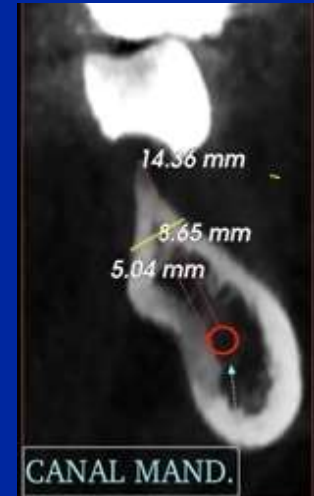
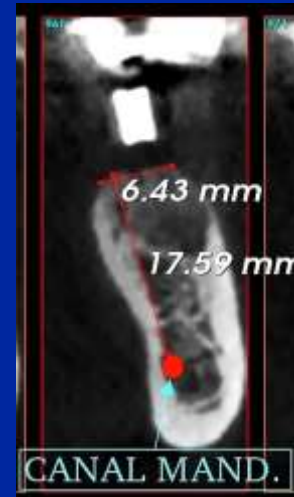
– VOLUME OSSEUX

.épaisseur au niveau de la crête

.hauteur jusqu'au premier obstacle

.en cas de crête effilée:

hauteur résiduelle pour 5 mm d'épaisseur

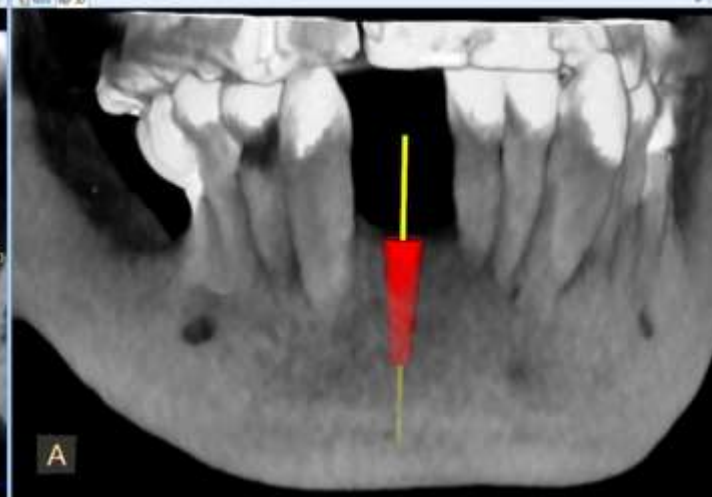
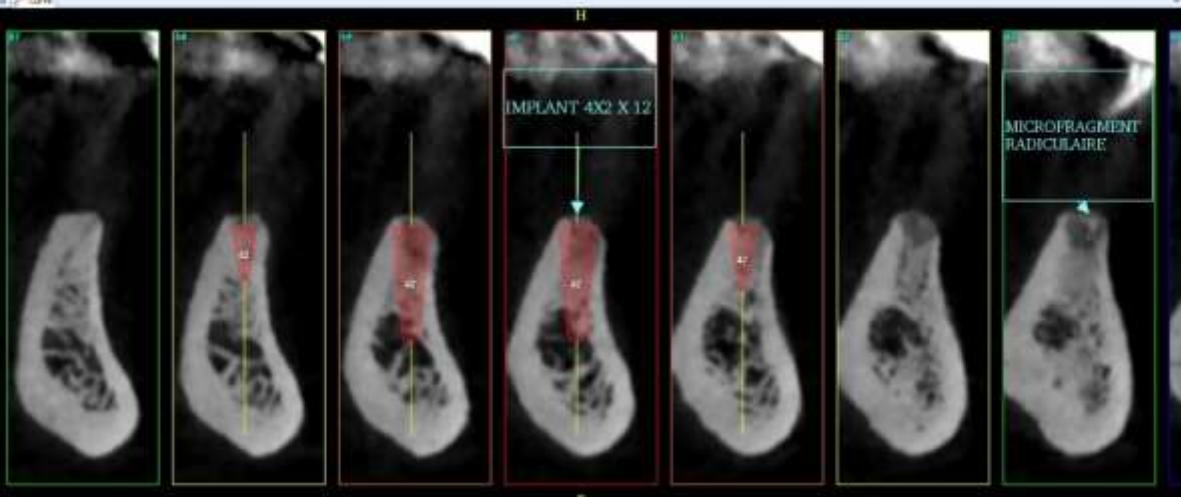
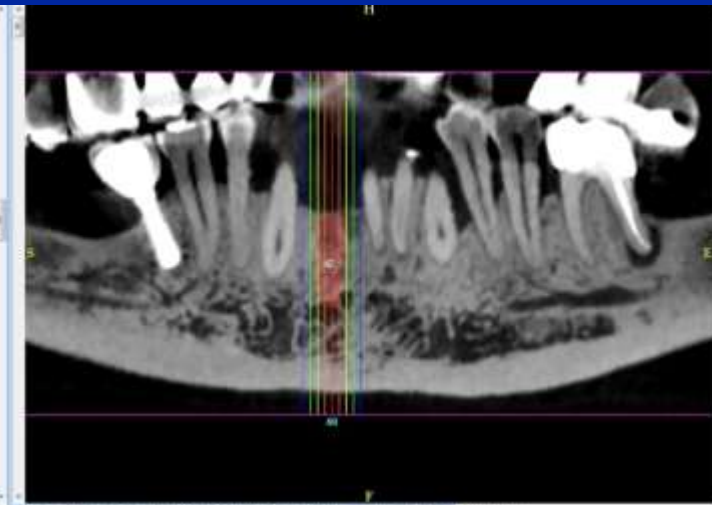
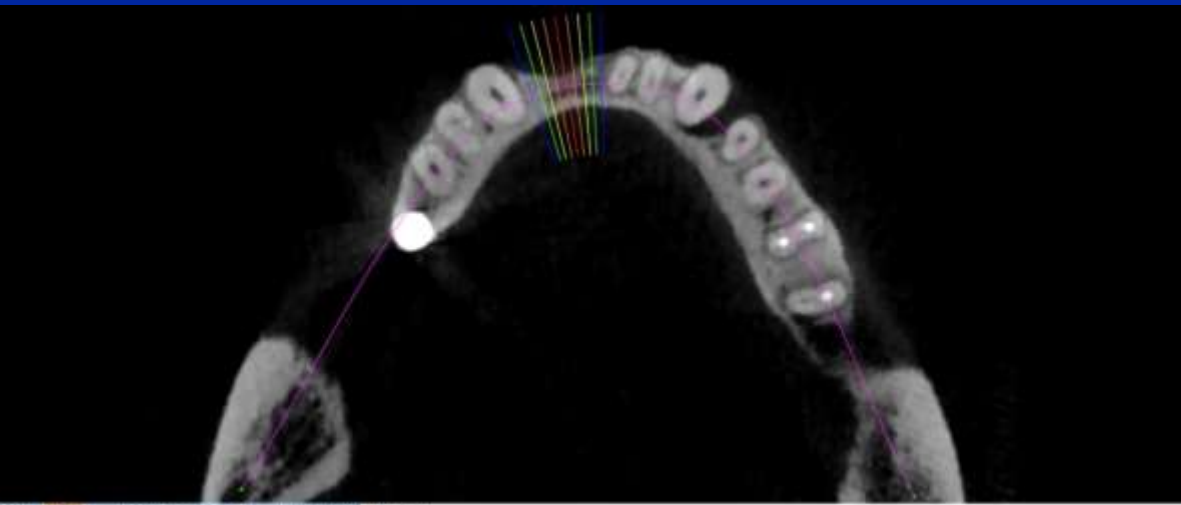


– QUALITE DE L'OS

.os spongieux (logiciel de simulation+++)

.corticales (en mm)

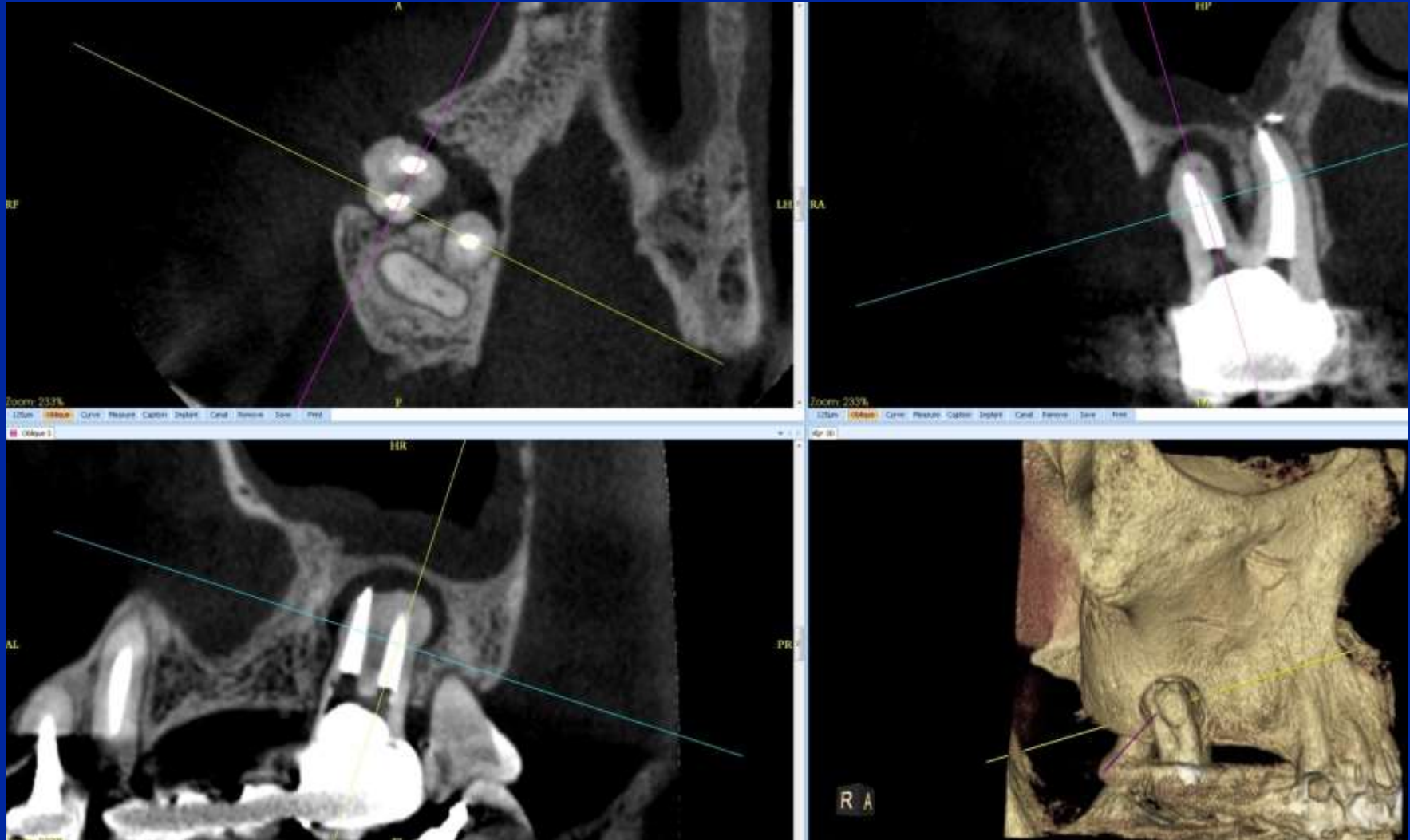
IMPLANTOLOGIE ORALE



DICOM Insight® Mode Dentascanner
Logiciel d'Imagerie médicale

www.conebeamparis.com

PATHOLOGIE



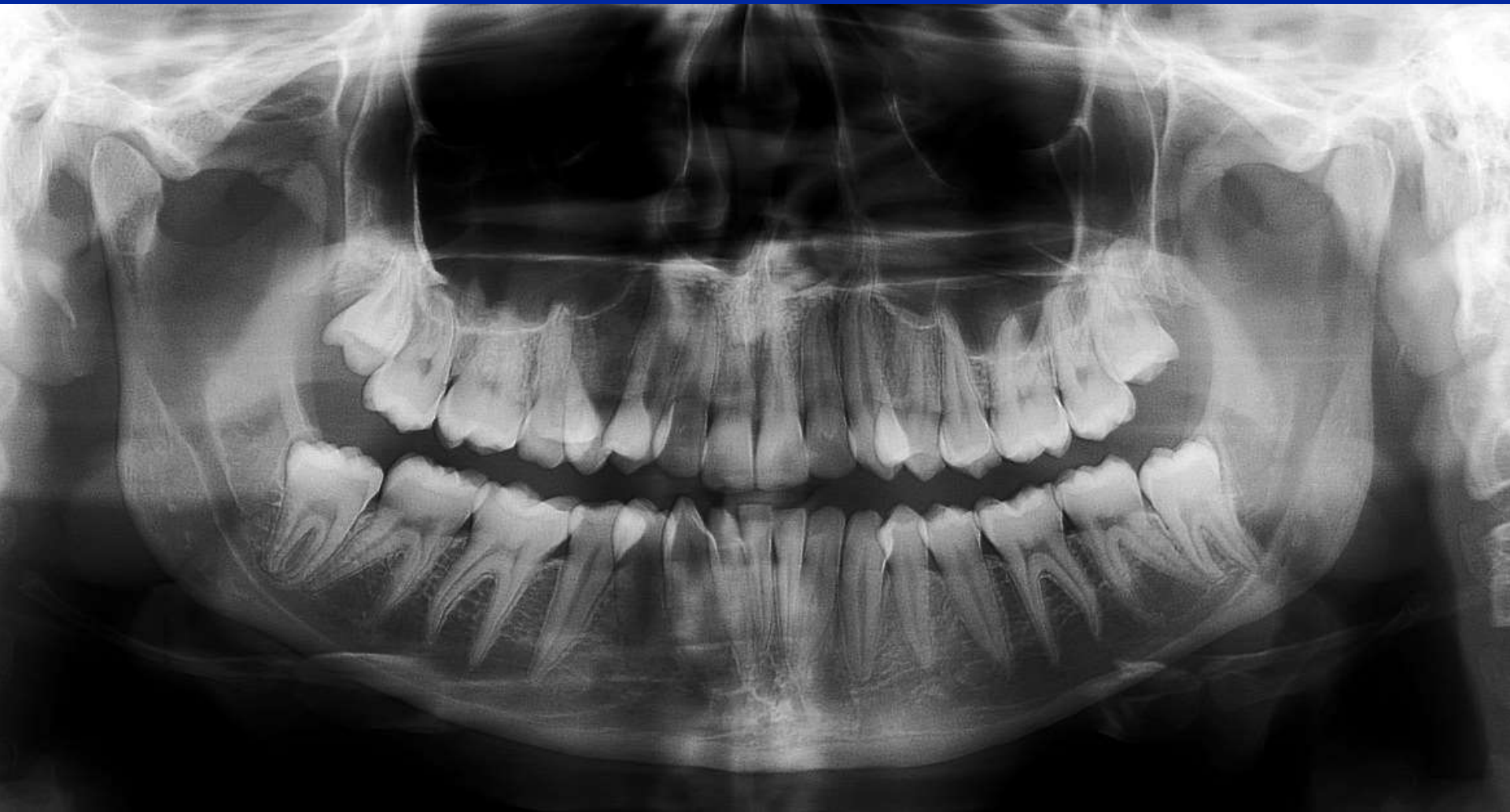DICOM Insight® Mode Multiplanaire (MPR)

Logiciel d'Imagerie médicale

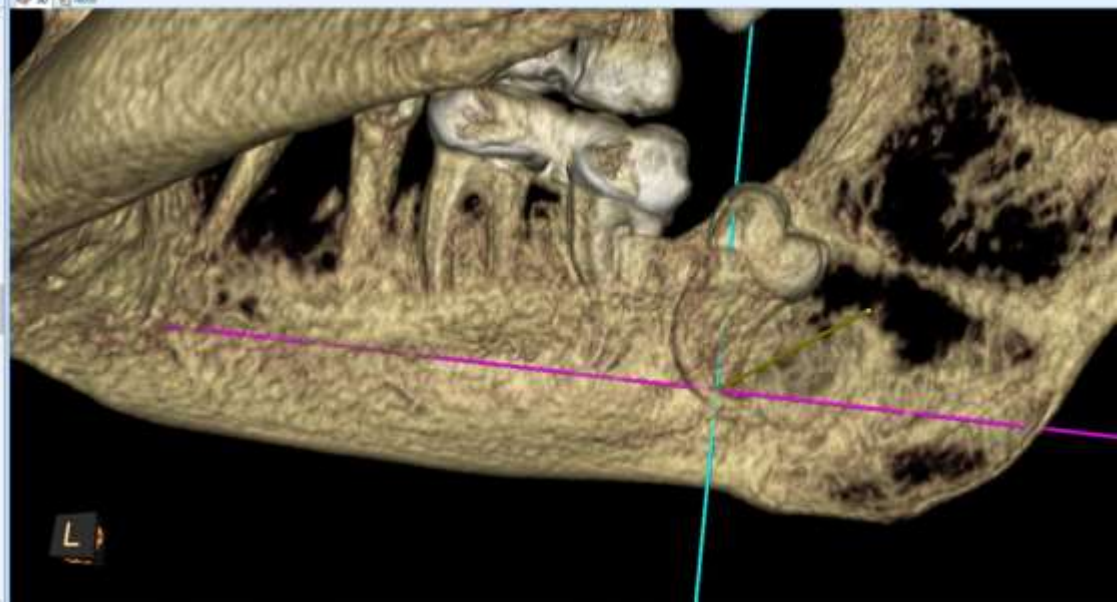
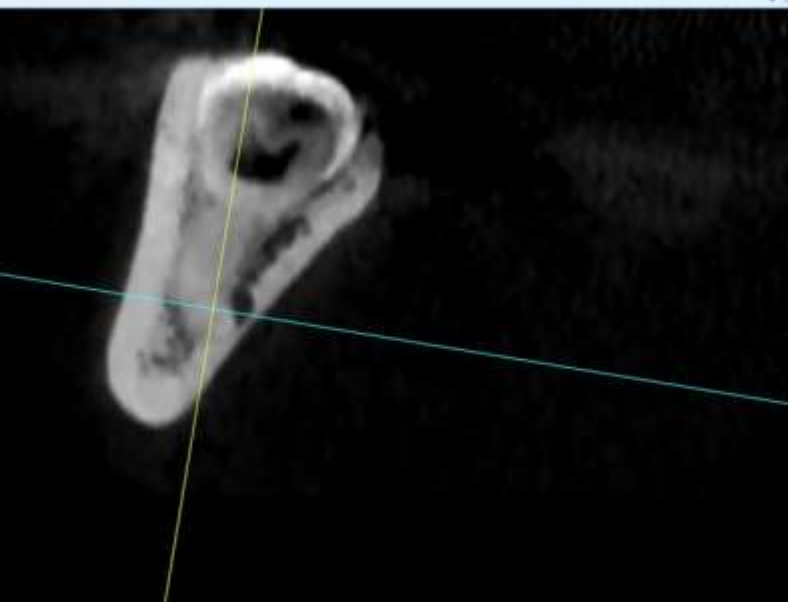
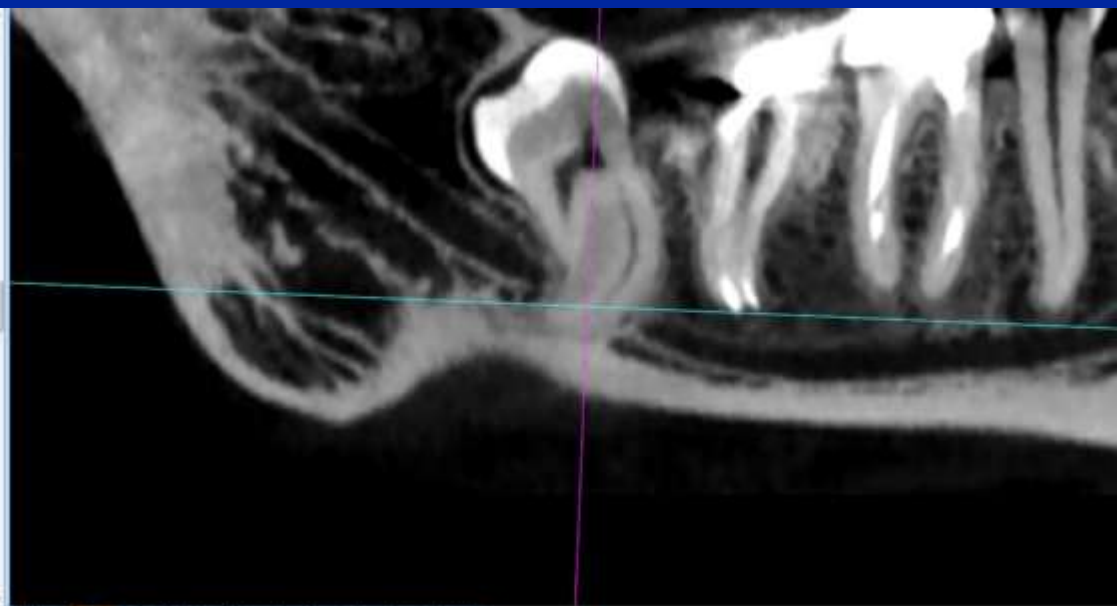
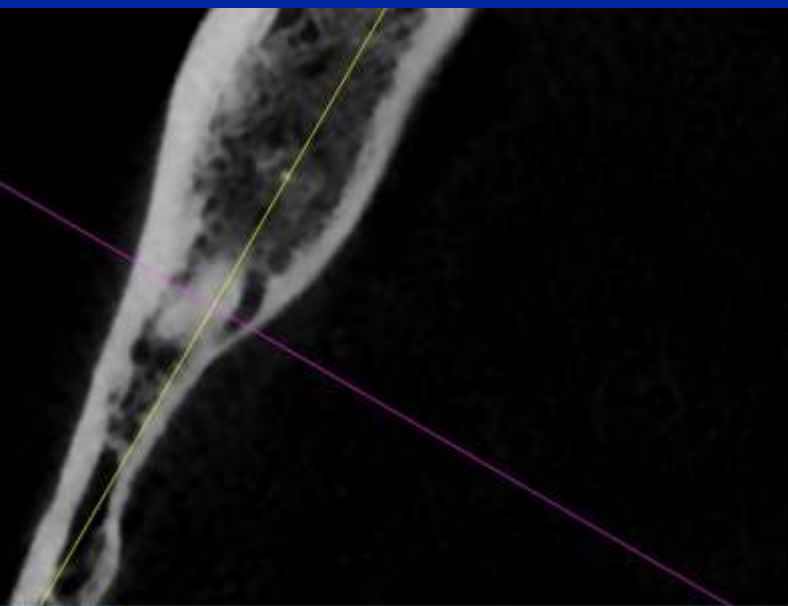
www.conebeamparis.com

CONE BEAM ET TROISIEMES MOLAIRES INCLUSES

PANORAMIQUE



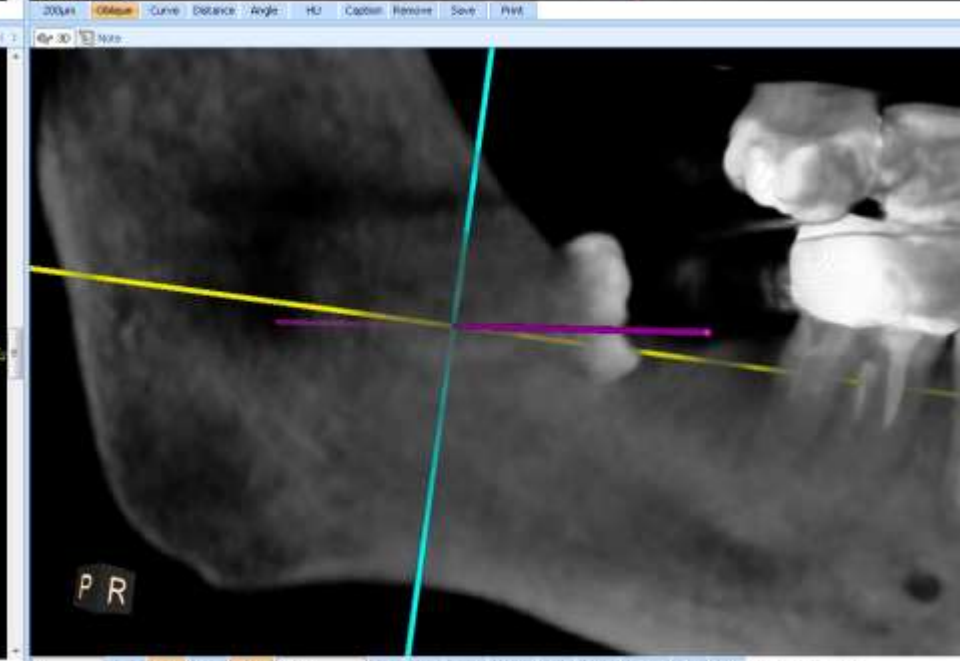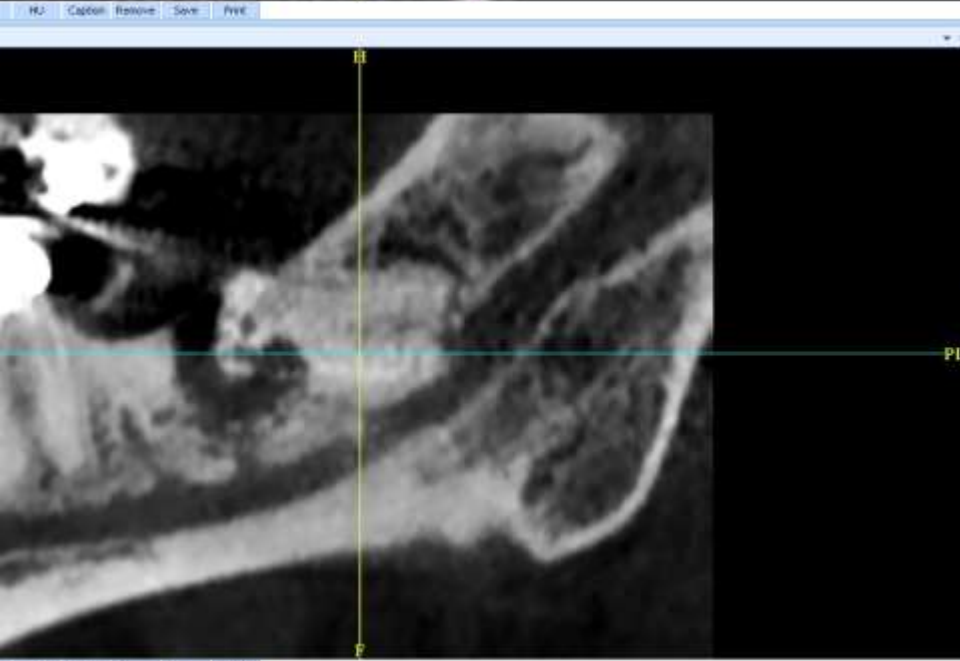
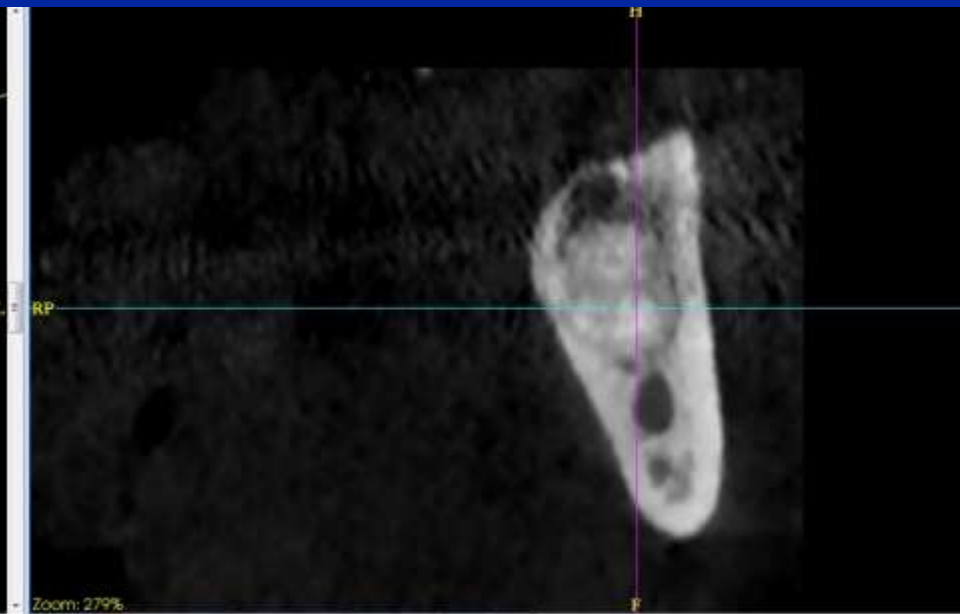
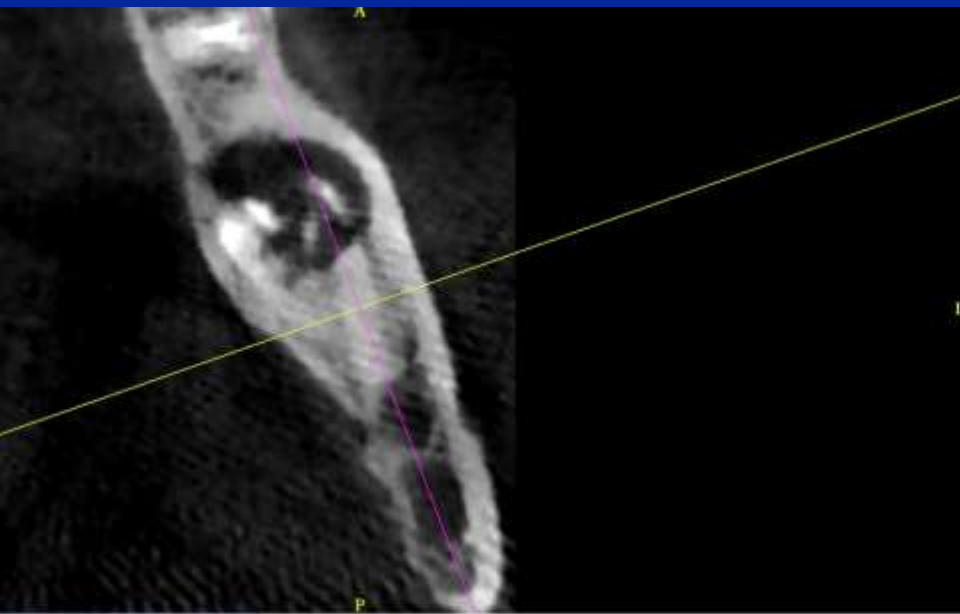
CONE BEAM ET TROISIEMES MOLAIRES INCLUSES



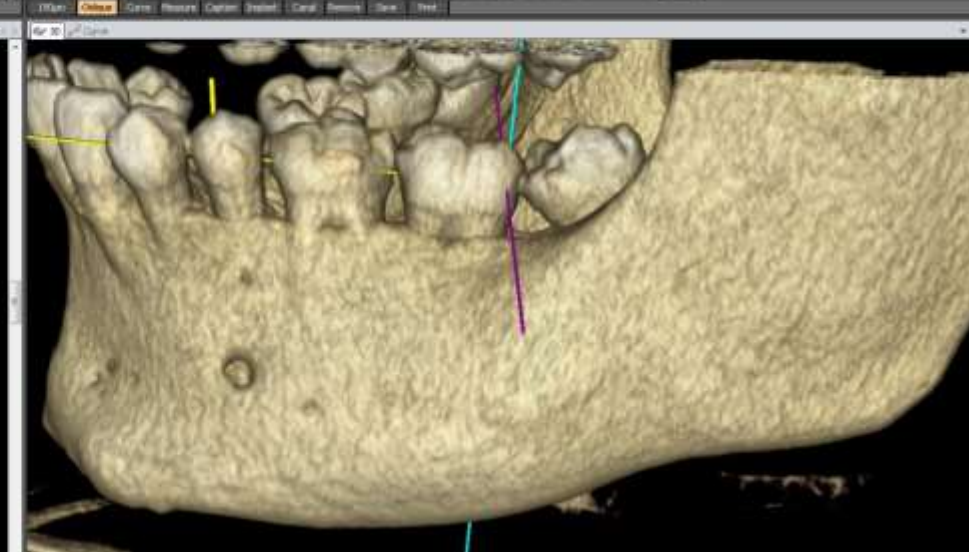
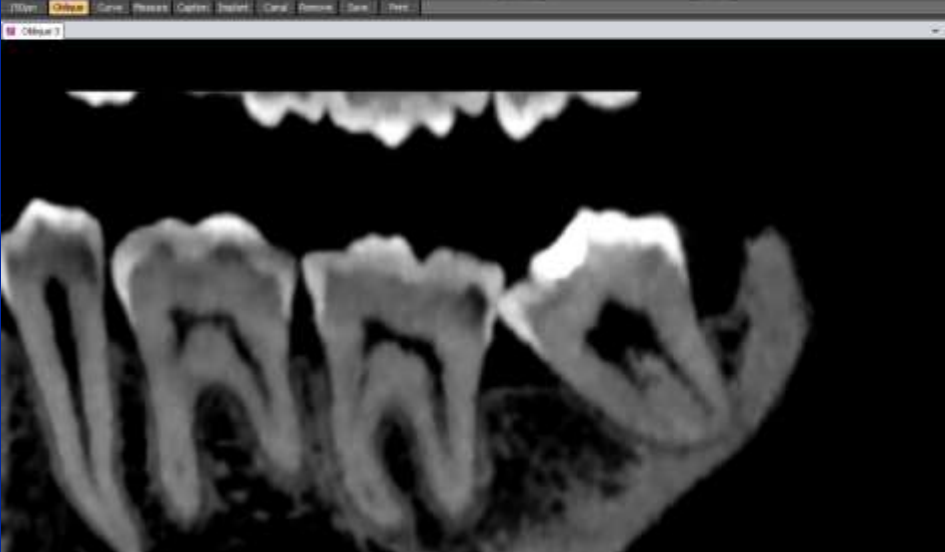
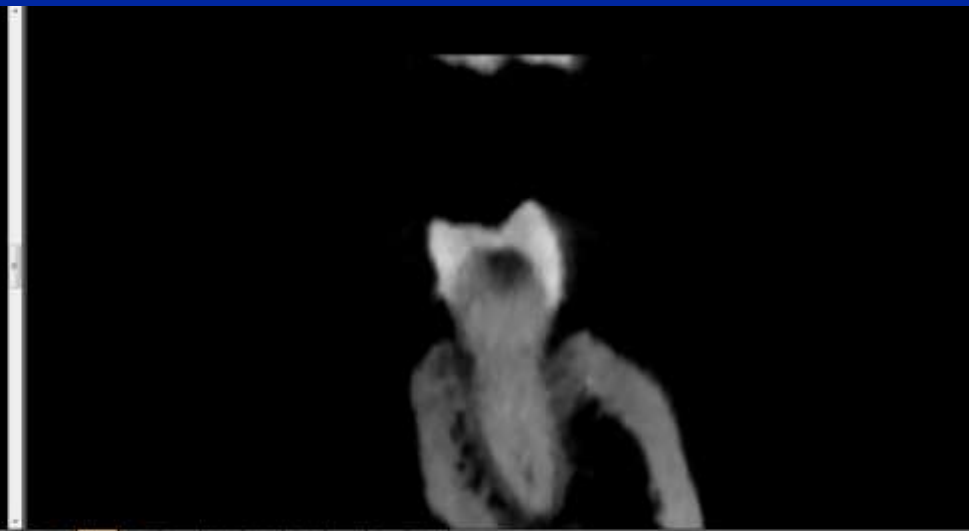
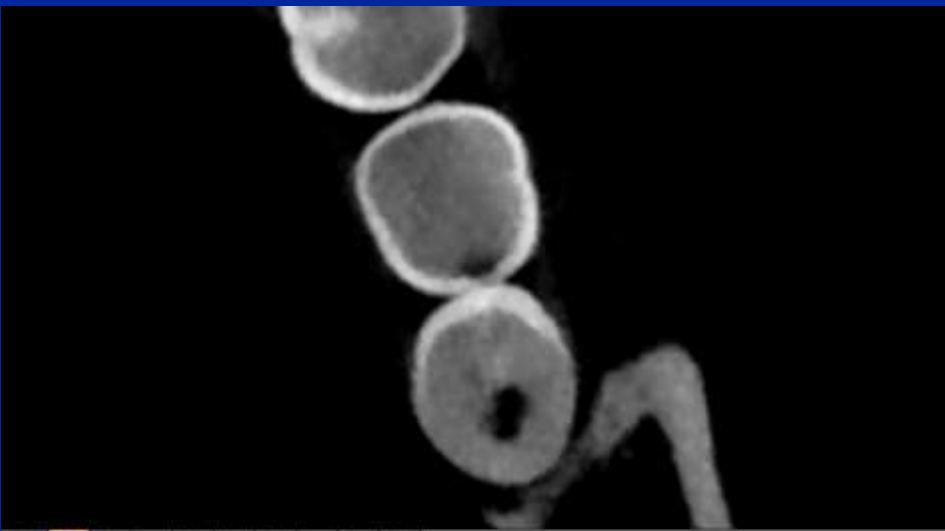
48 INCLUSE COURBE, CROCHET COMPLET

www.conebeamparis.com

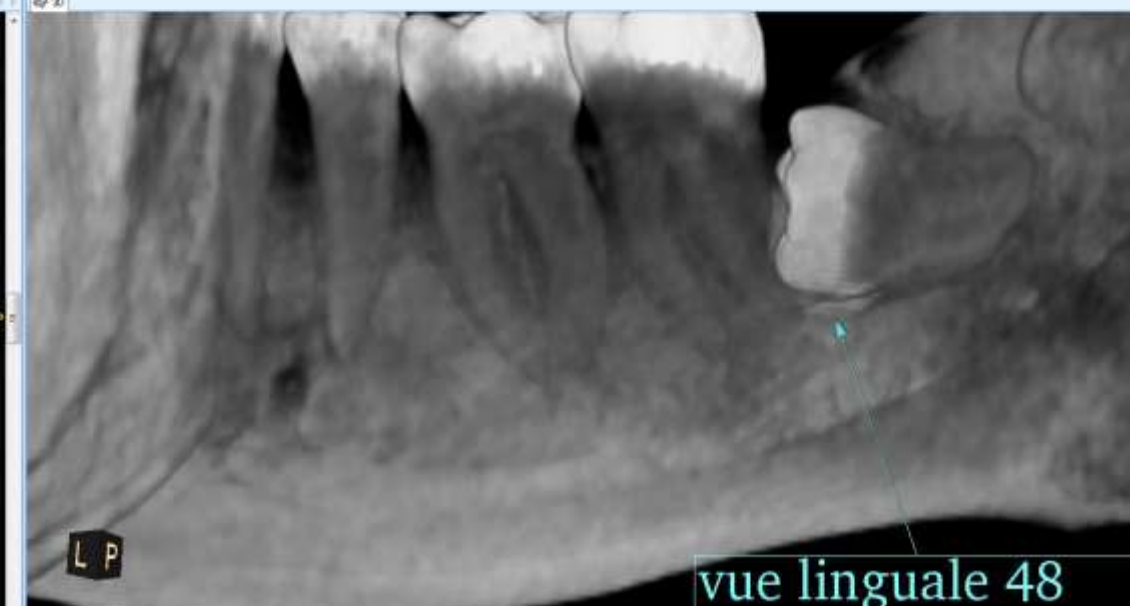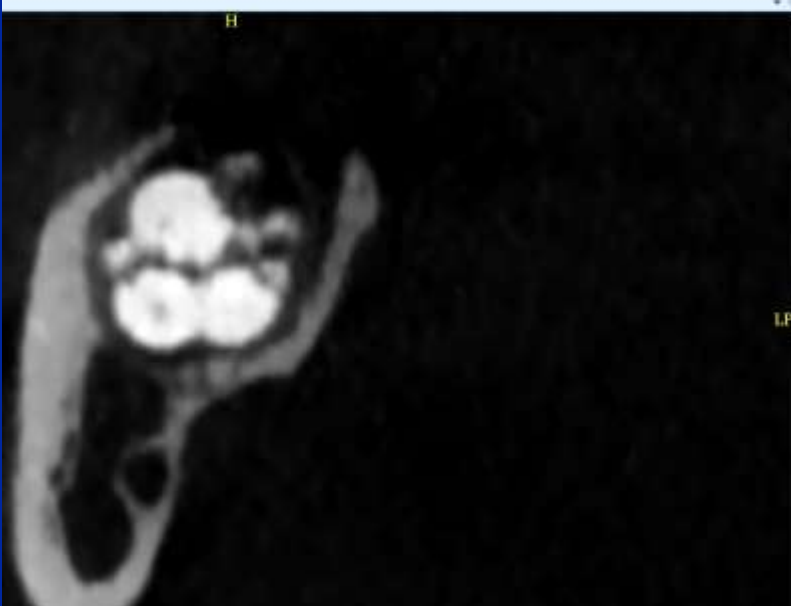
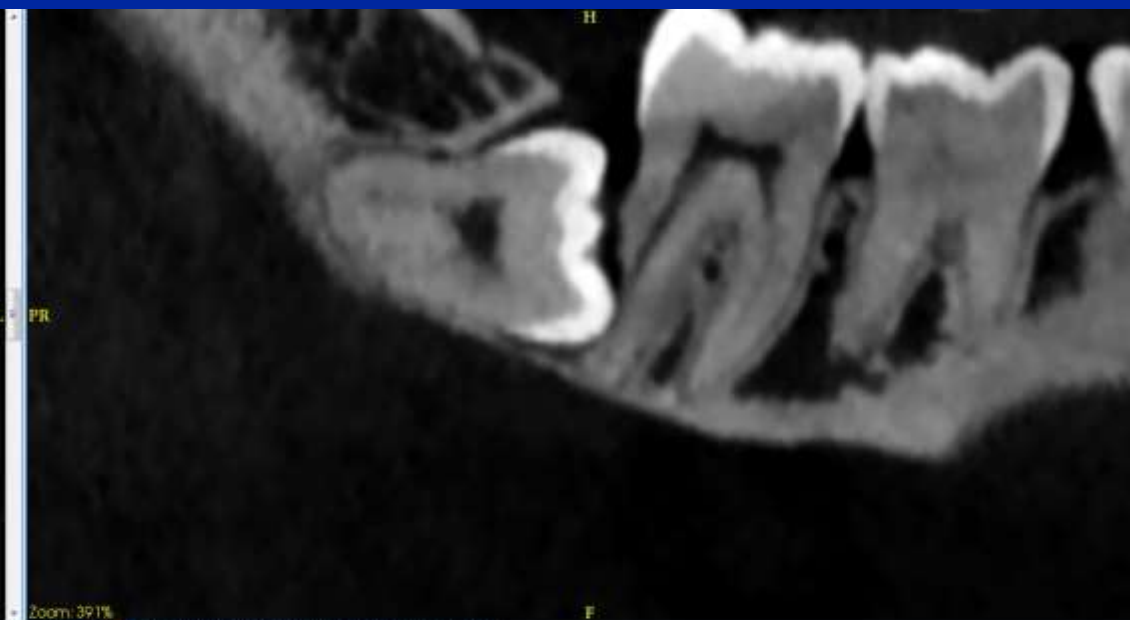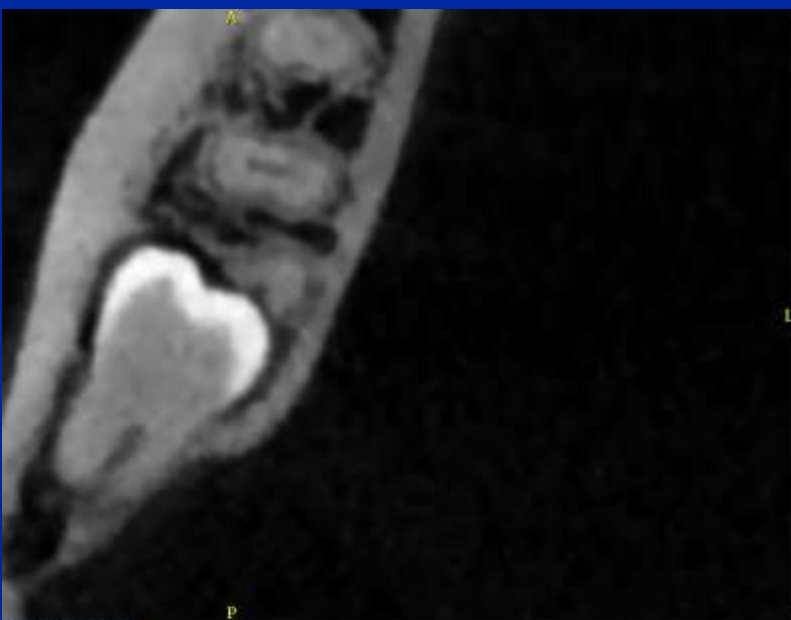
CONE BEAM ET TROISIEMES MOLAIRES INCLUSES



CONE BEAM ET TROISIEMES MOLAIRES INCLUSES

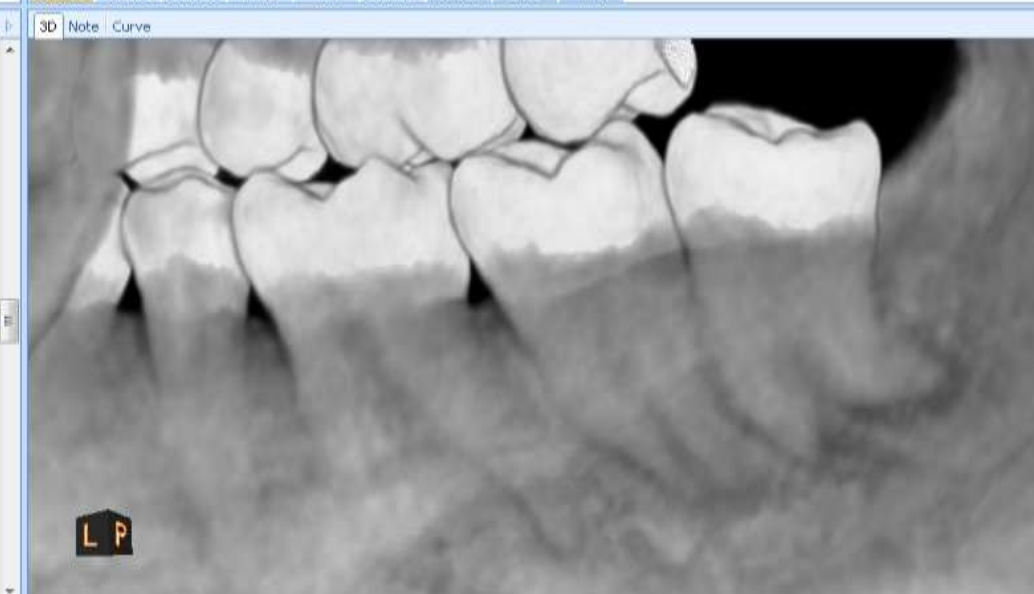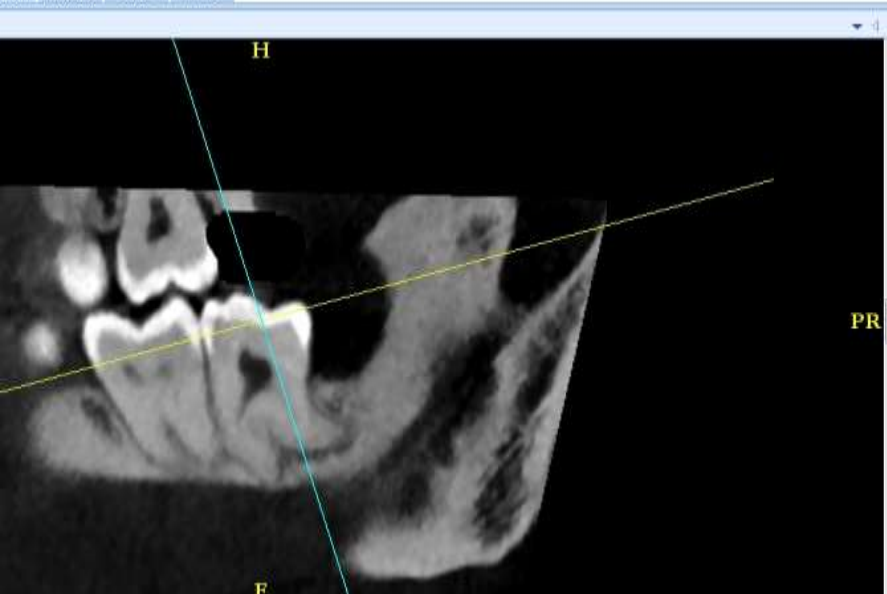
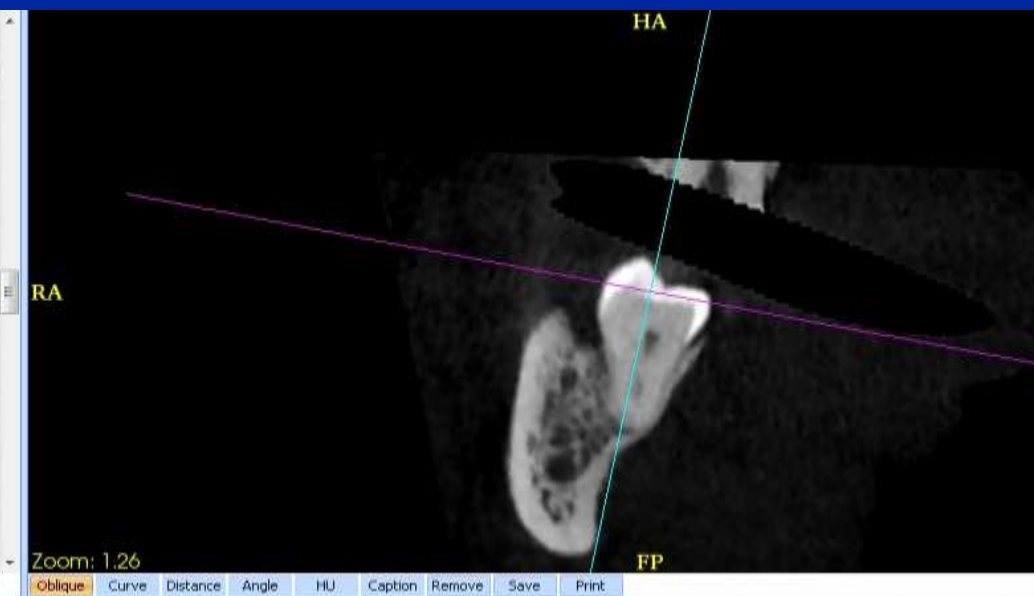

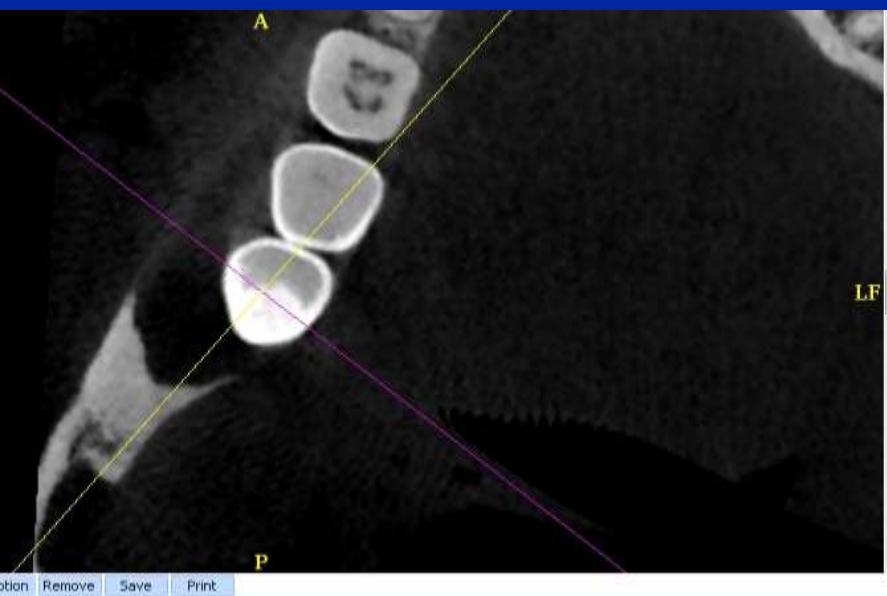
CONE BEAM ET TROISIEMES MOLAIRES INCLUSES



vue linguale 48

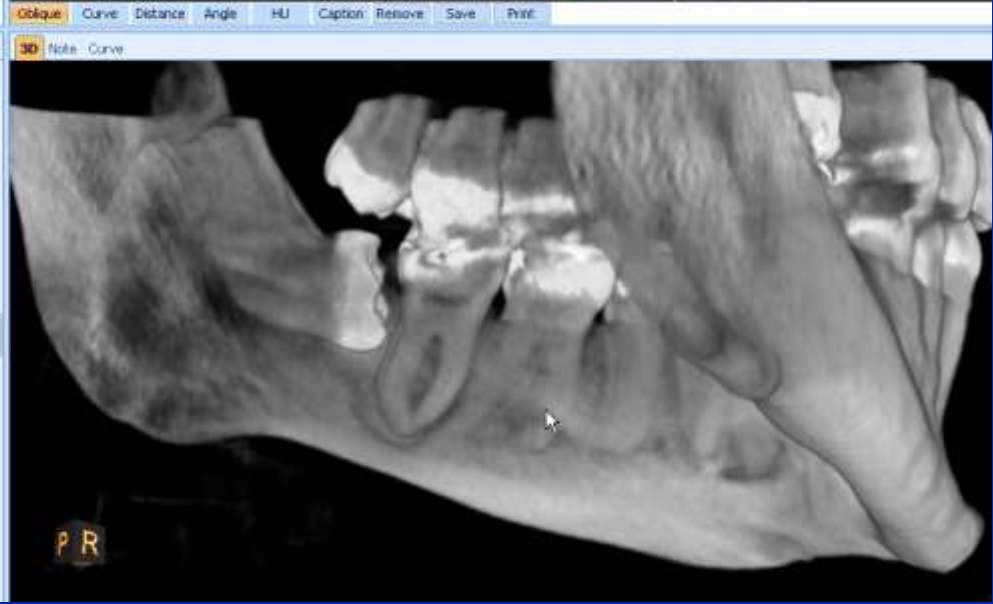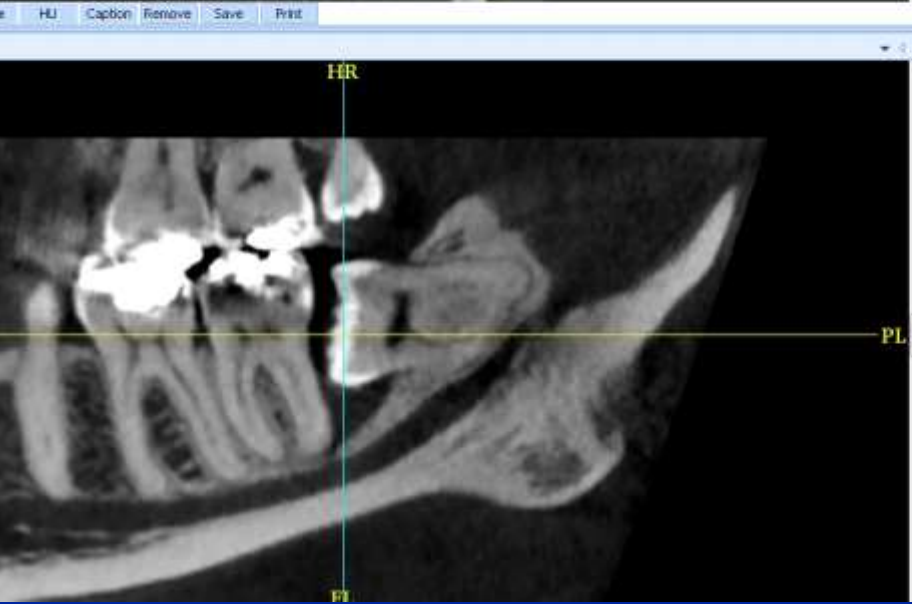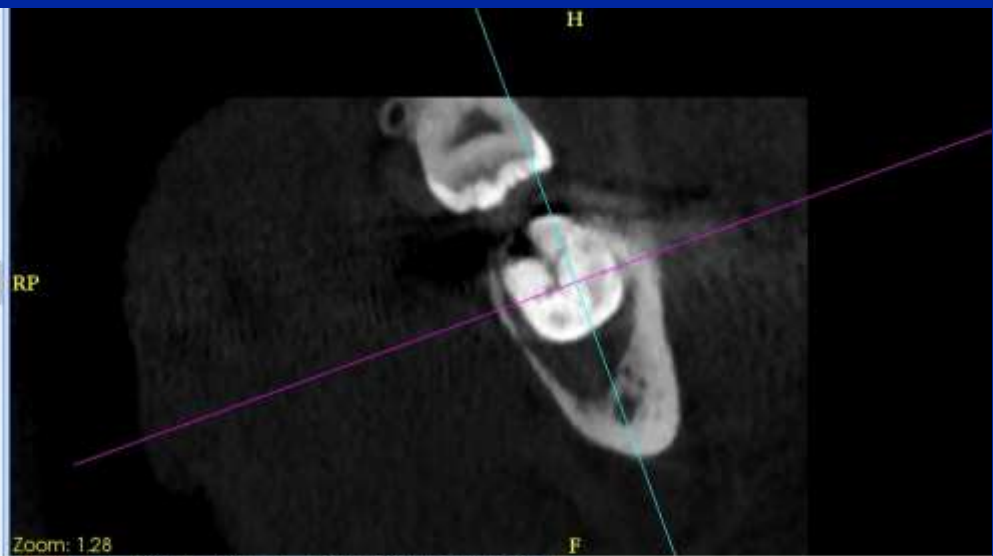
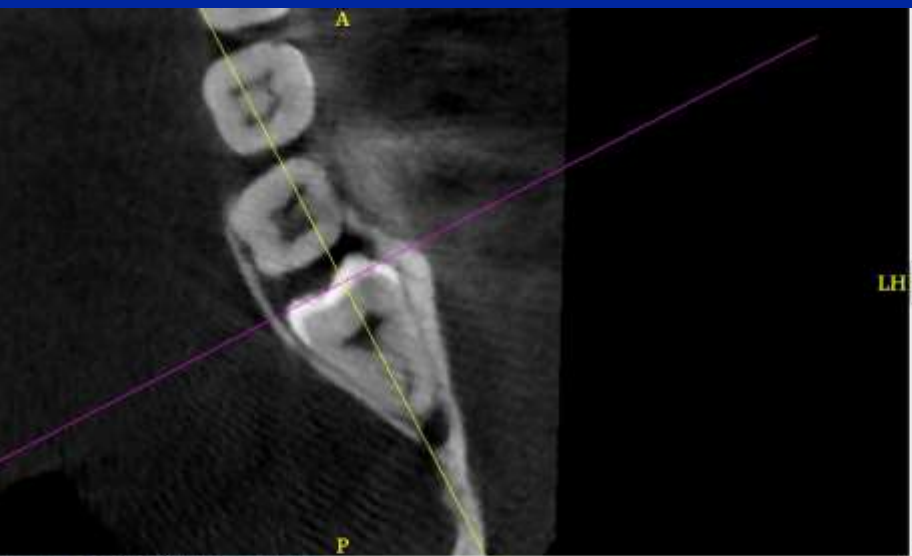
CONE BEAM ET TROISIEMES MOLAIRES INCLUSES



**38 INCLUSE RACINE COURBE
ET KYSTE MARGINAL POSTERIEUR**

www.conebeamparis.com

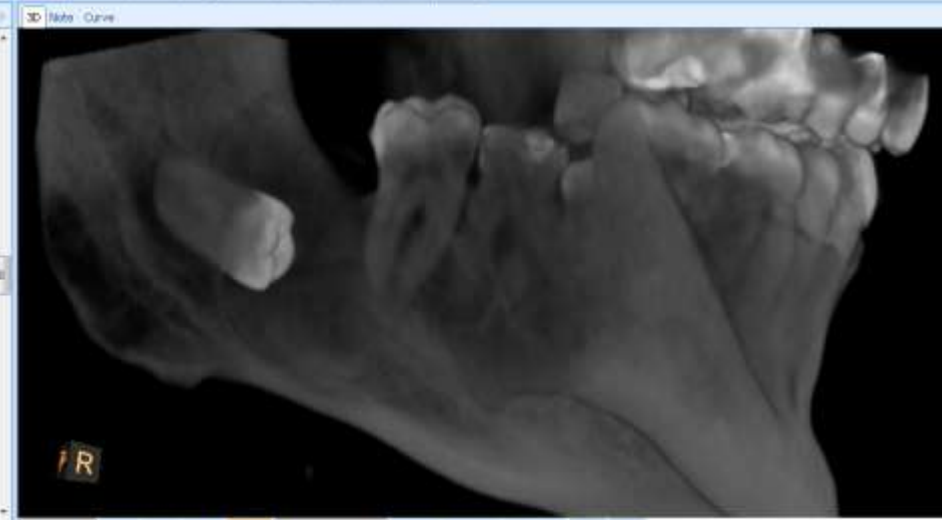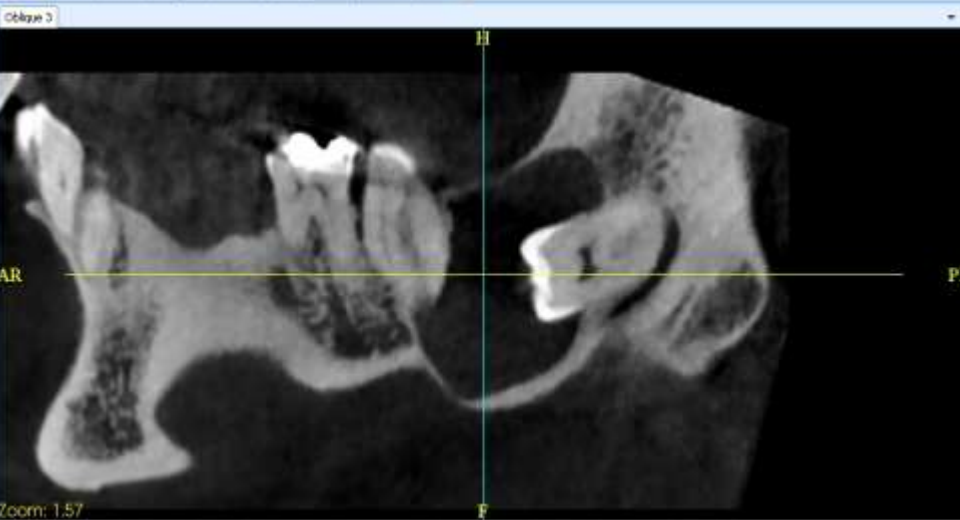
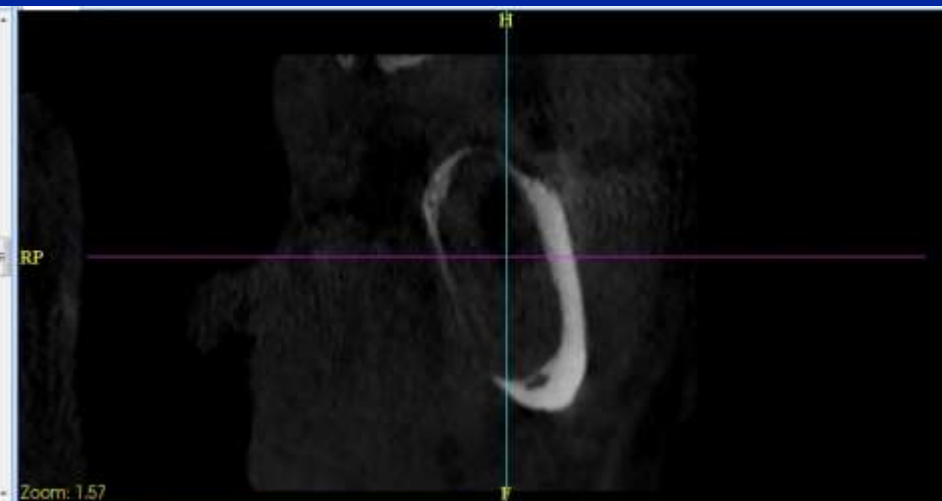
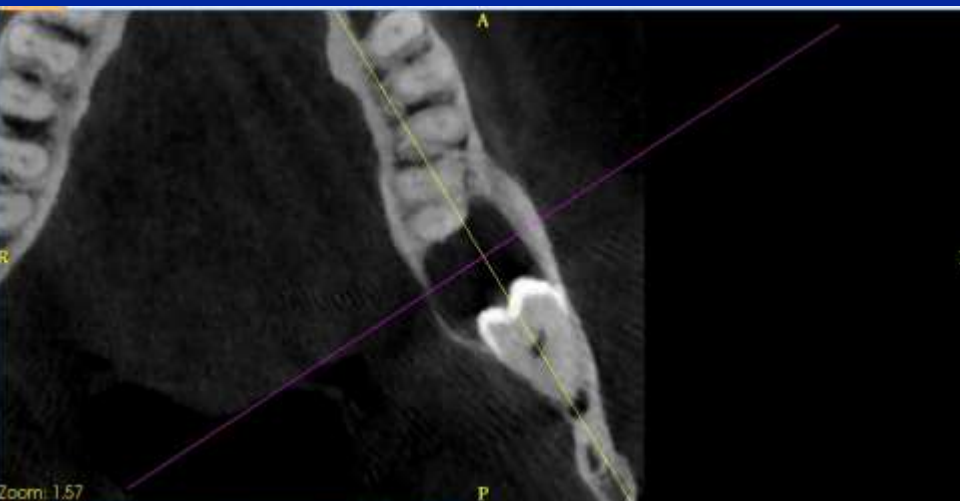CONE BEAM ET TROISIEMES MOLAIRES INCLUSES



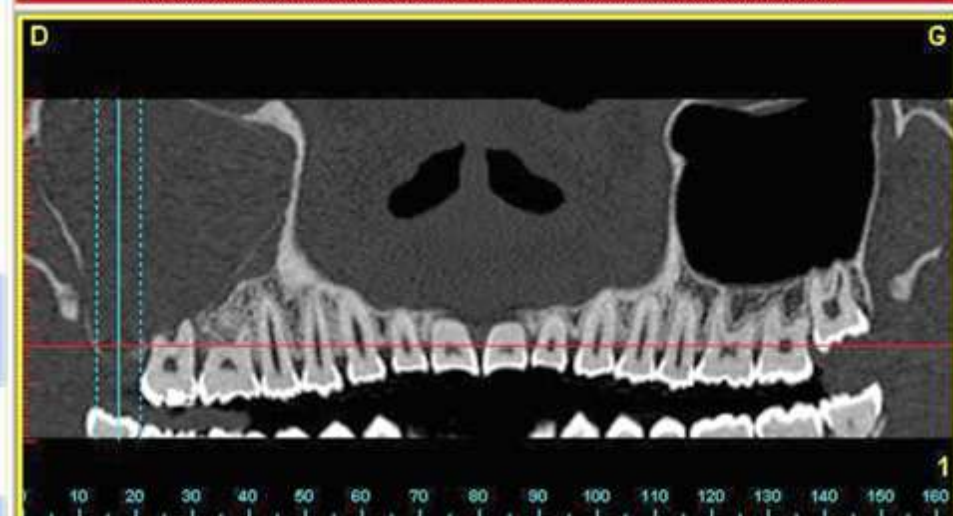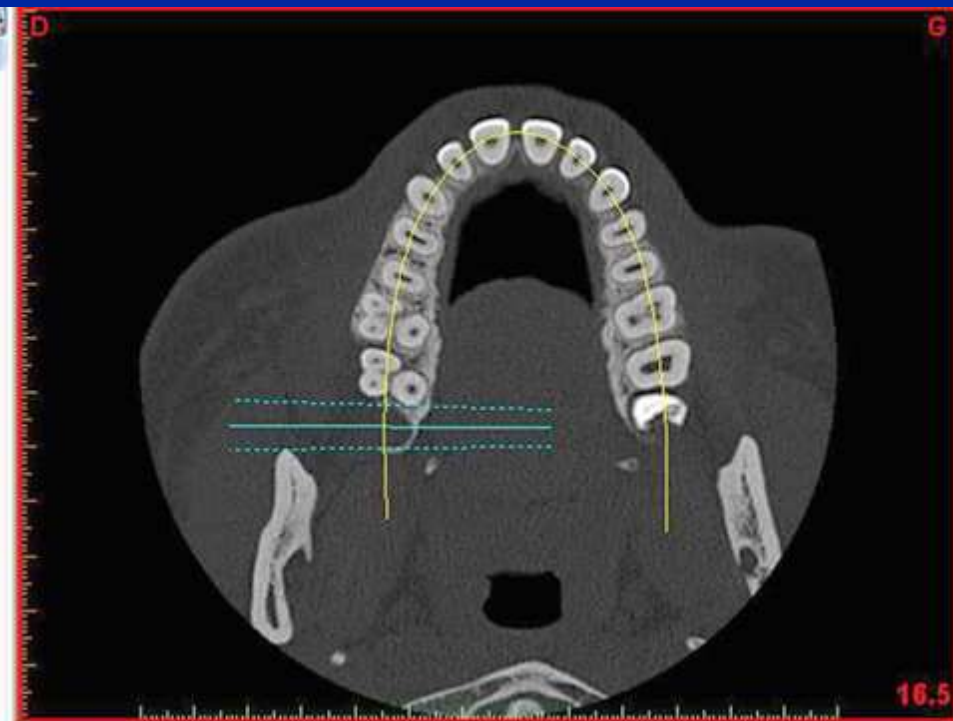
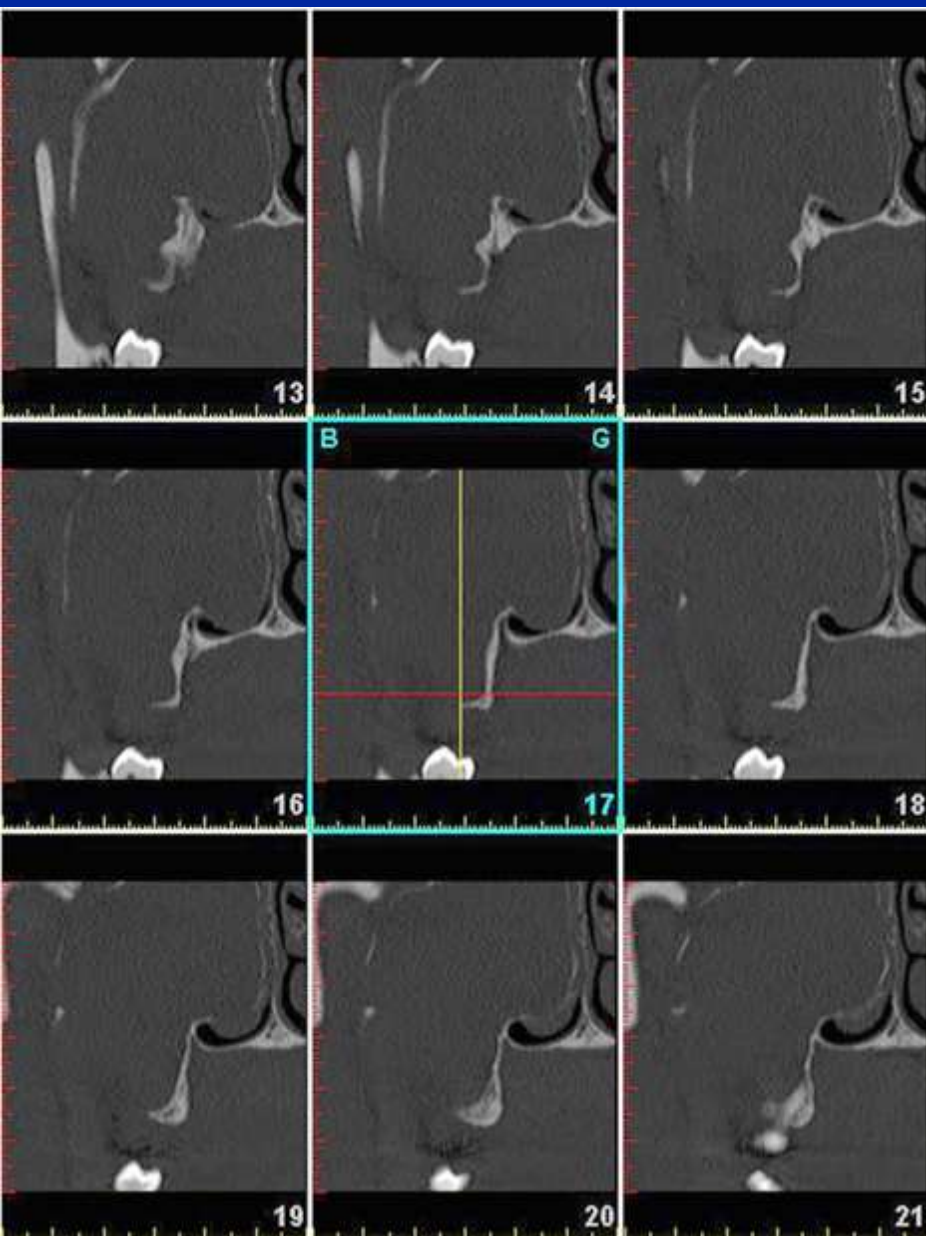
**38 INCLUSE
ET KYSTE MARGINAL ANTERIEUR**

www.conebeamparis.com

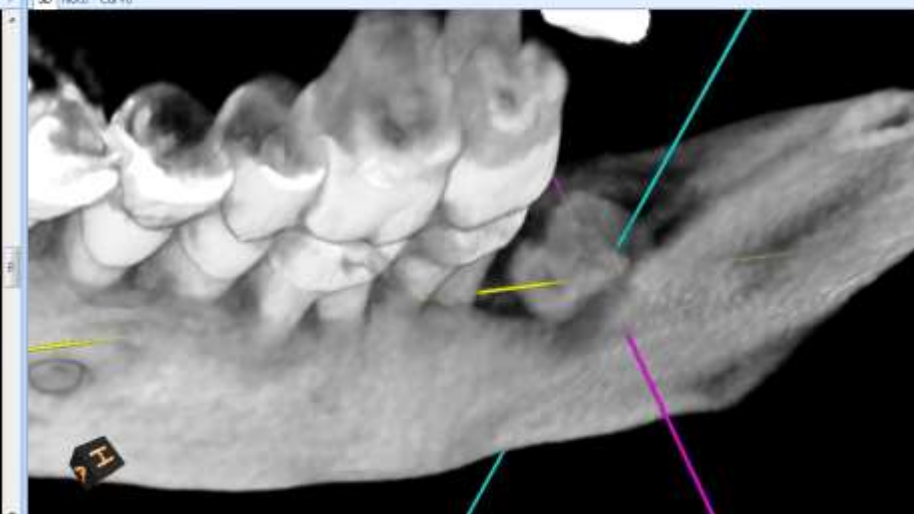
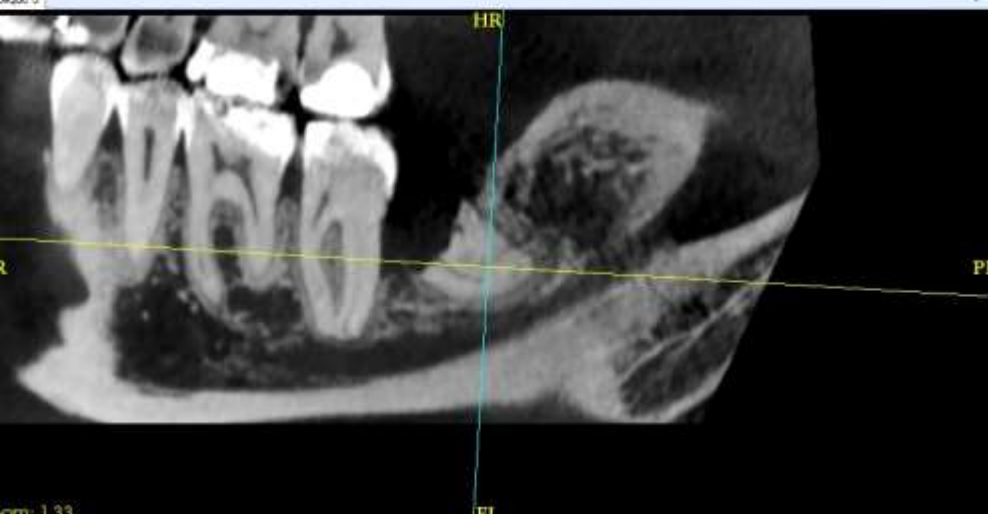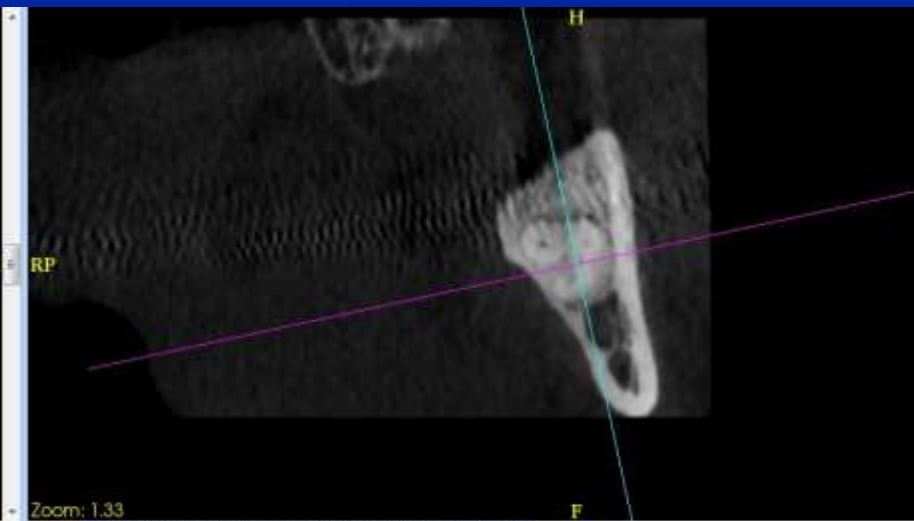
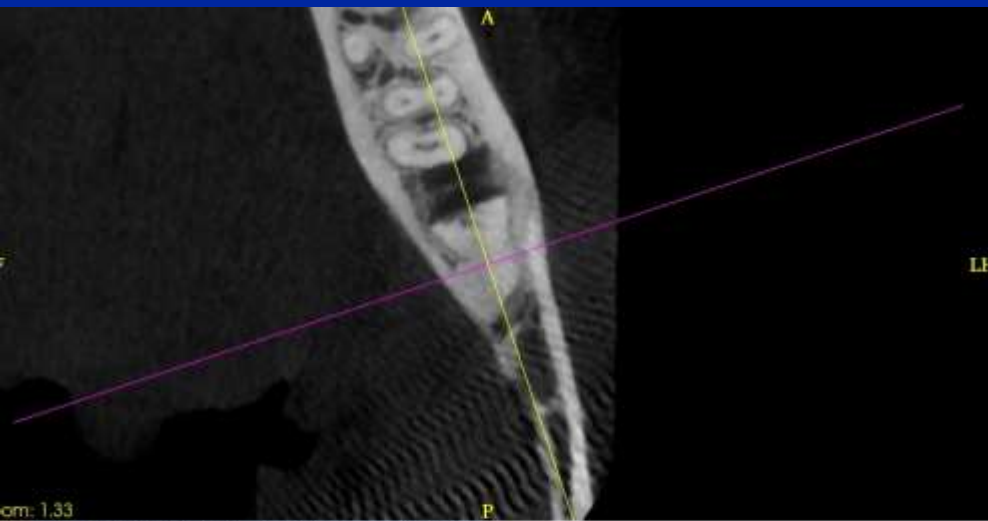
CONE BEAM ET TROISIEMES MOLAIRES INCLUSES



CONE BEAM ET TROISIEMES MOLAIRES INCLUSES



CONE BEAM ET TROISIEMES MOLAIRES INCLUSES



CONE BEAM ET ODF

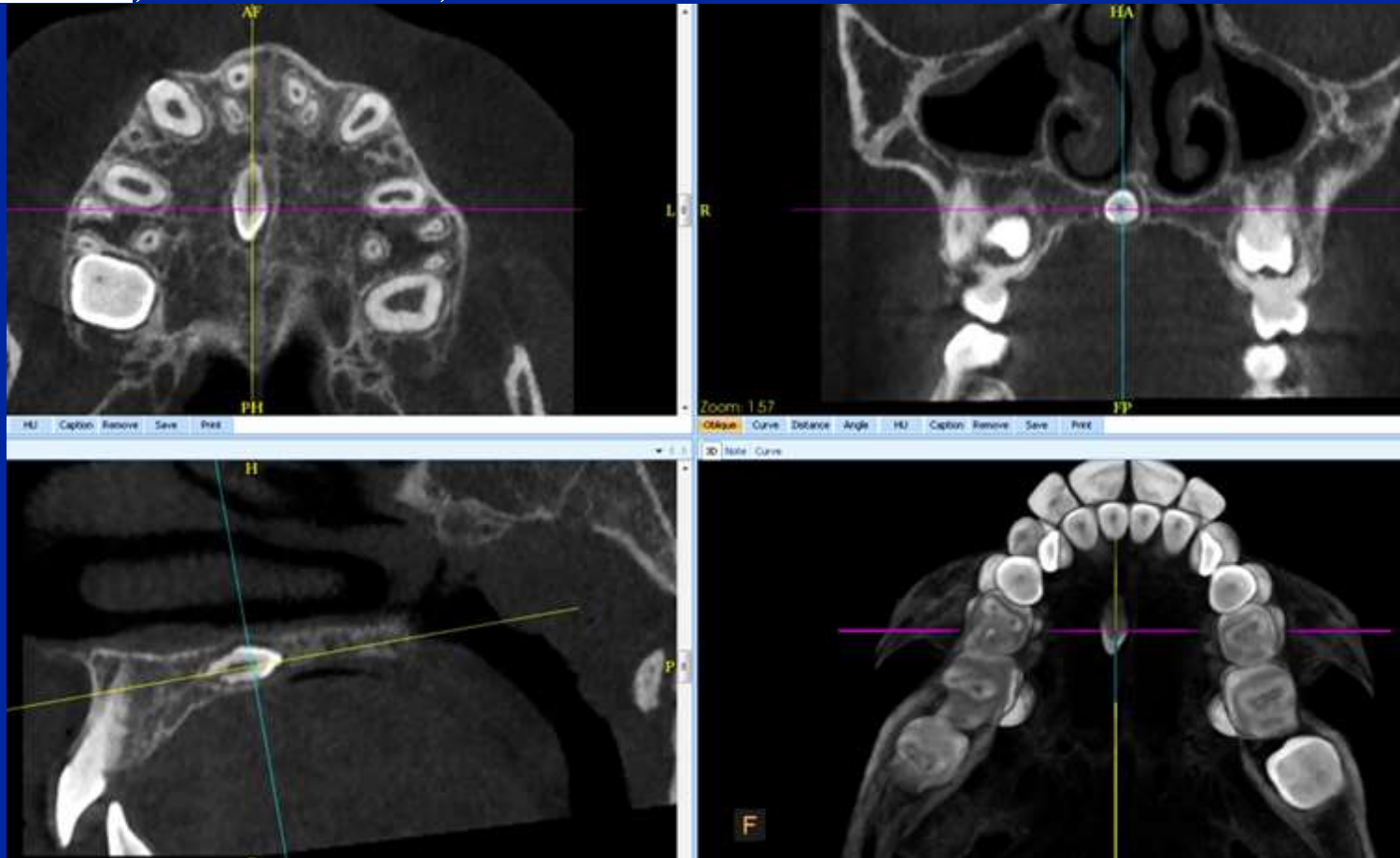
Anomalies dentaires :

Les éléments dentaires surnuméraires: risque d'obstacle à l'évolution des dents.

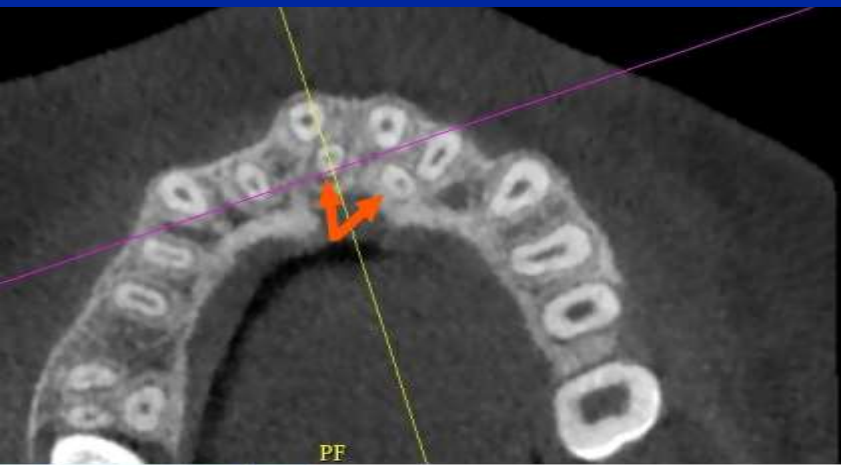1. Odontoïde (forme générale d'une dent normale) *mésiodens*+++

-souvent unique, paramédian maxillaire, petit, caniniforme et inclus, couronne en haut ;

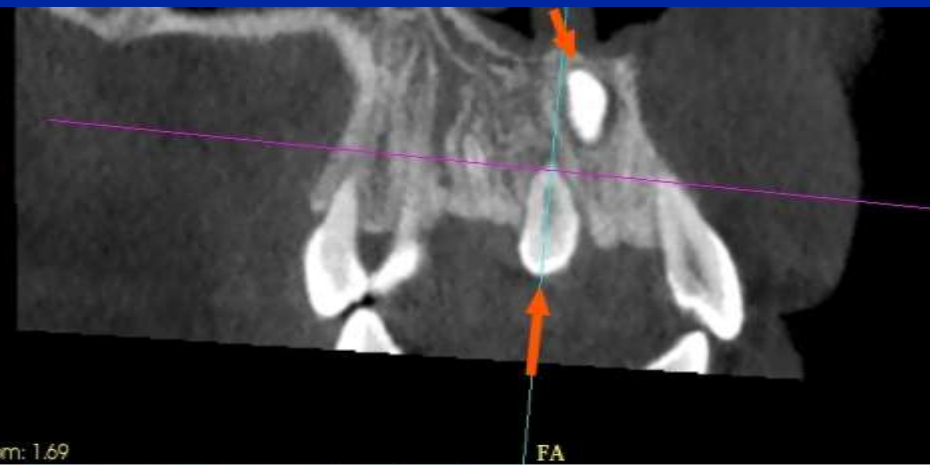
-parfois double, «tête-bêche» ;



CONE BEAM ET ODF

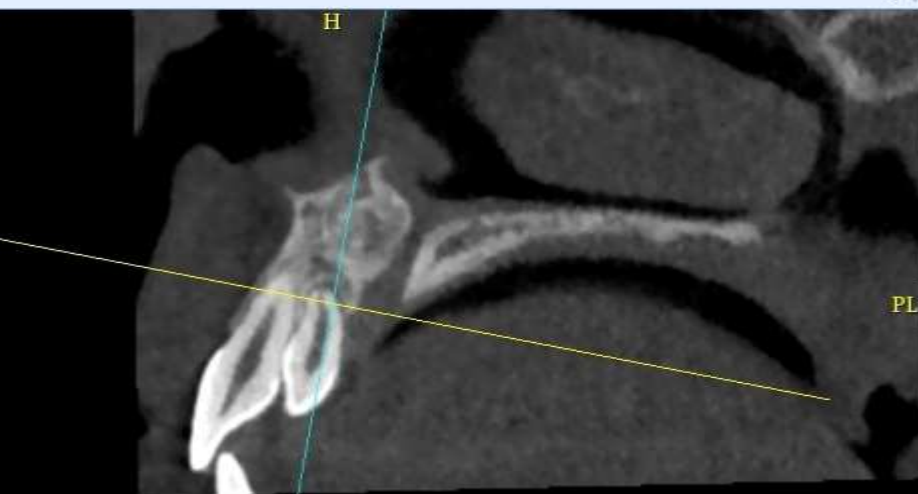

L RP

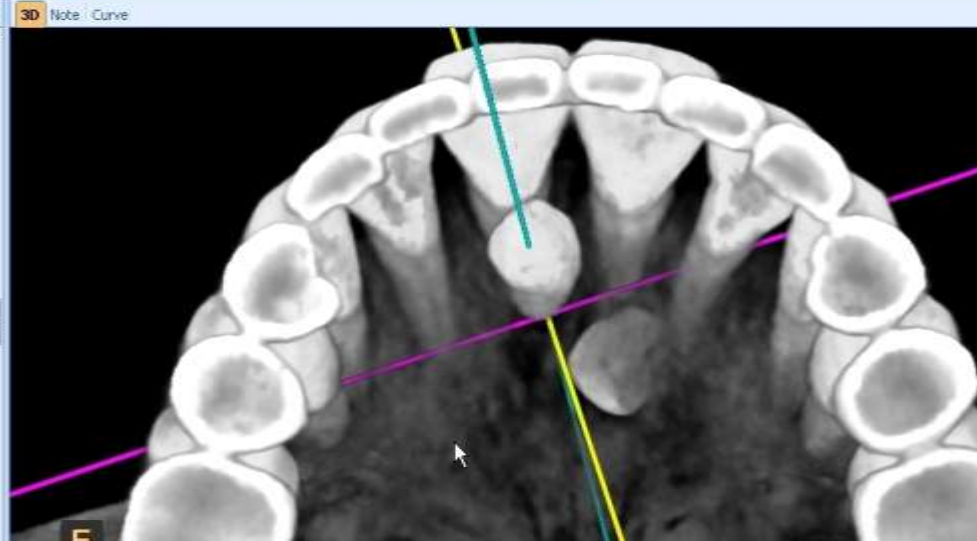


Zoom: 1.69

Oblique Curve Distance Angle HU Caption Remove Save Print



PL



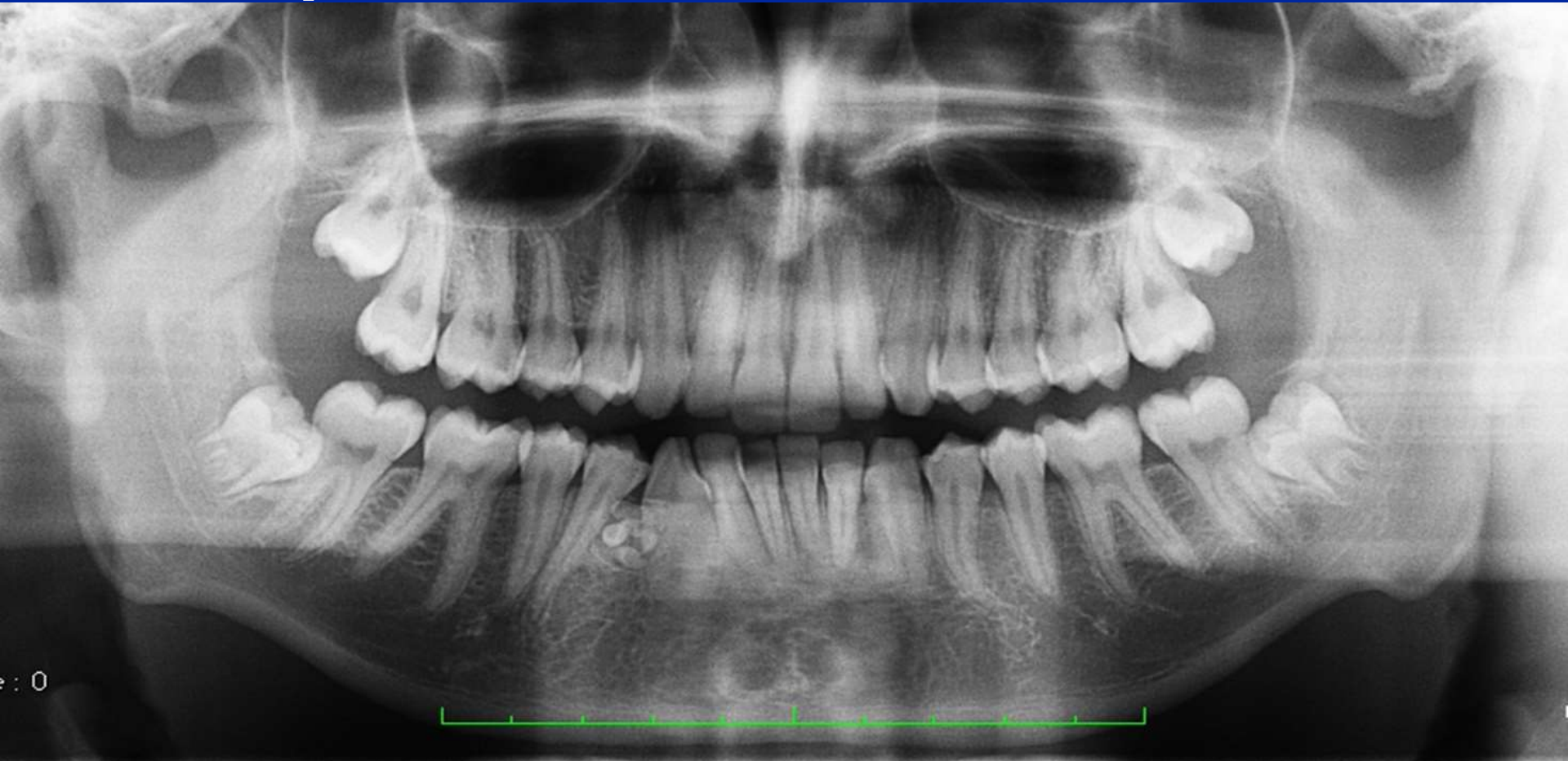CONE BEAM ET ODF

Les éléments dentaires surnuméraires: risque d'obstacle à l'évolution des dents.

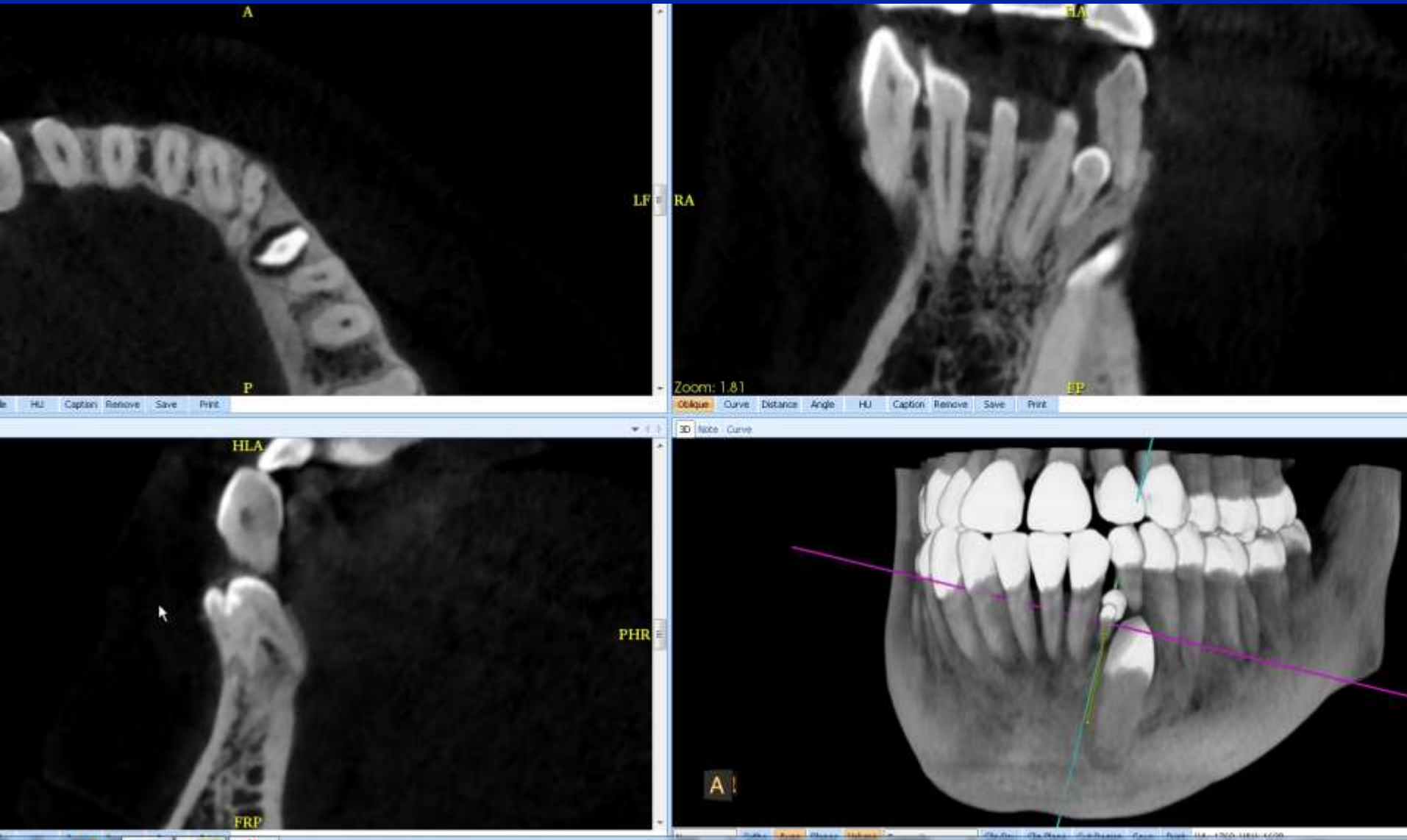
2. Les odontomes: malformations classées parmi les **TB odontogéniques**,

.odontomes complexes : les plus fréquents, constitués de nombreuses petites dents rudimentaires, groupées dans un sac unique, de volume variable ;

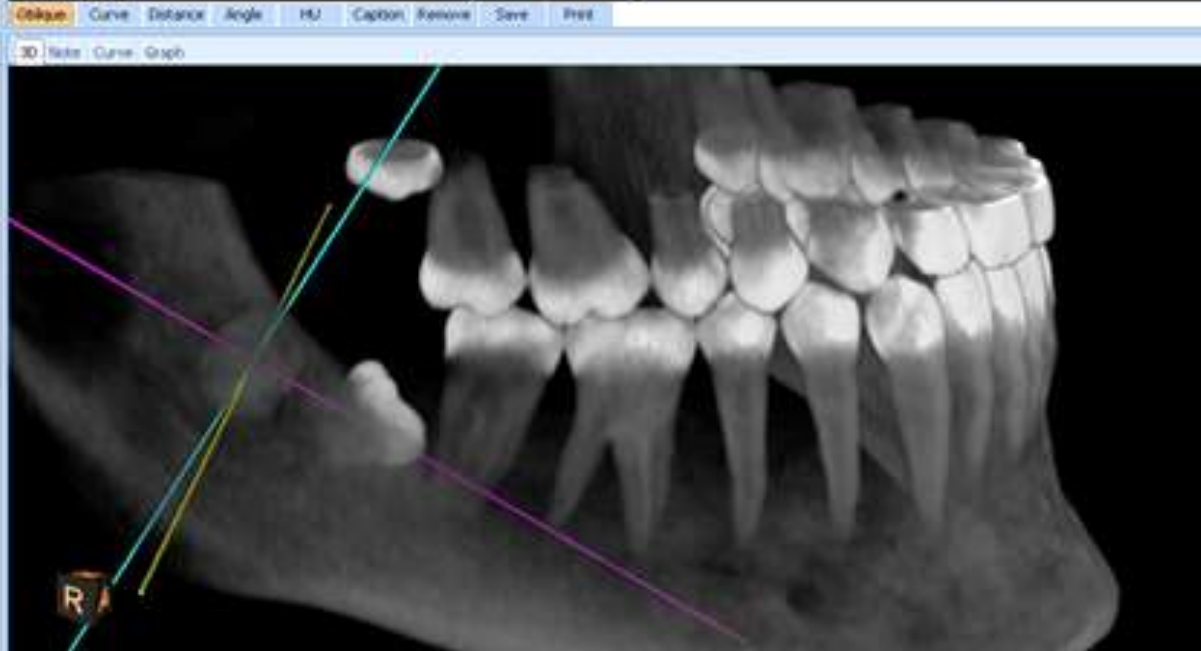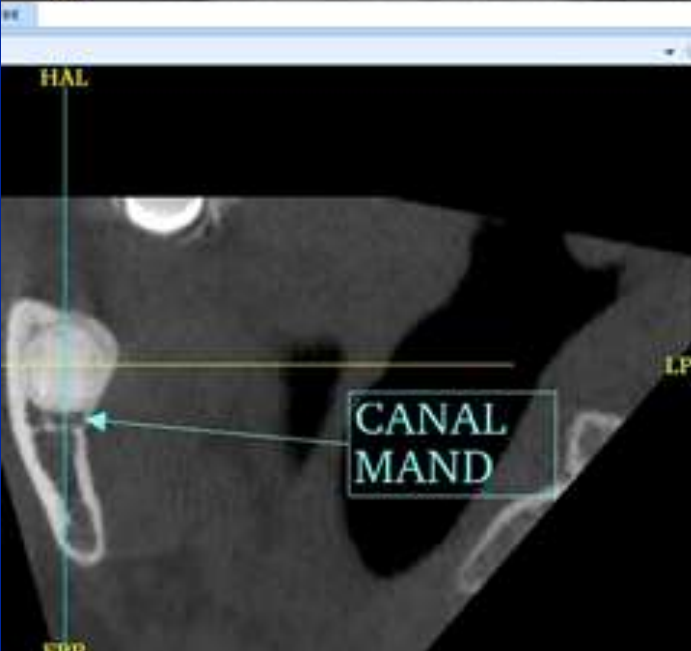
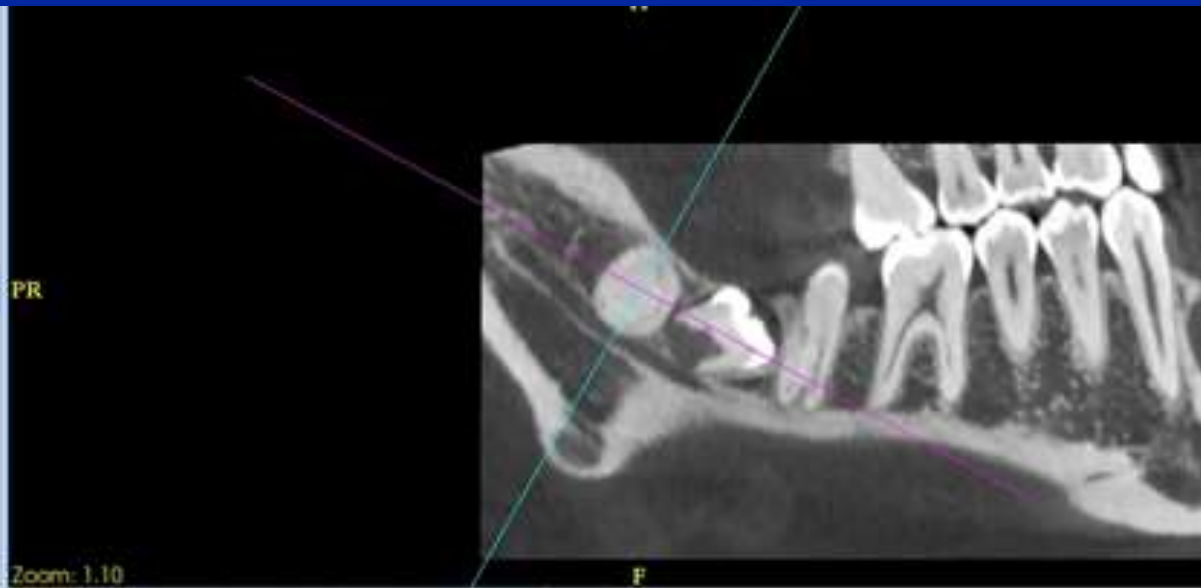
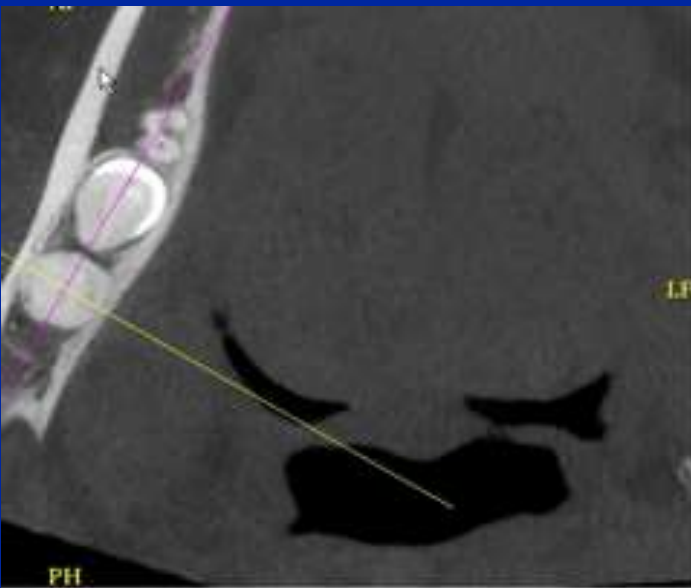.odontomes composés: le tissu dentaire constituant une masse difforme et dense...



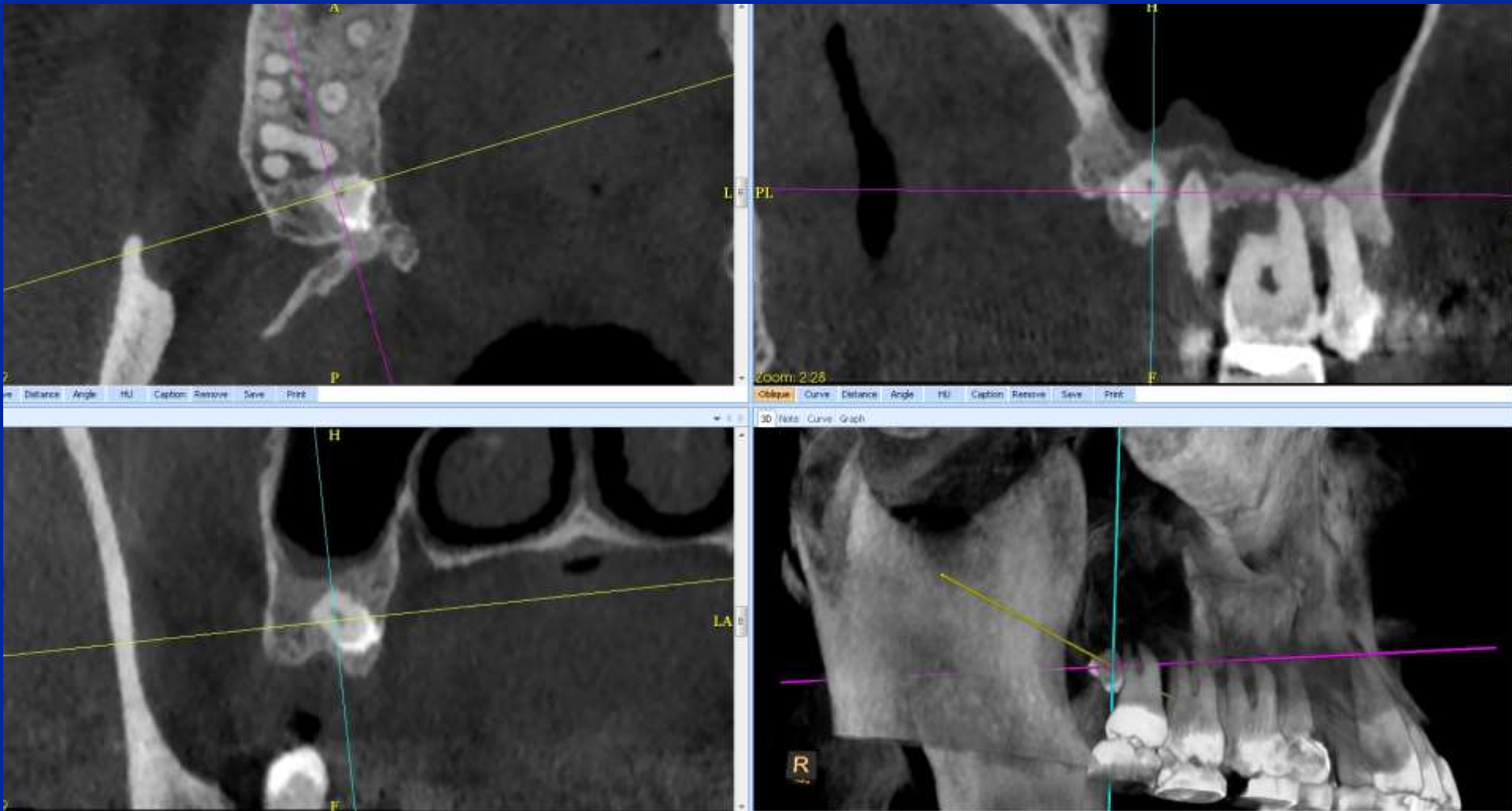
CONE BEAM ET ODF



CONE BEAM ET ODF



CONE BEAM ET ODF



DENTS SURNUMERAIRES
4^{ème} MOLLAIRE+++

www.conebeamparis.com

Les anomalies de situation sont dominées par les inclusions.

L'INCLUSION DES CANINES MAXILLAIRES est la plus fréquente.

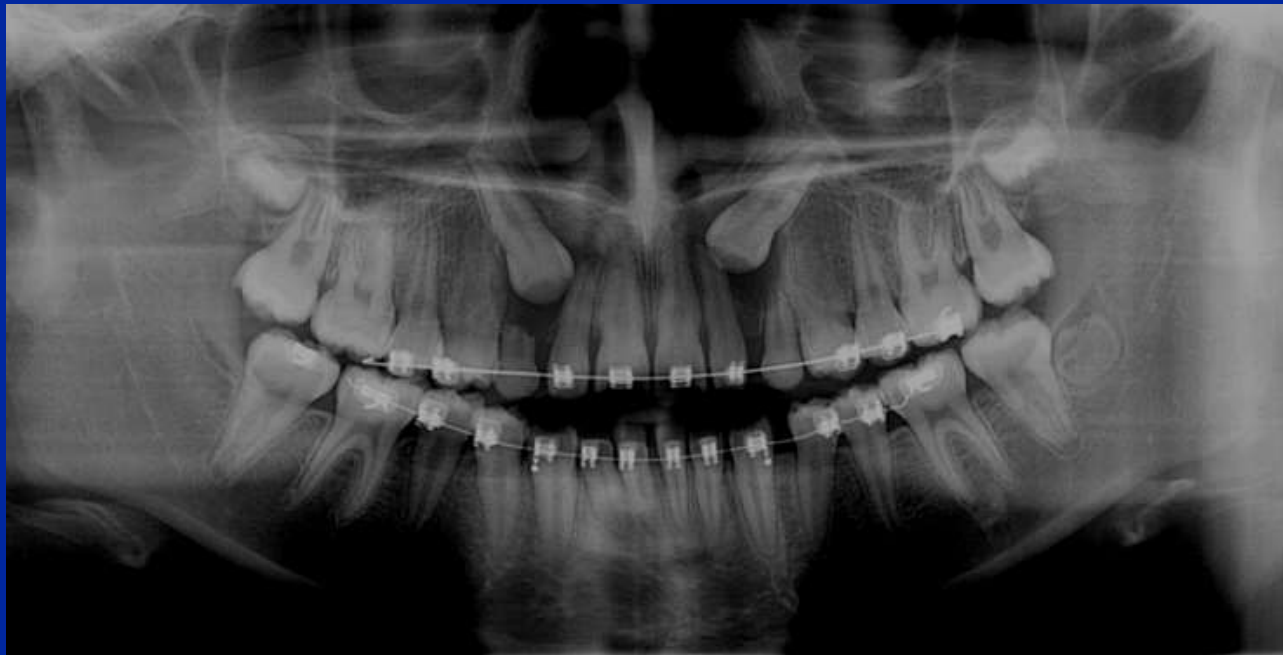***AGIR AVANT MATURATION+++ (12 ans), sinon, risque d'ANKYLOSE.**

***IMAGERIE**

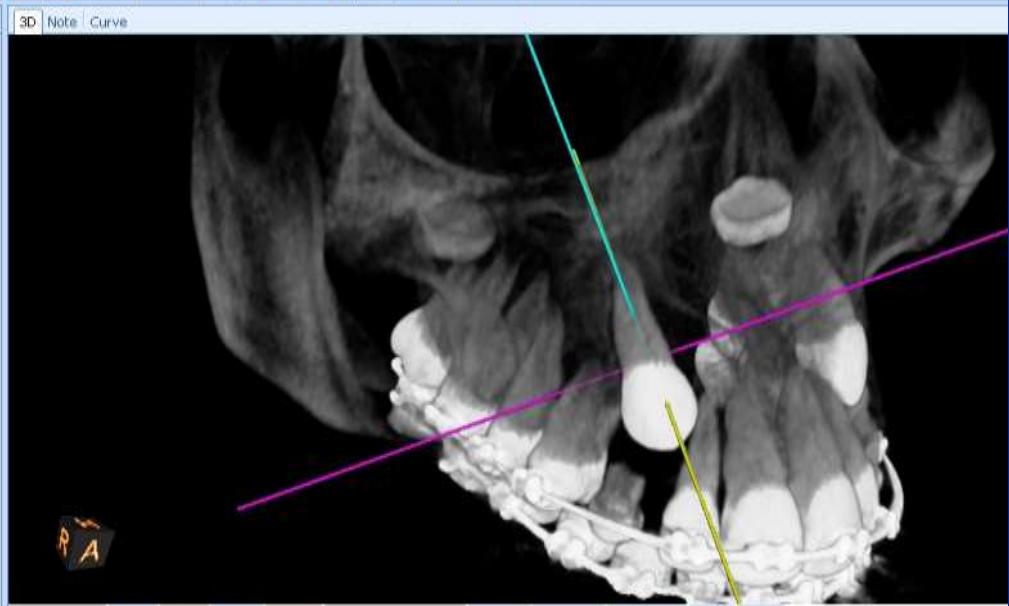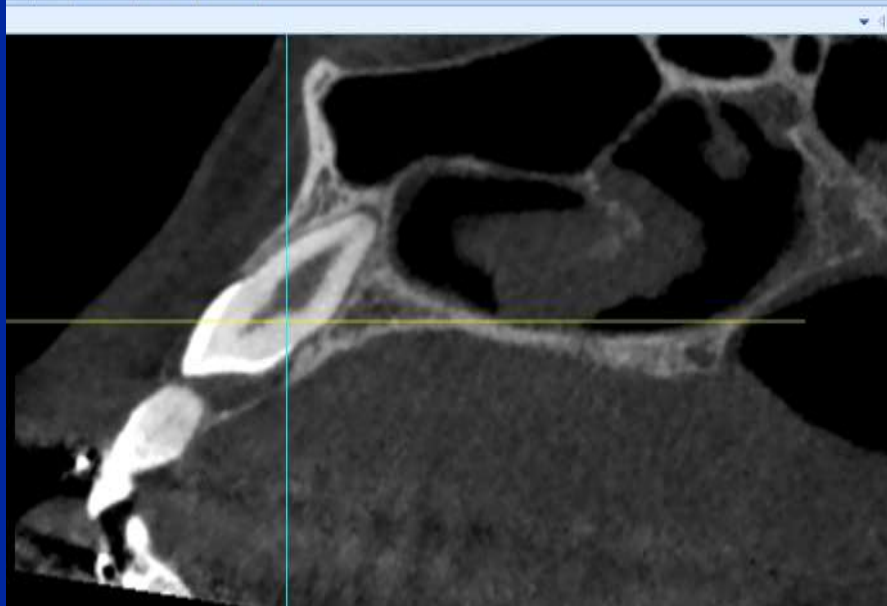
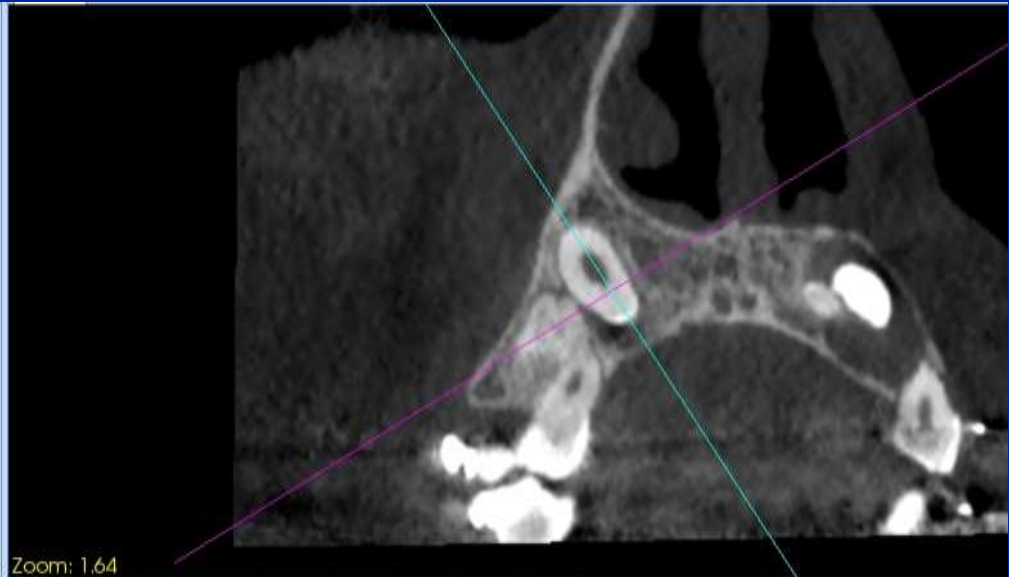
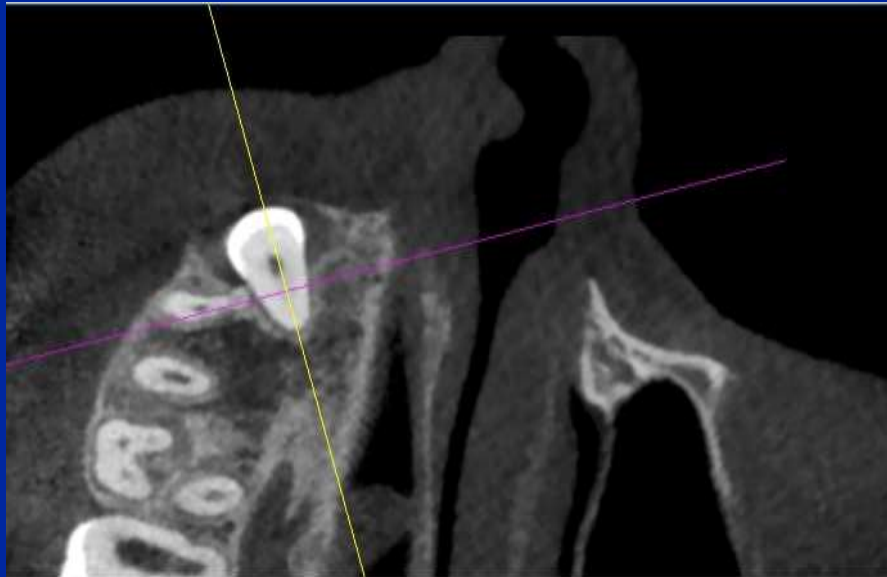
❑ LE PANORAMIQUE élimine la rare agénésie et situe la dent sur le plan vertical;

❑ LE CONE BEAM précise

- les caractères morphologiques de la dent,
- ses rapports et complications propres (ankylose, hypercémentose, carie...)
- l'éventualité d'un kyste péri-coronaire et de ses complications...



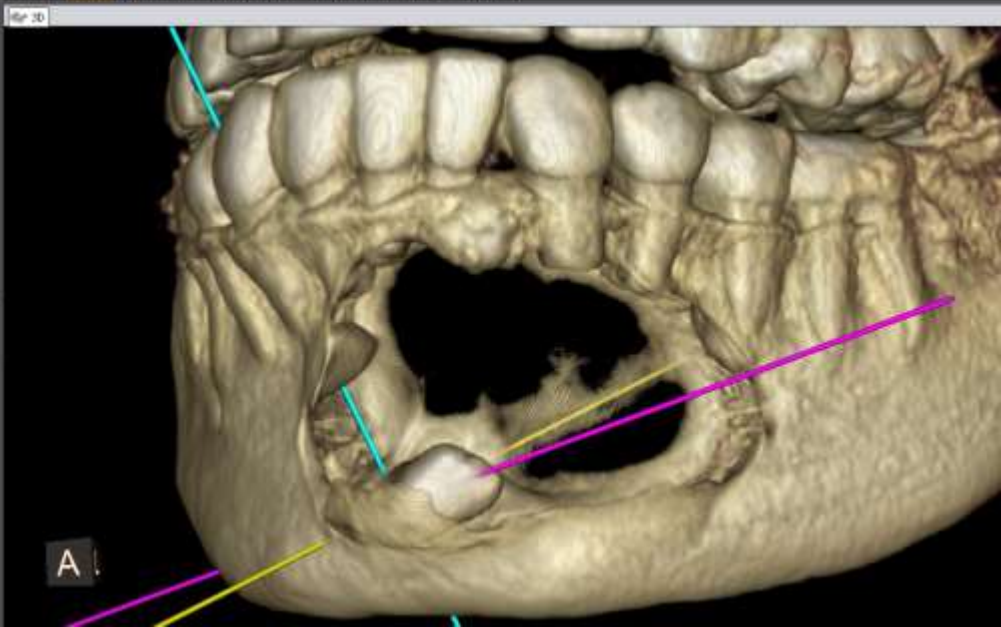
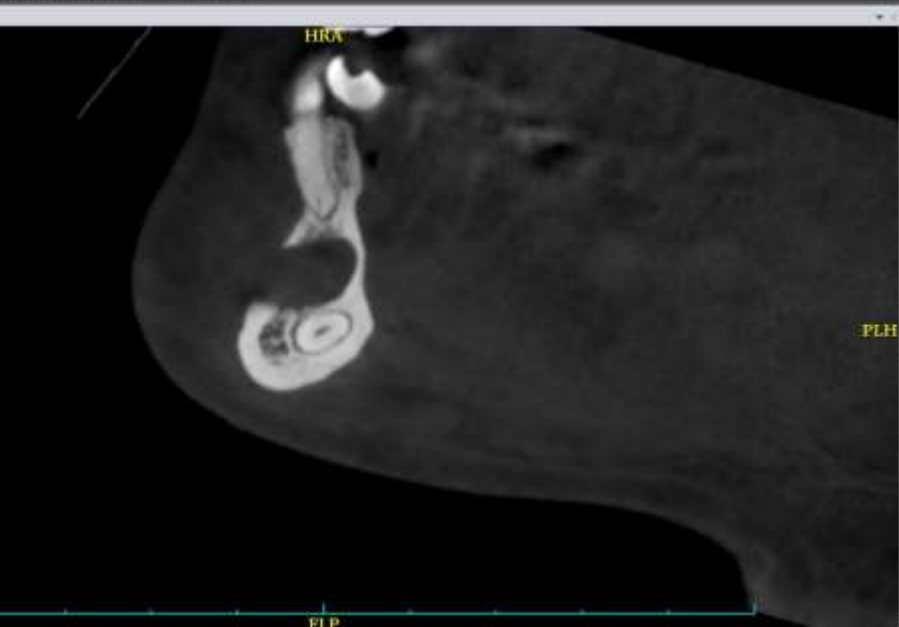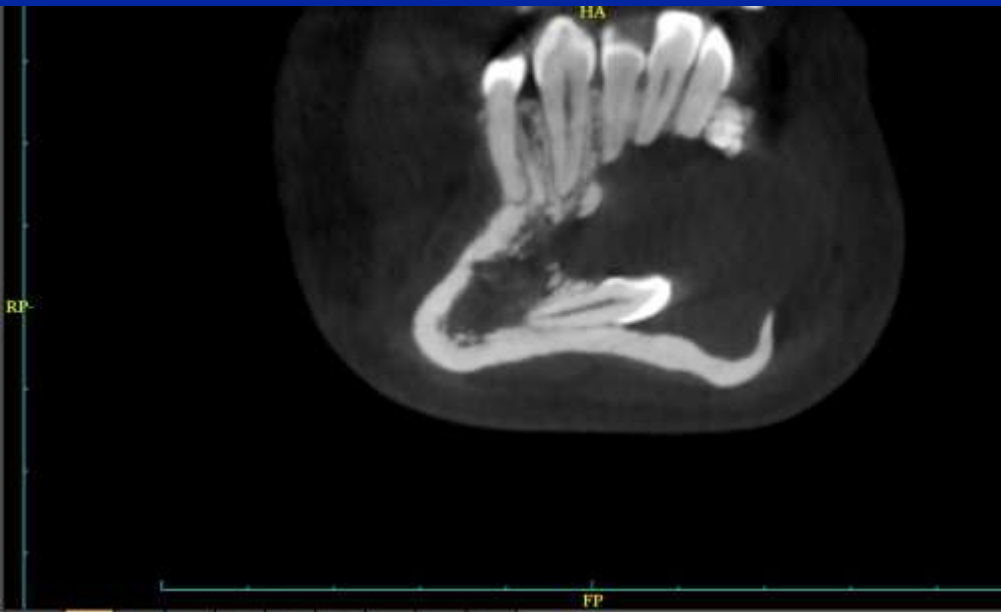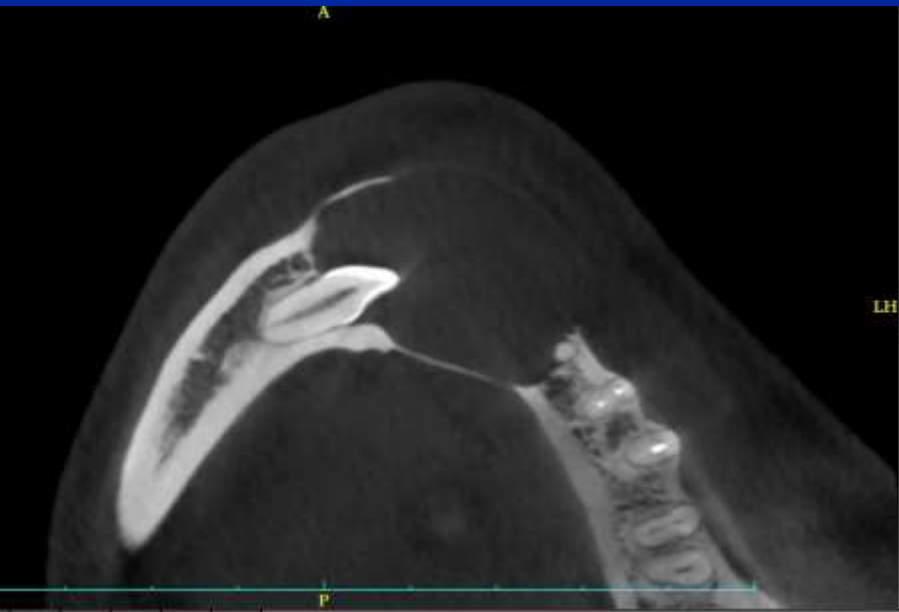CONE BEAM ET ODF



CANINES INCLUDES

www.conebeamparis.com

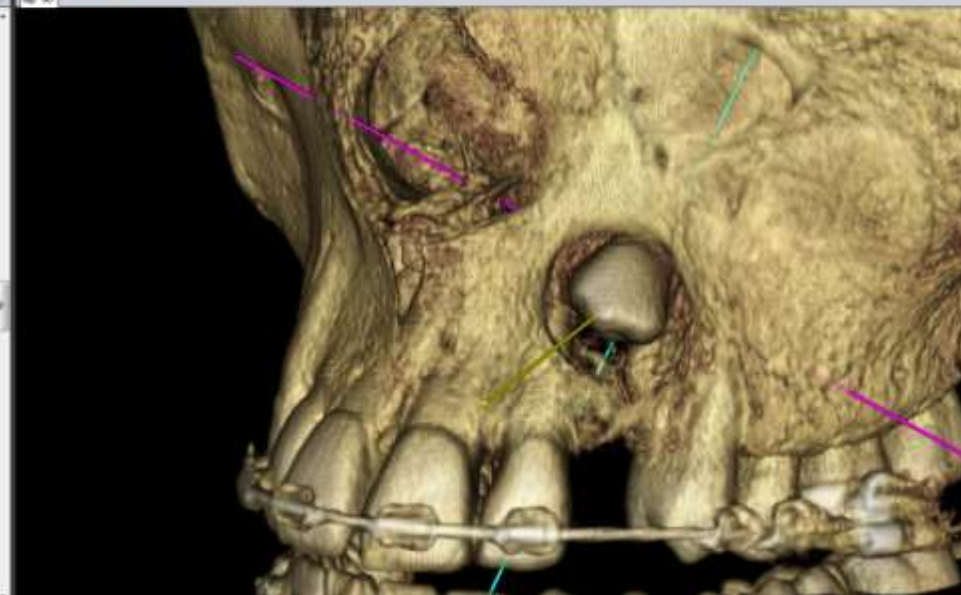
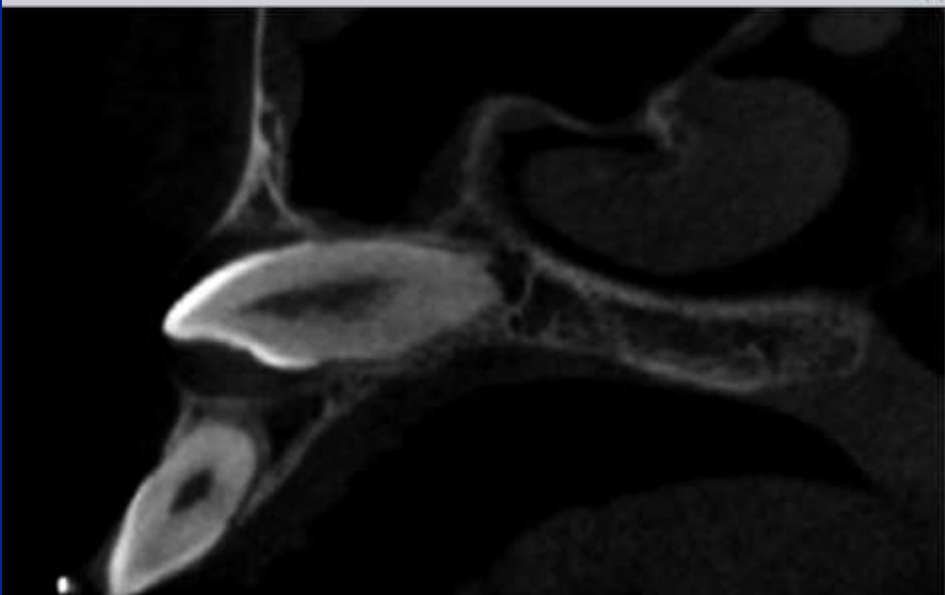
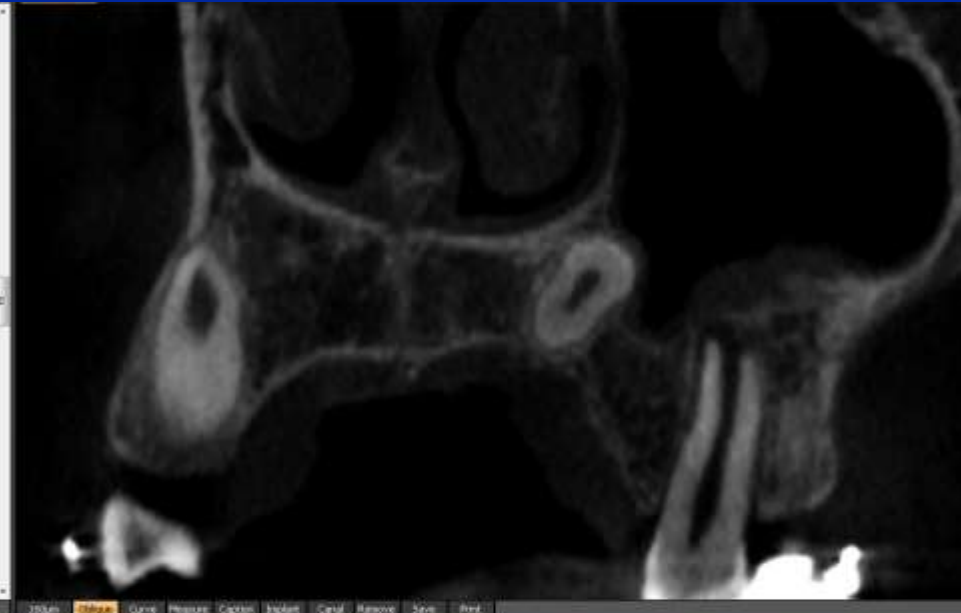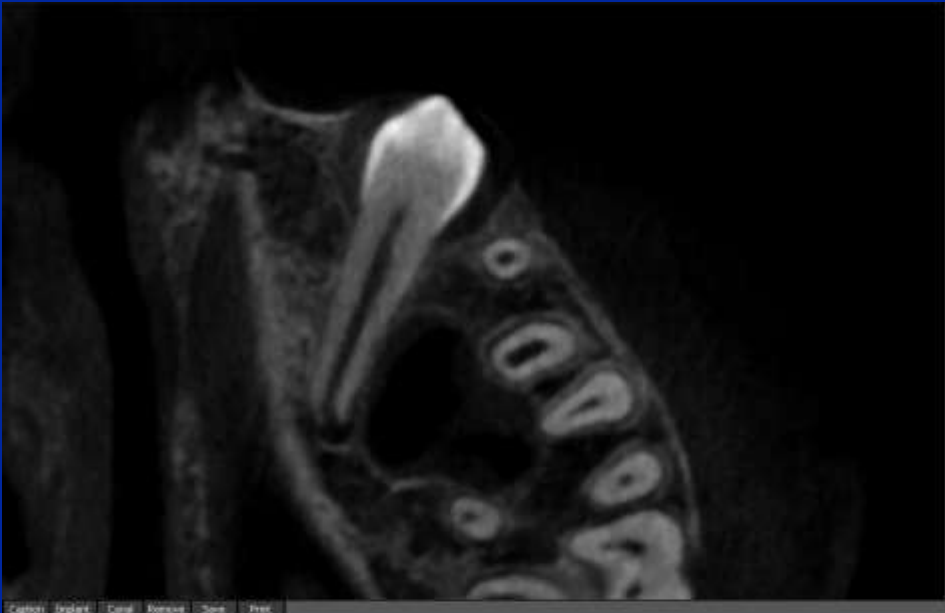
CONE BEAM ET ODF



CANINE INCLUSE ET KYSTE PERICORONAIRE

www.conebeamparis.com

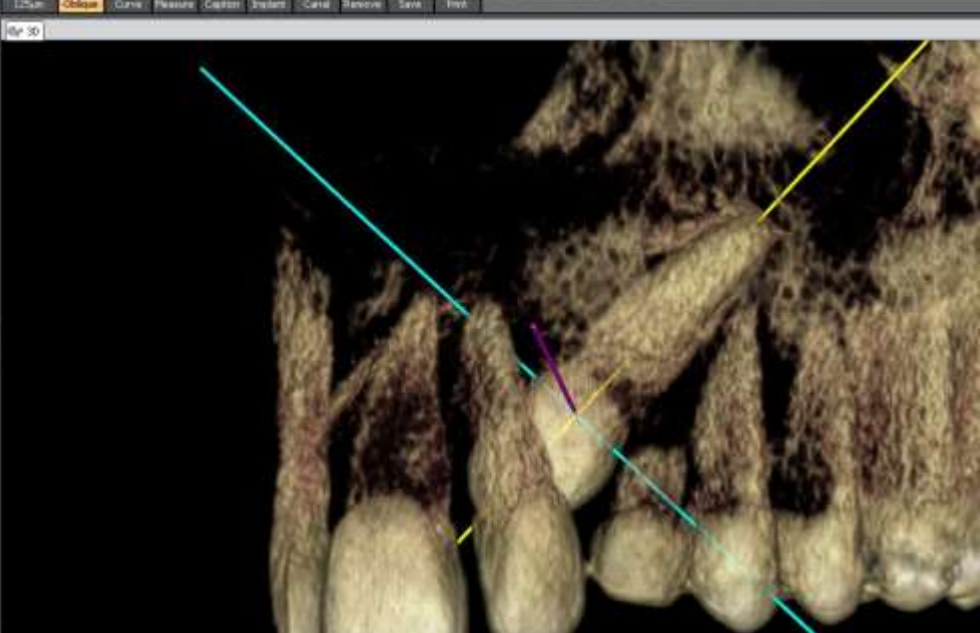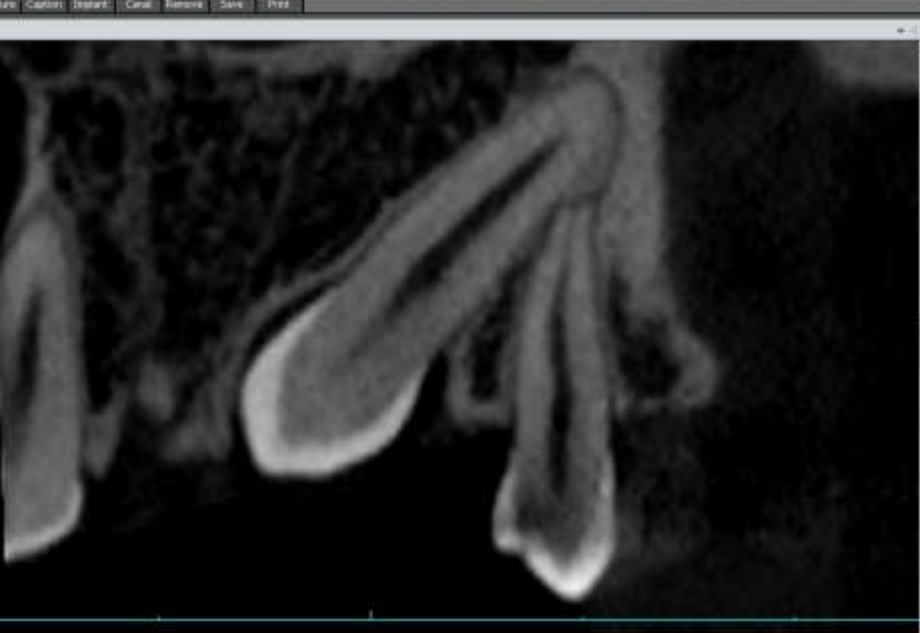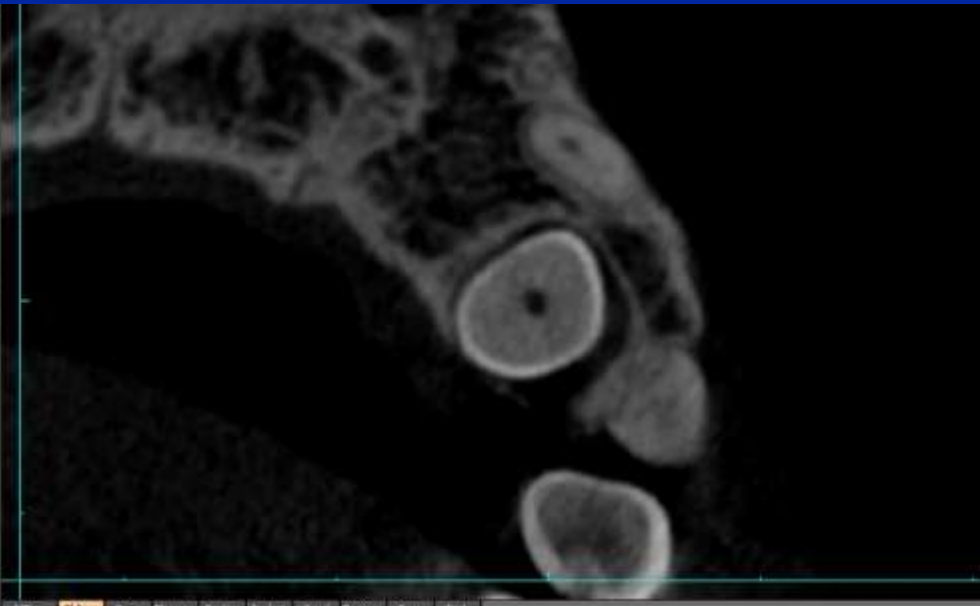
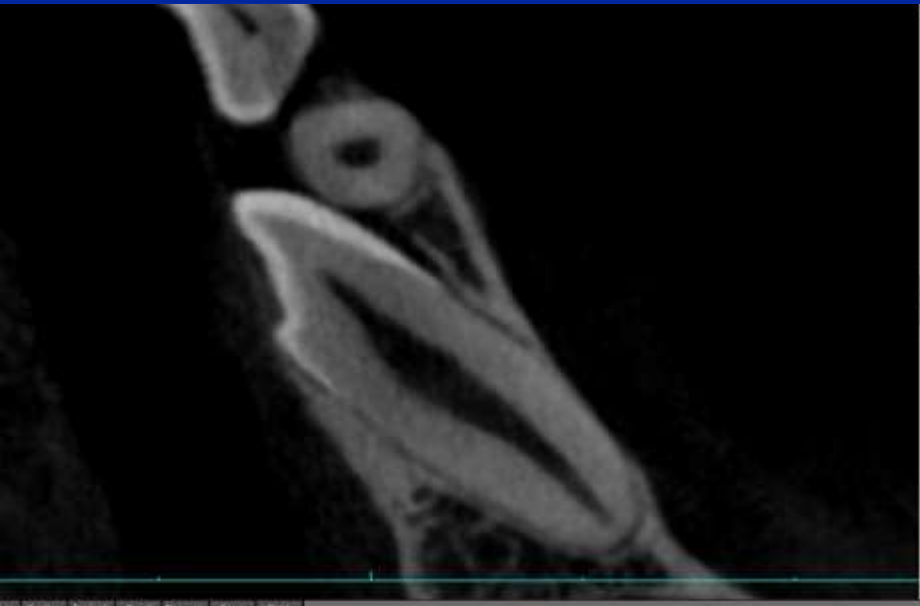
CONE BEAM ET ODF



CANINE INCLUSE ET ANKYLOSE DEBUTANTE

www.conebeamparis.com

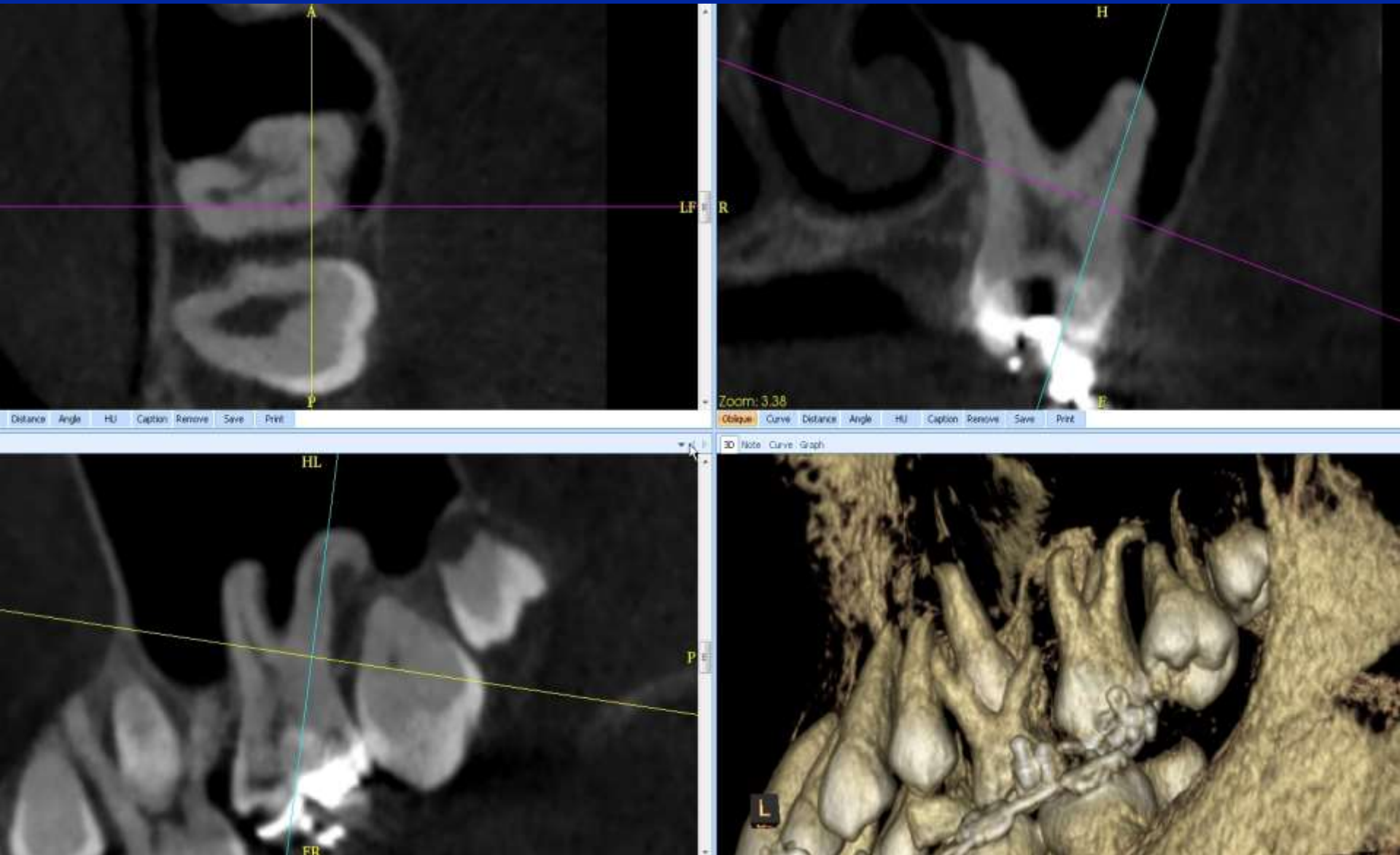
CONE BEAM ET ODF



CANINE INCLUSE ET HYPERCEMENTOSE

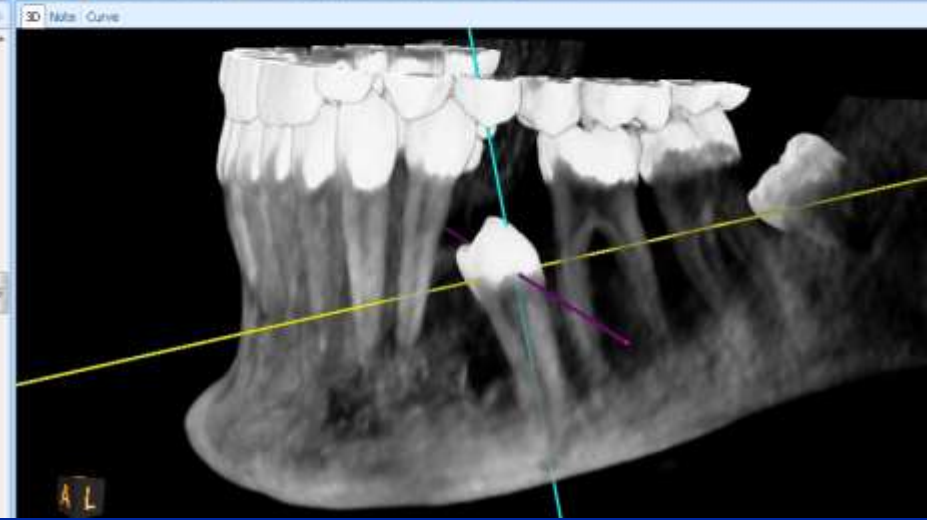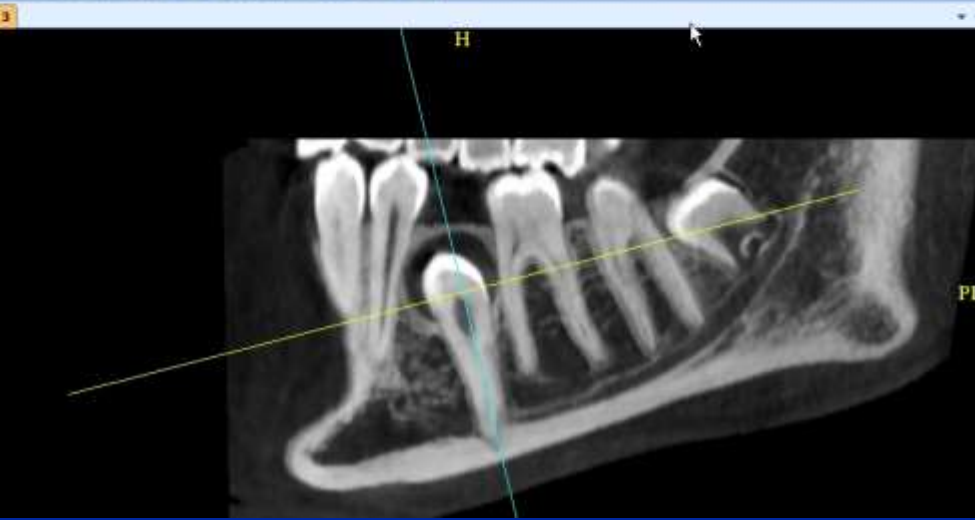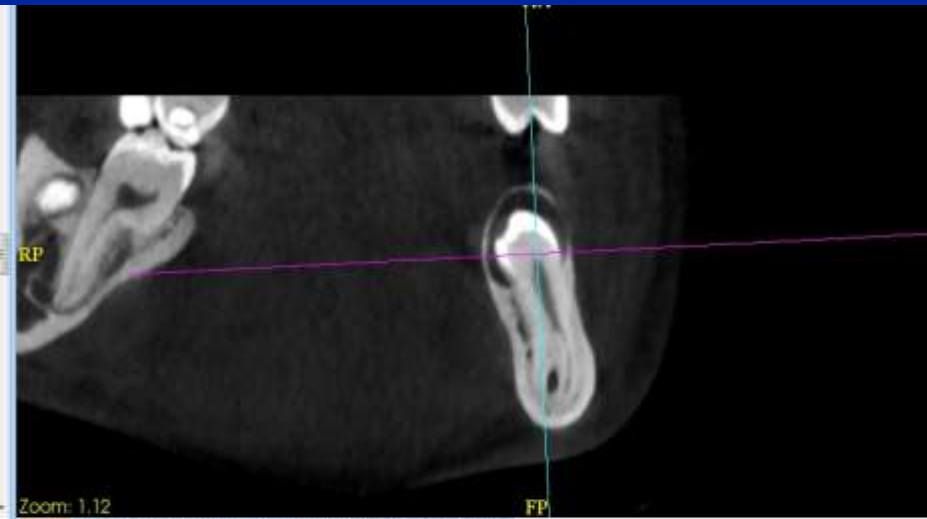
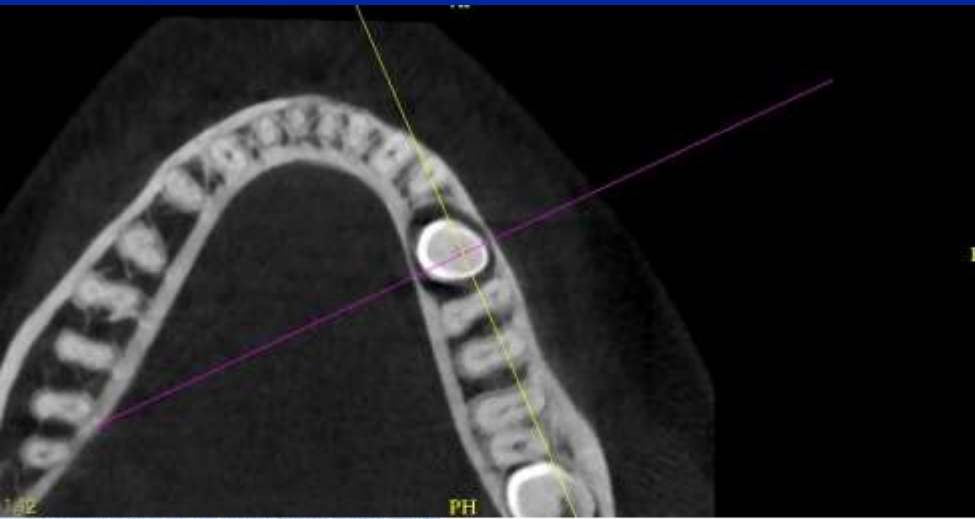www.conebeamparis.com

CONE BEAM ET ODF



DYSMORPHIE DE 26, RACINE COURBE www.conebeamparis.com

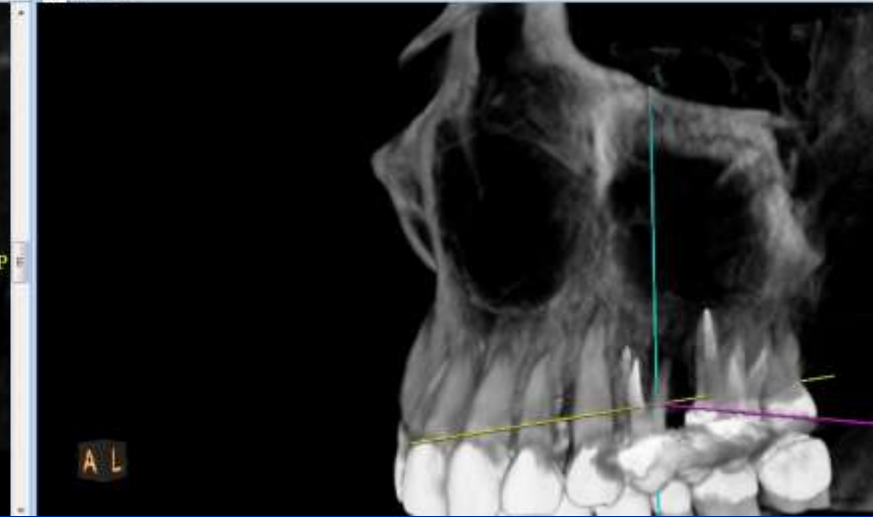
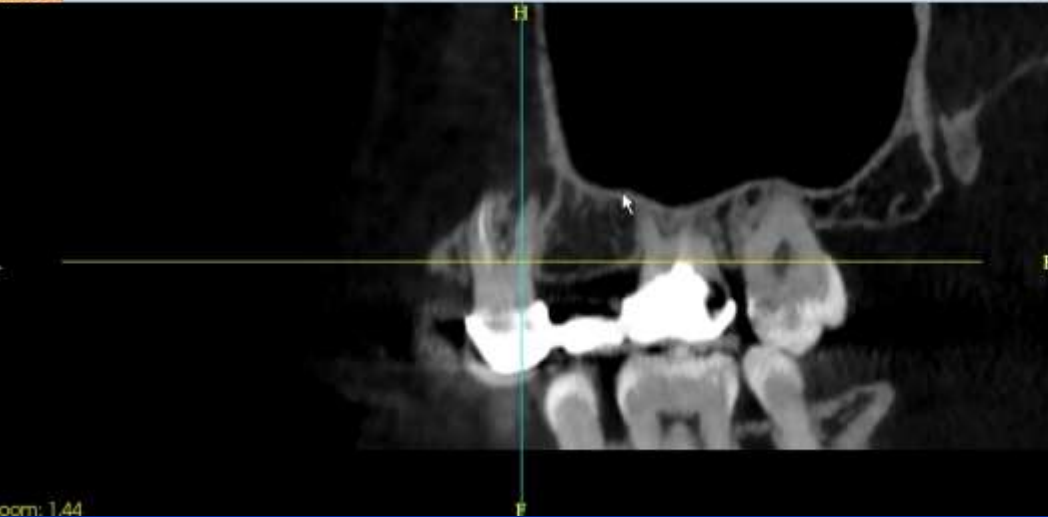
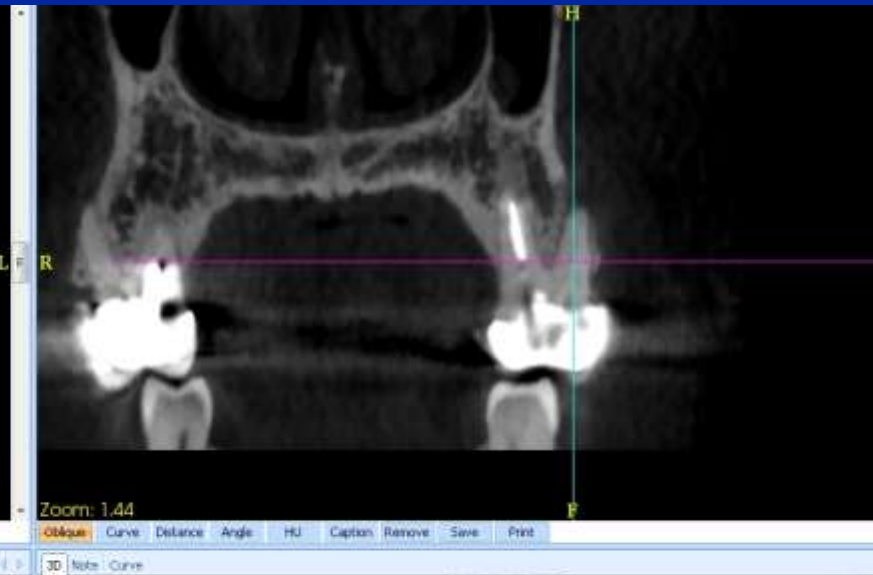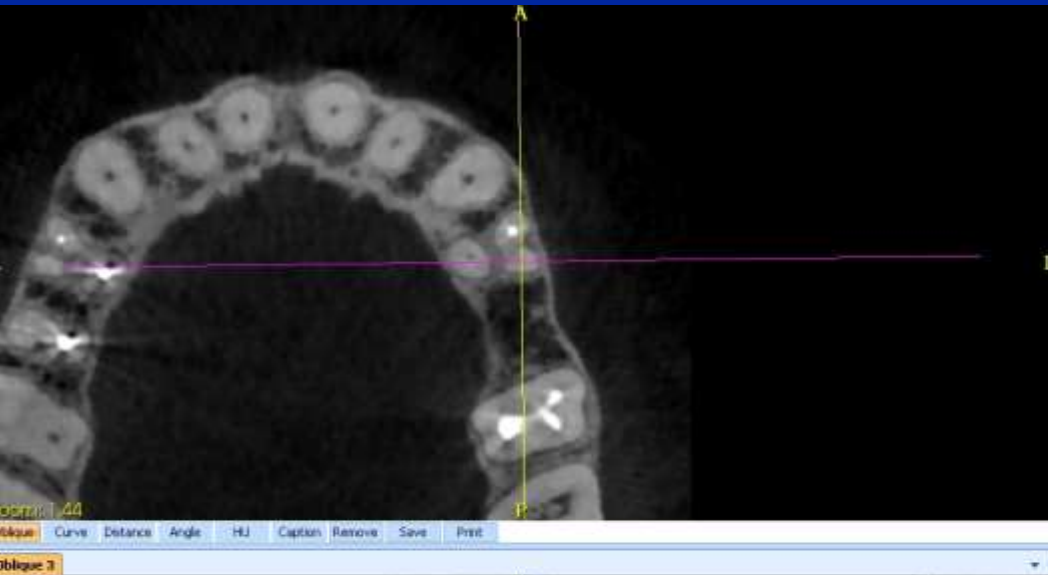CONE BEAM ET ODF



**DYSMORPHIE DE 35, racines courbes,
CANAL INTER-RADICULAIRE**

www.conebeamparis.com

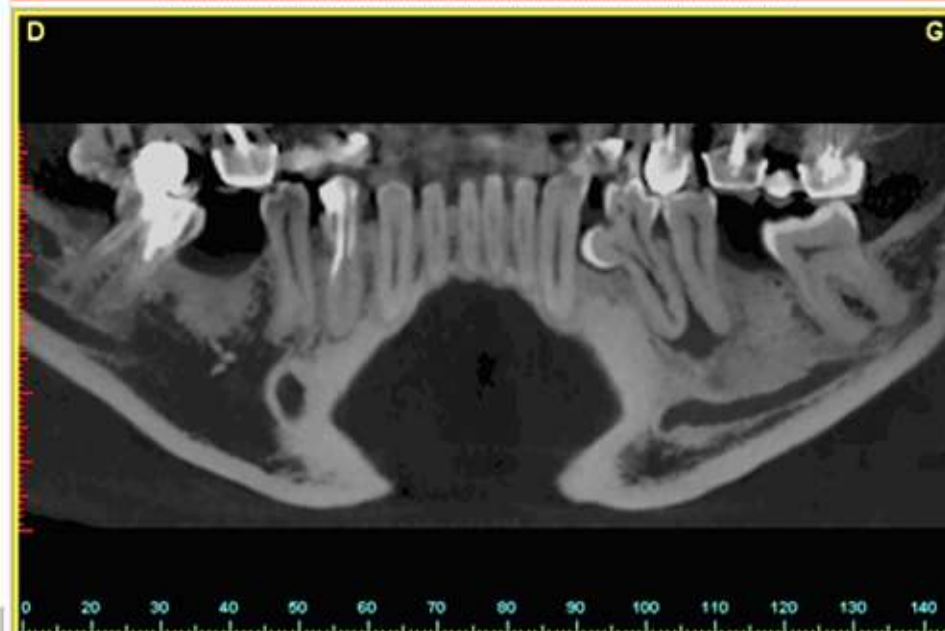
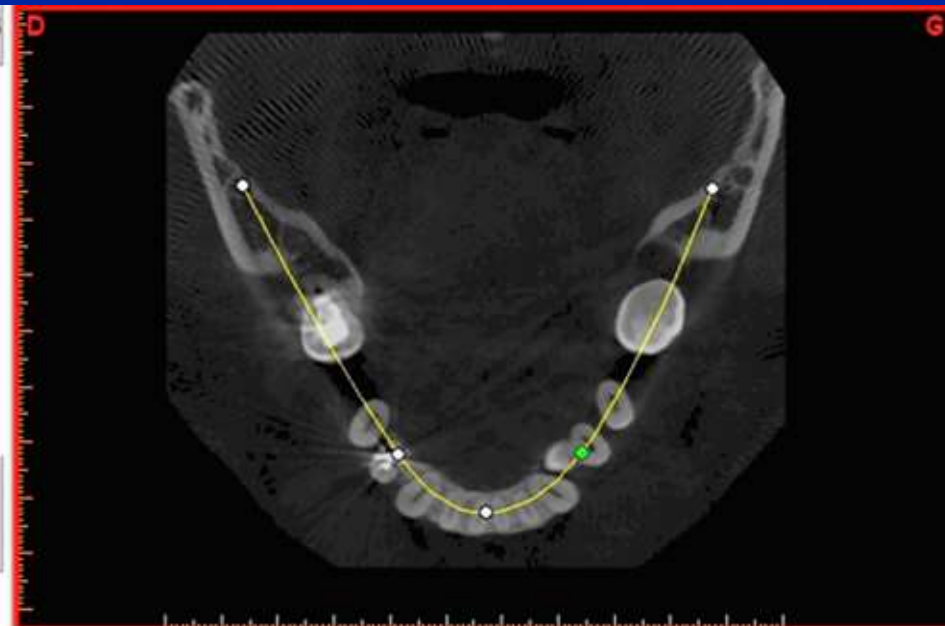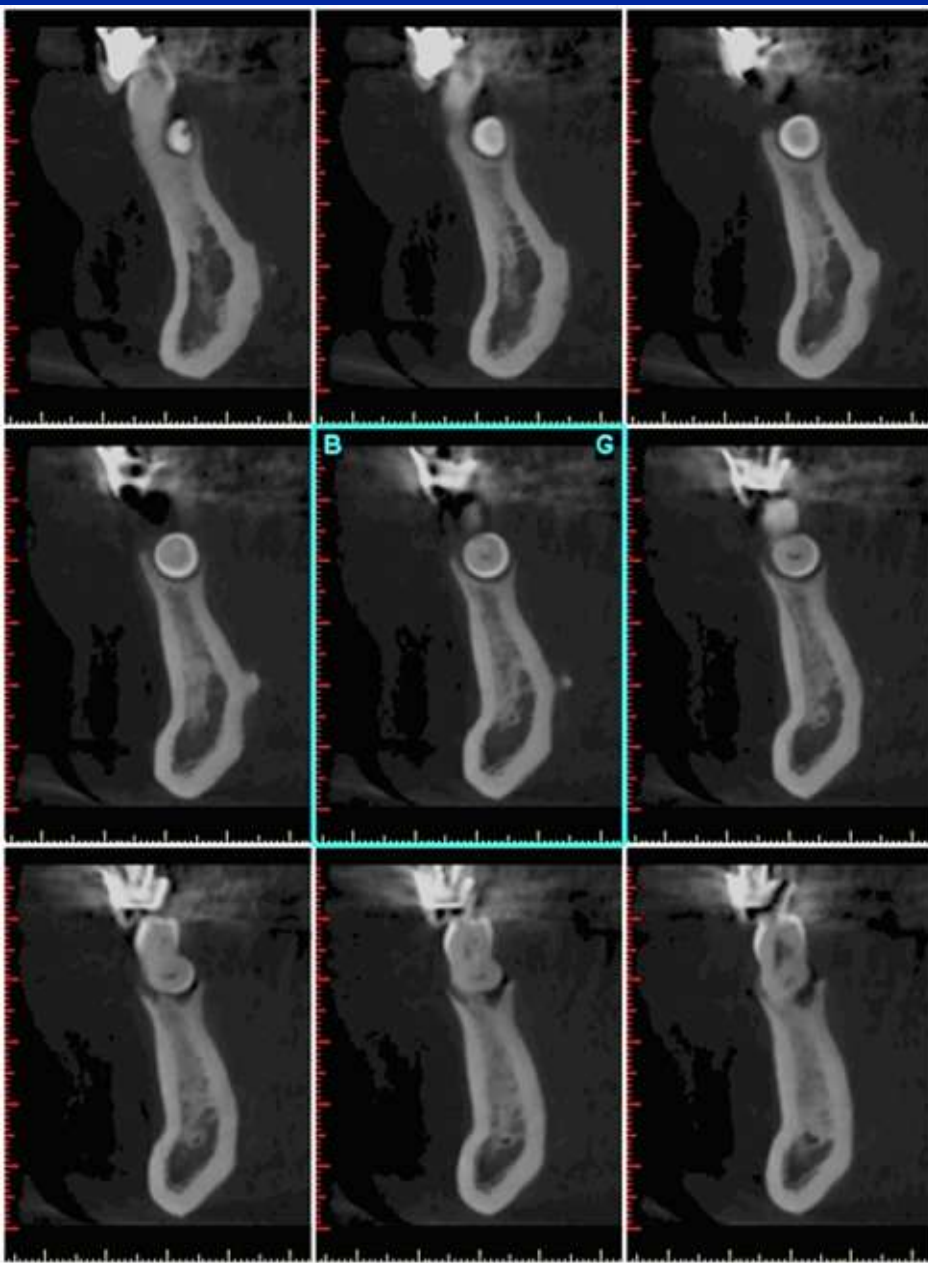
CONE BEAM ET ODF



24 TRIRADICULEE,+ granulome

www.conebeamparis.com

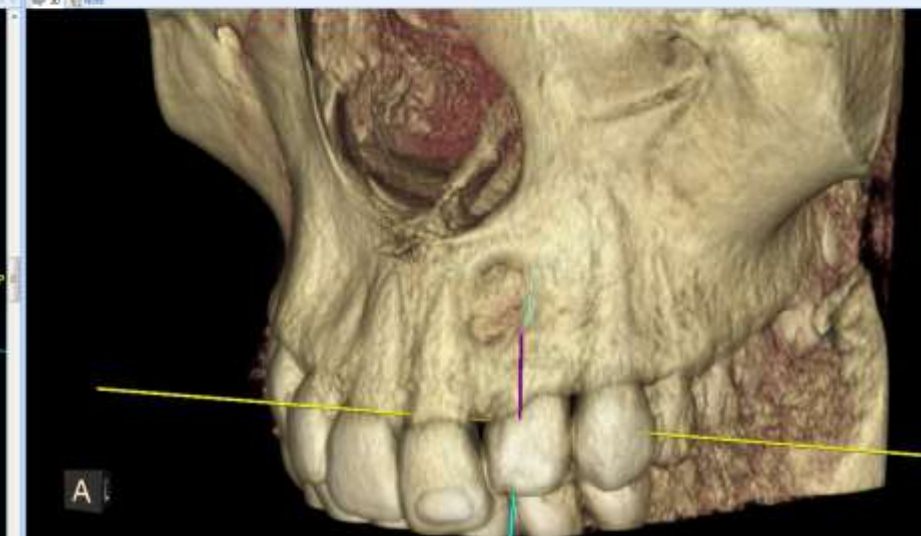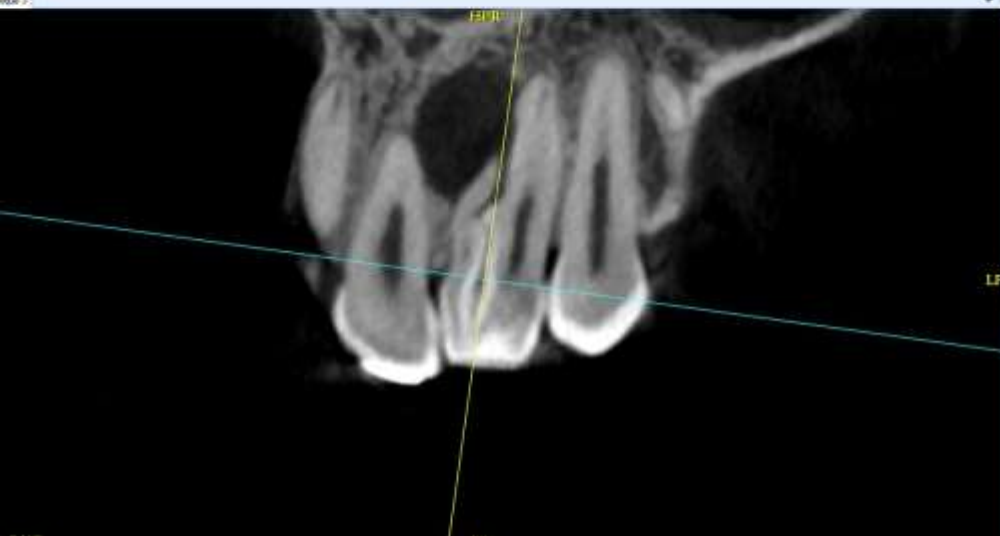
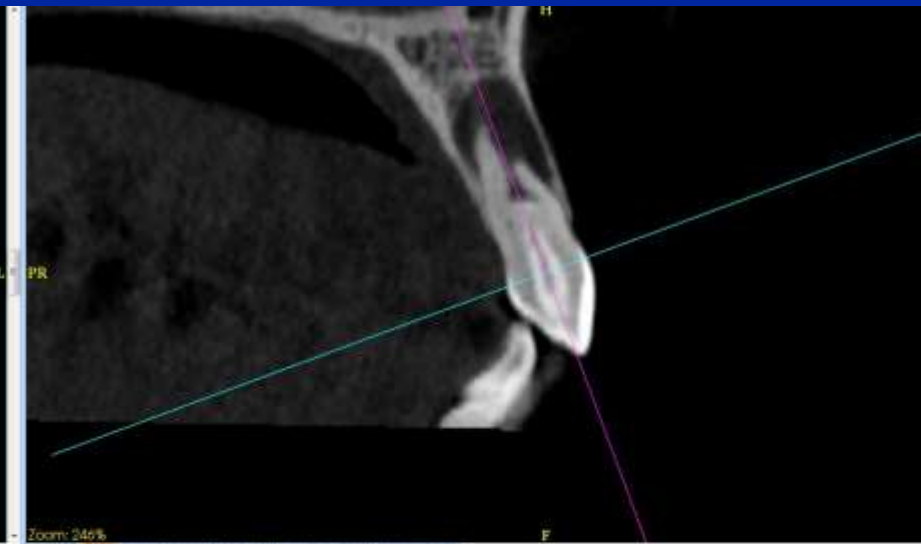
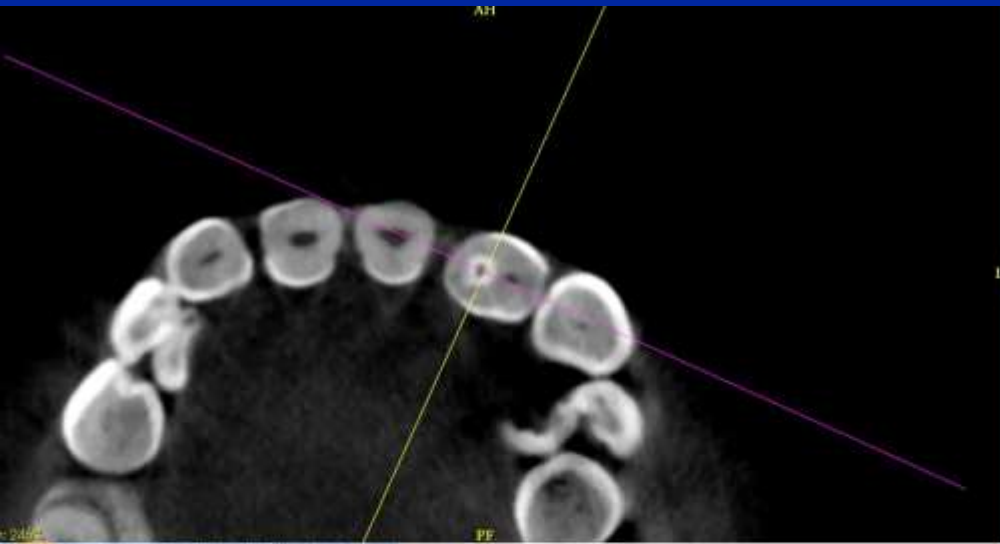
CONE BEAM ET ODF



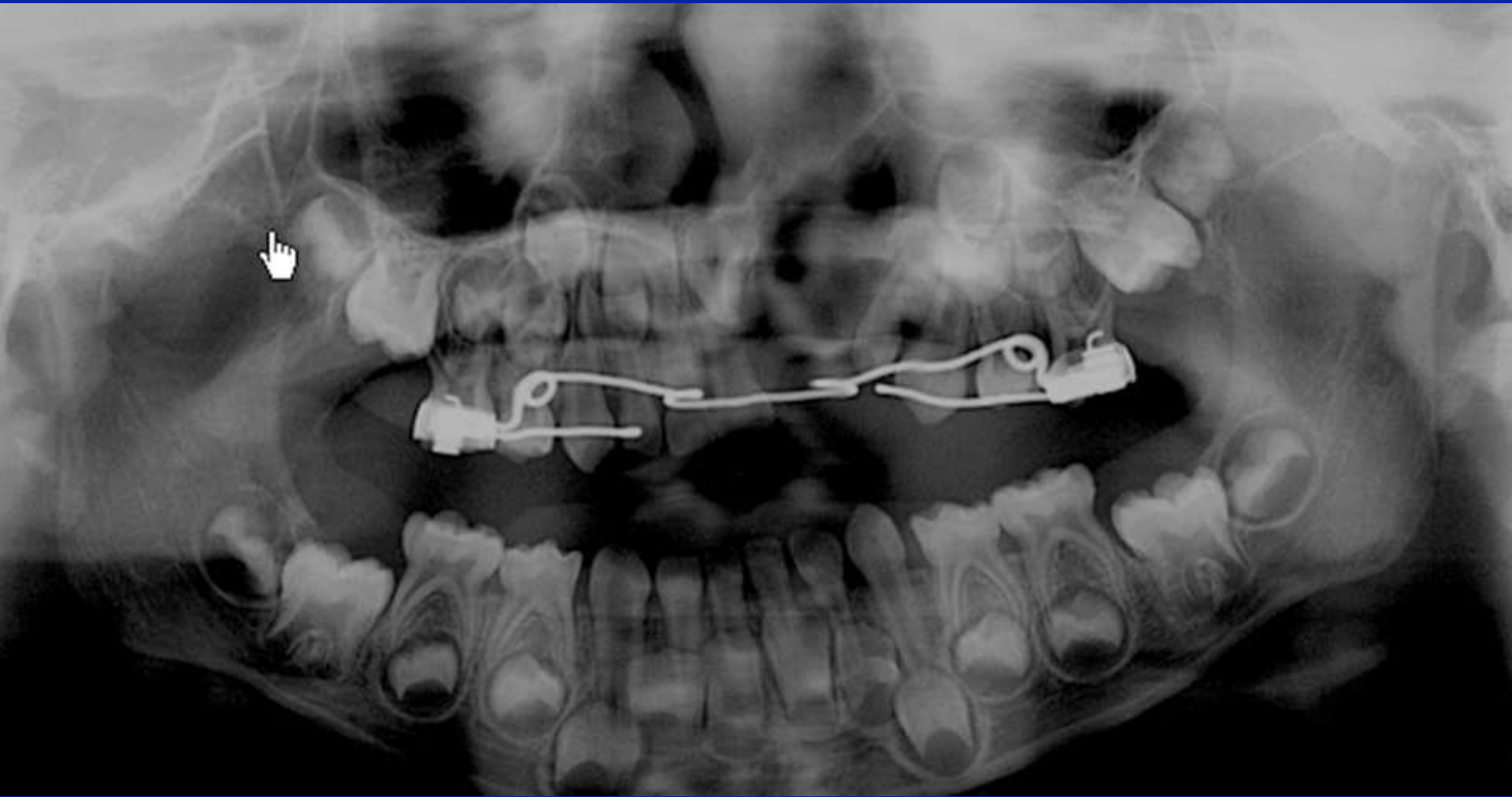
DYSMORPHIE DE 34, BICORONAIRE

www.conebeamparis.com

CONE BEAM ET ODF



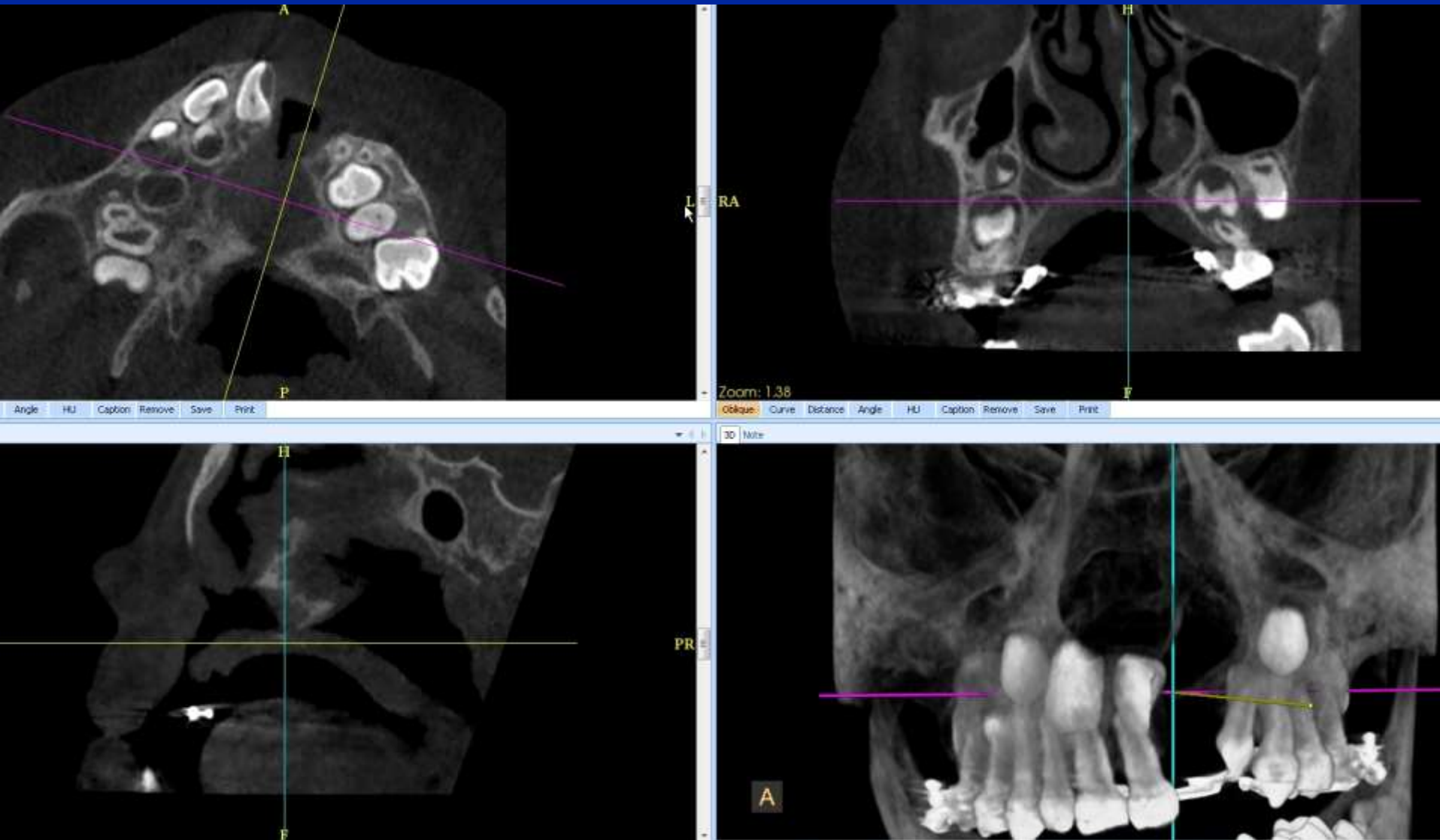
CONE BEAM ET ODF



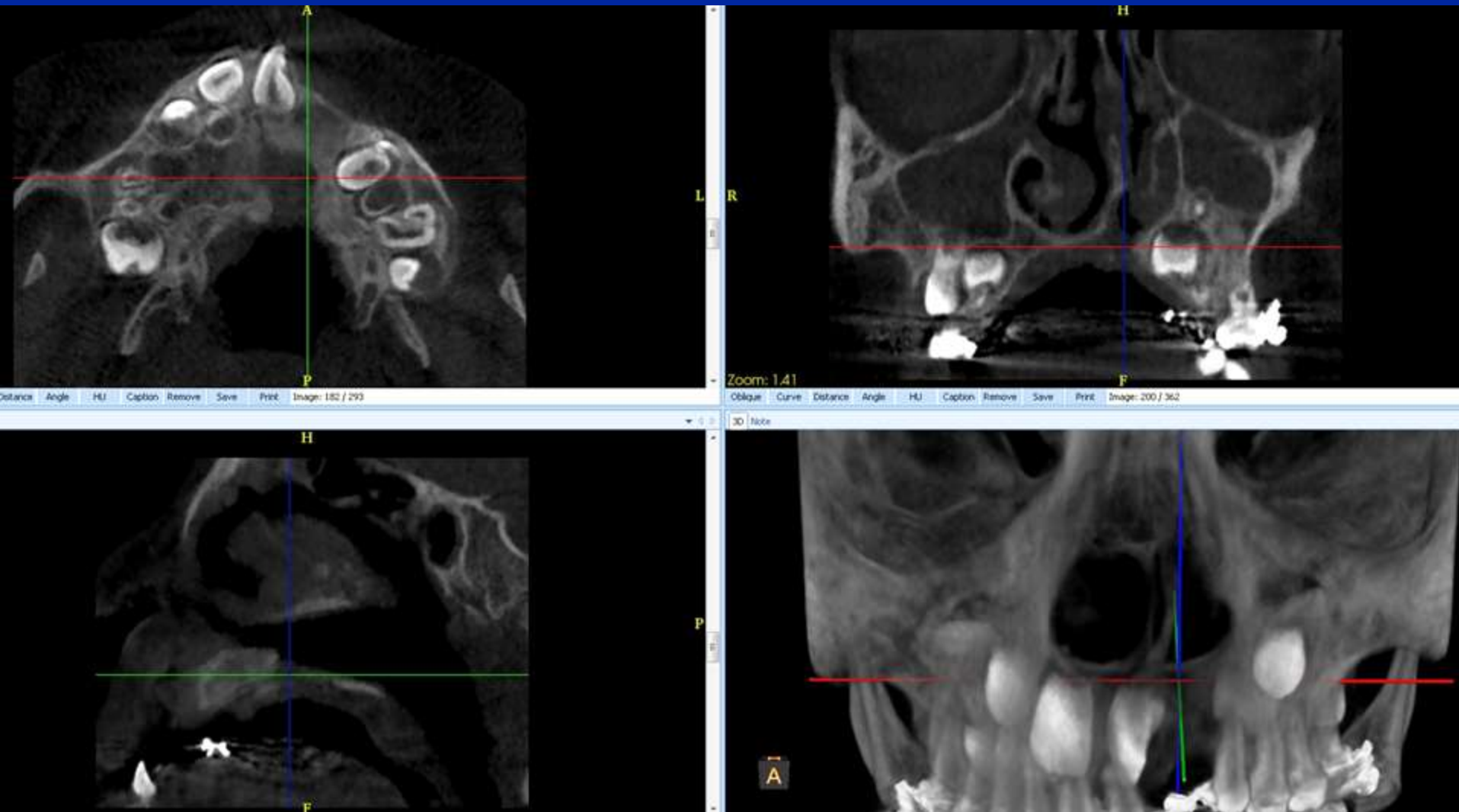
FENTE PALATINE PARAMEDIANE GAUCHE

www.conebeamparis.com

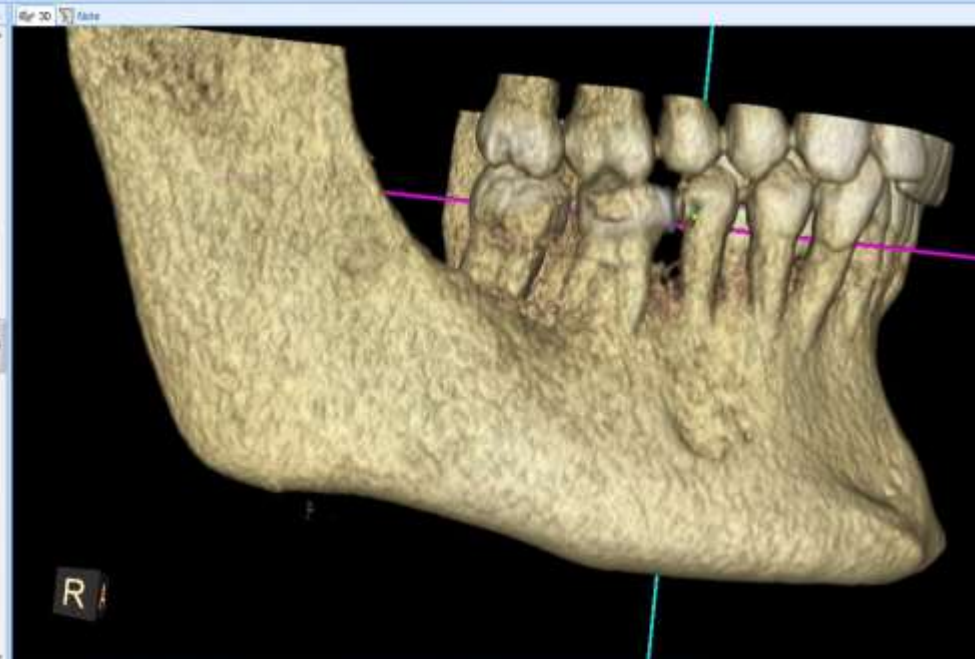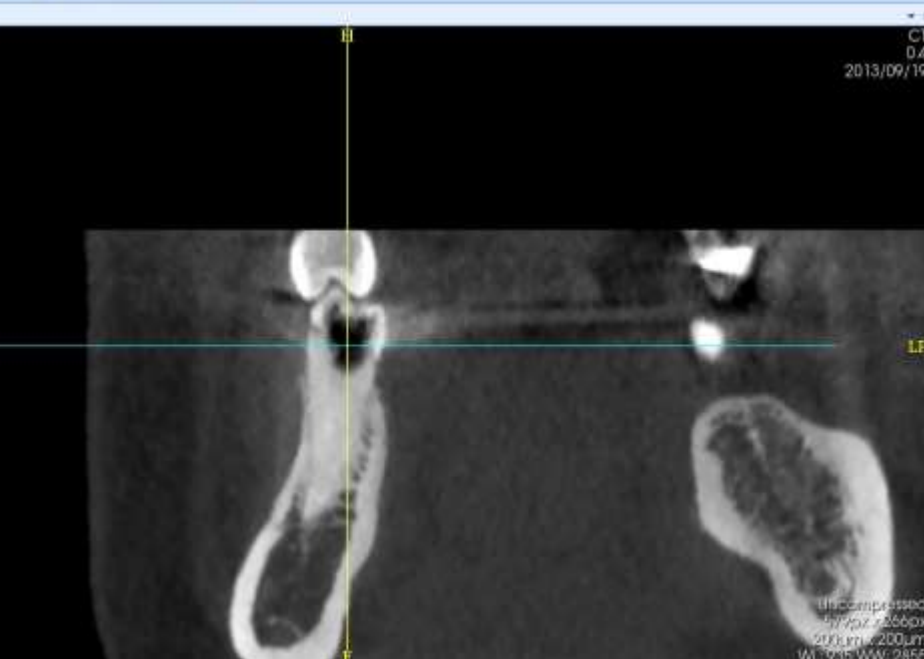
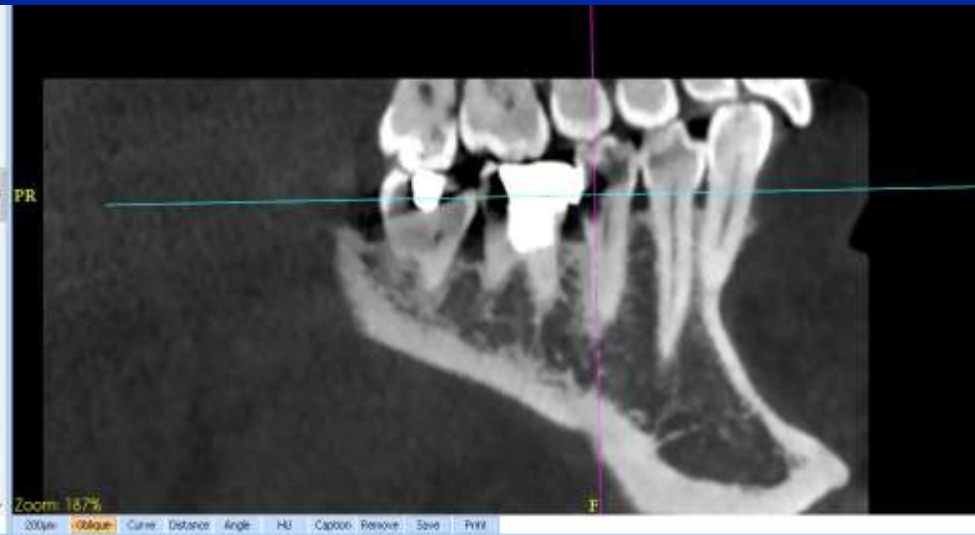
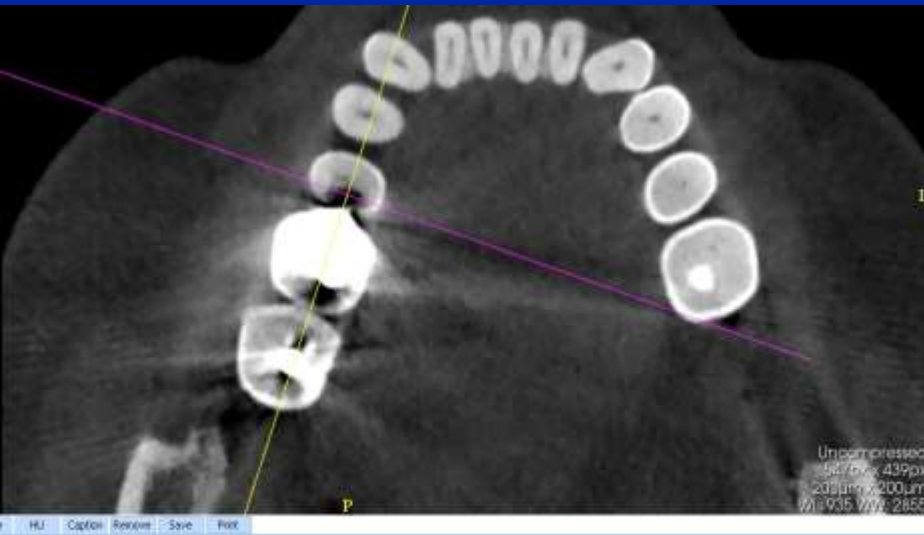CONE BEAM ET ODF



CONE BEAM ET ODF

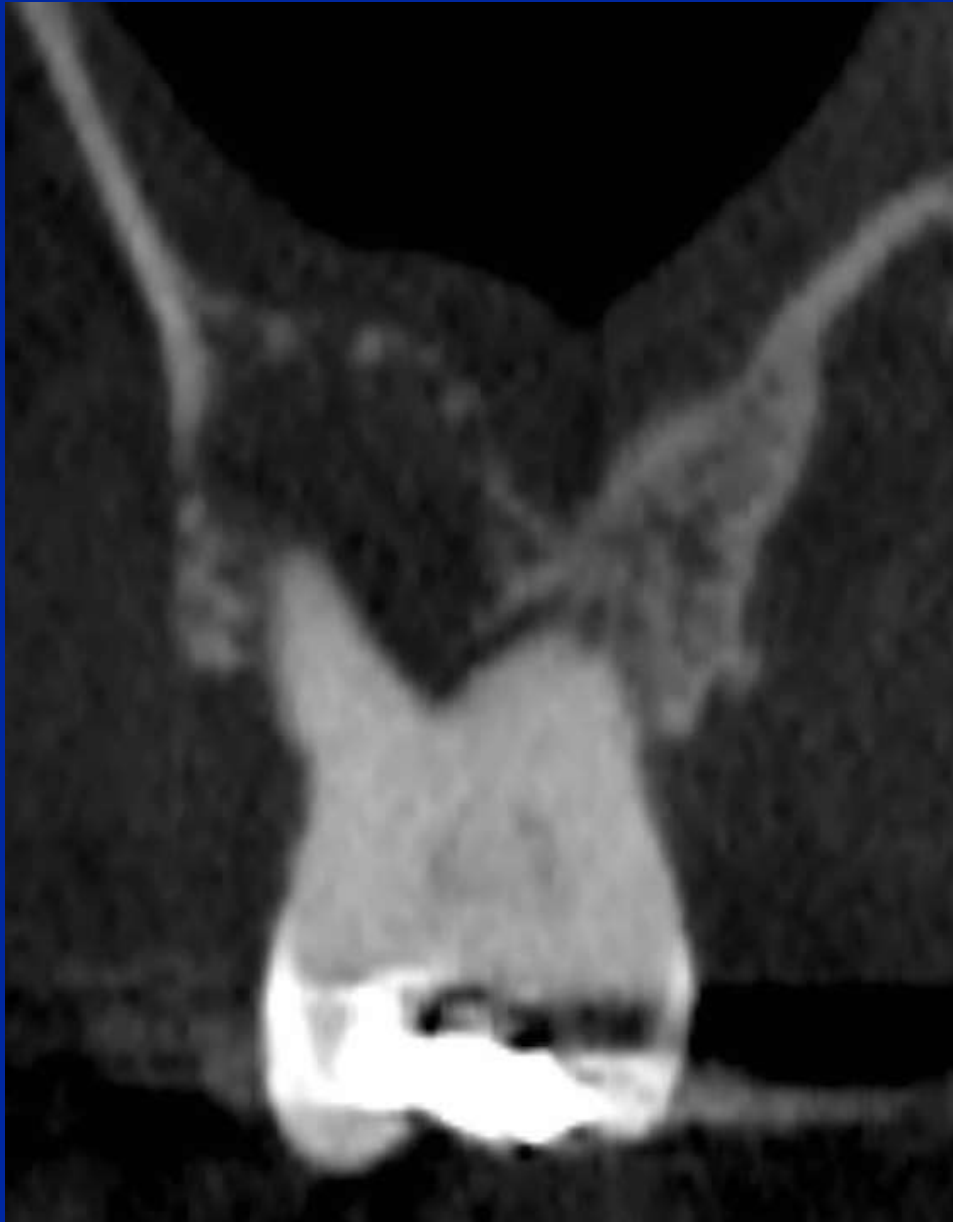


CONE BEAM EN ENDODONTIE ET PARODONTIE



VRAIE CARIE EN 45
PSEUDO CARIE EN 46 (ARTEFACT)

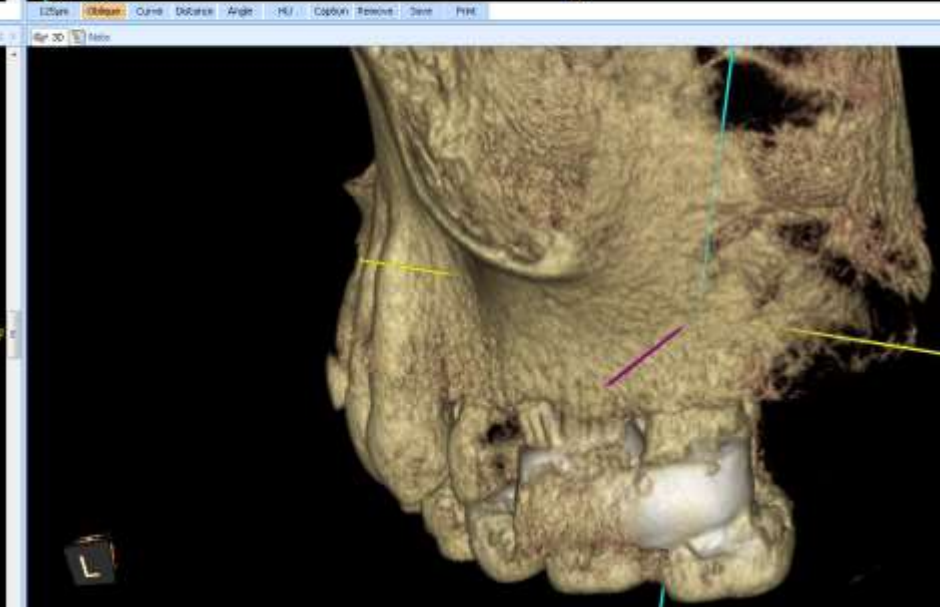
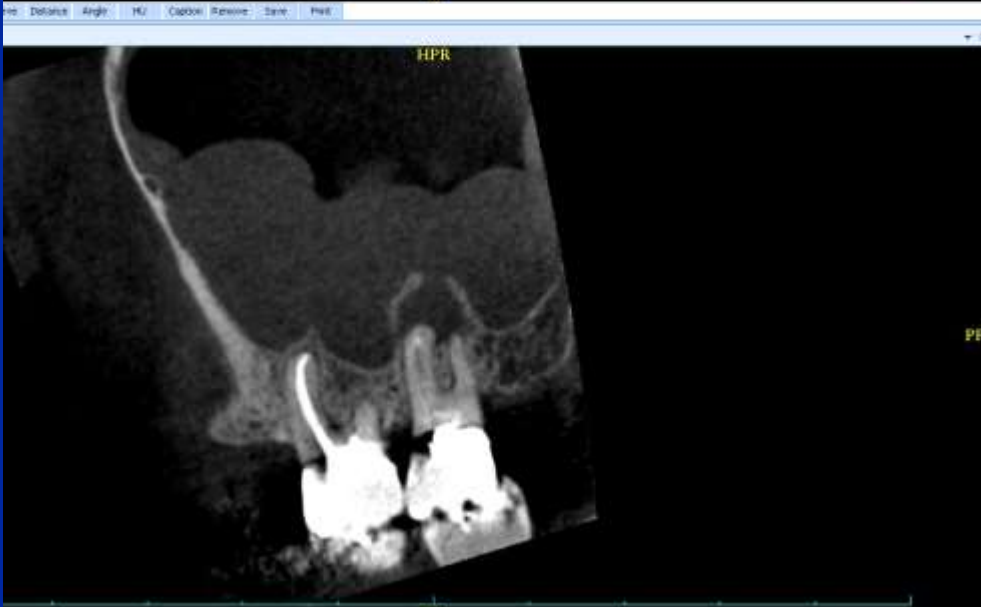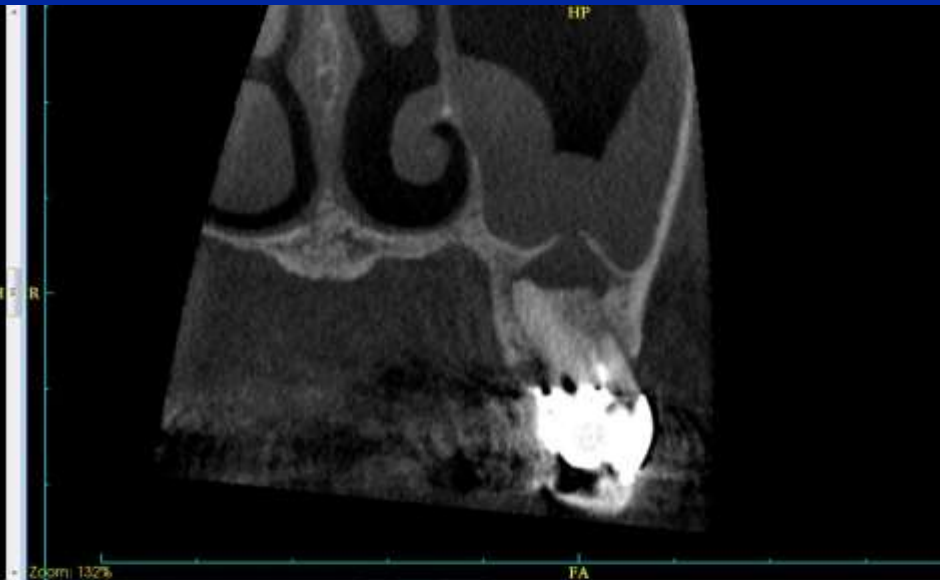
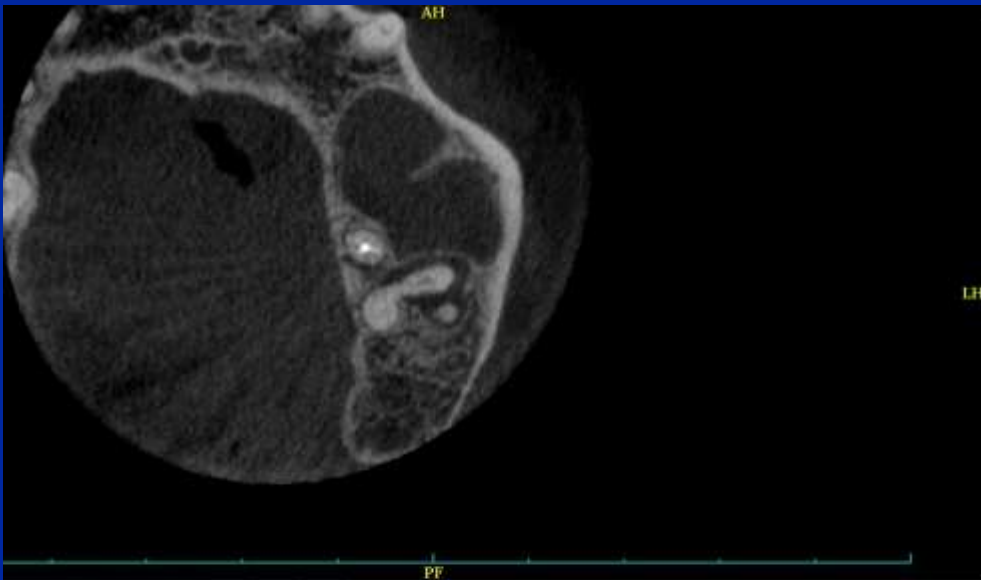
CONE BEAM EN ENDODONTIE ET PARODONTIE



GAD 27, MICROPERFORATIONS SINUSIENNES

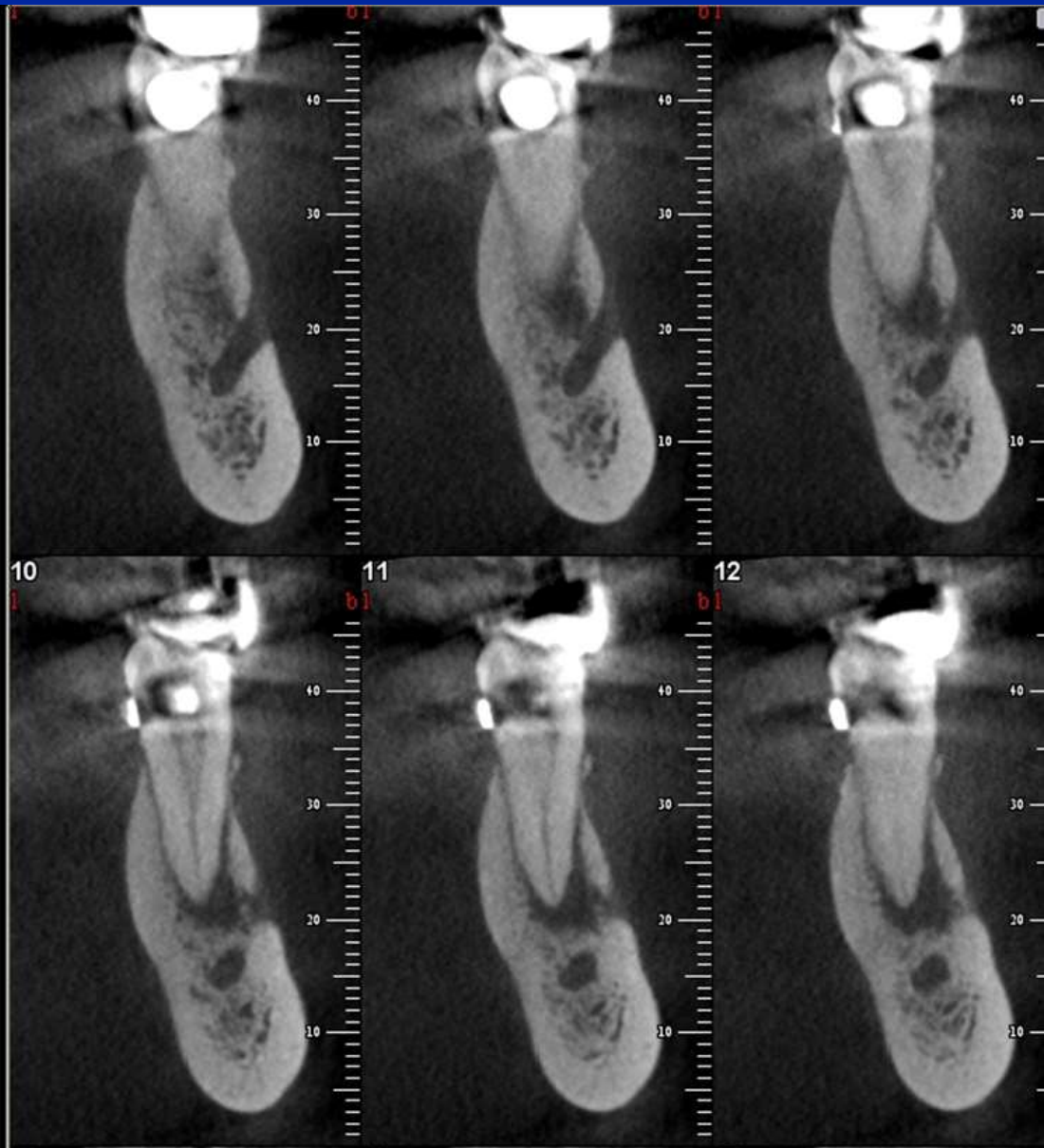
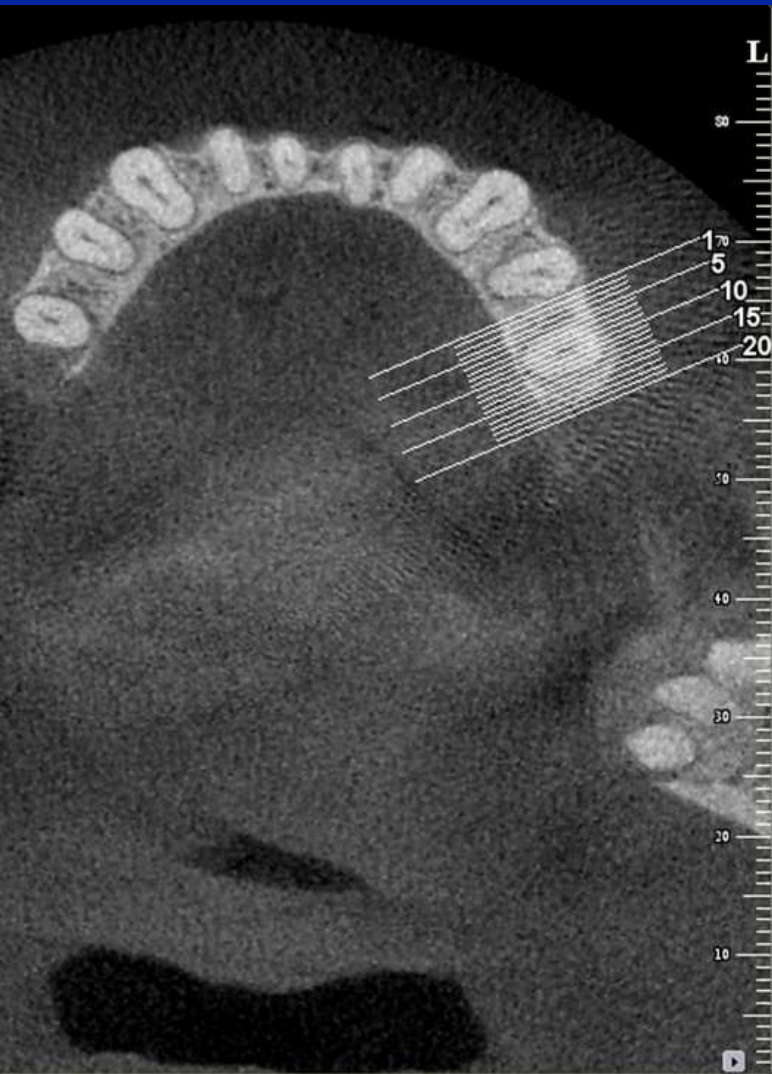
www.conebeamparis.com

CONE BEAM EN ENDODONTIE ET PARODONTIE



**GRANULOME APICAL DE 27
SINUSITE DENTAIRE (CBS)**

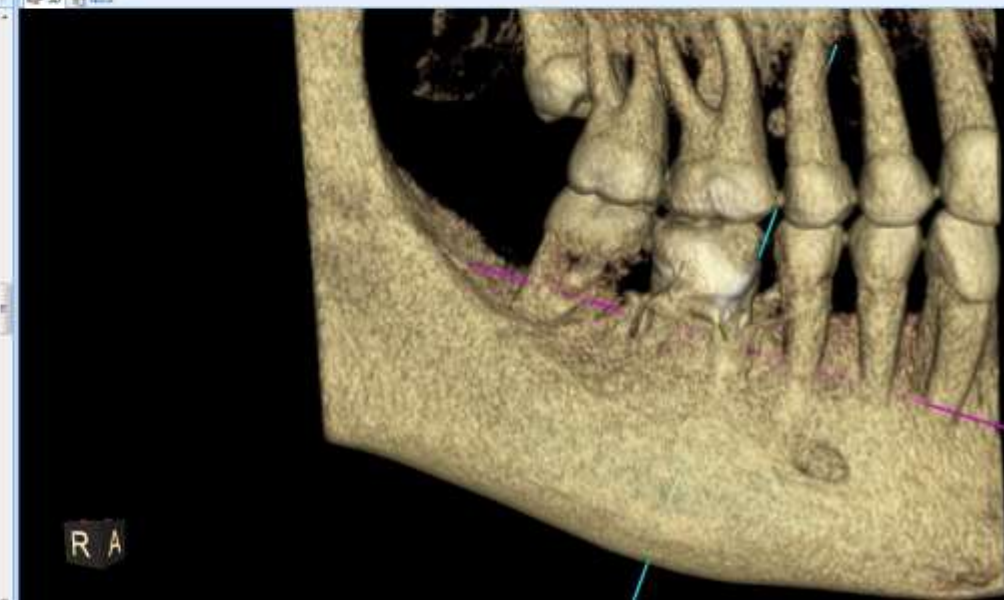
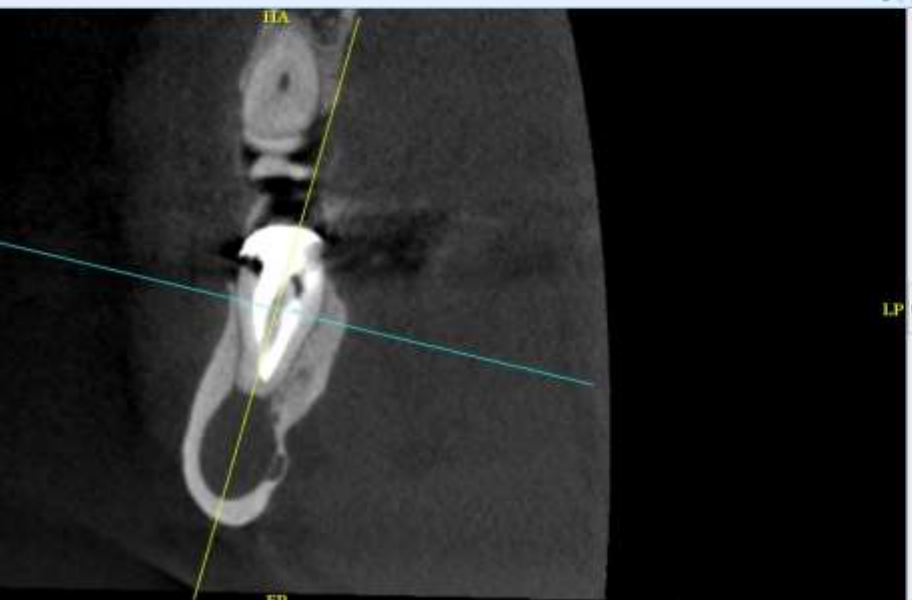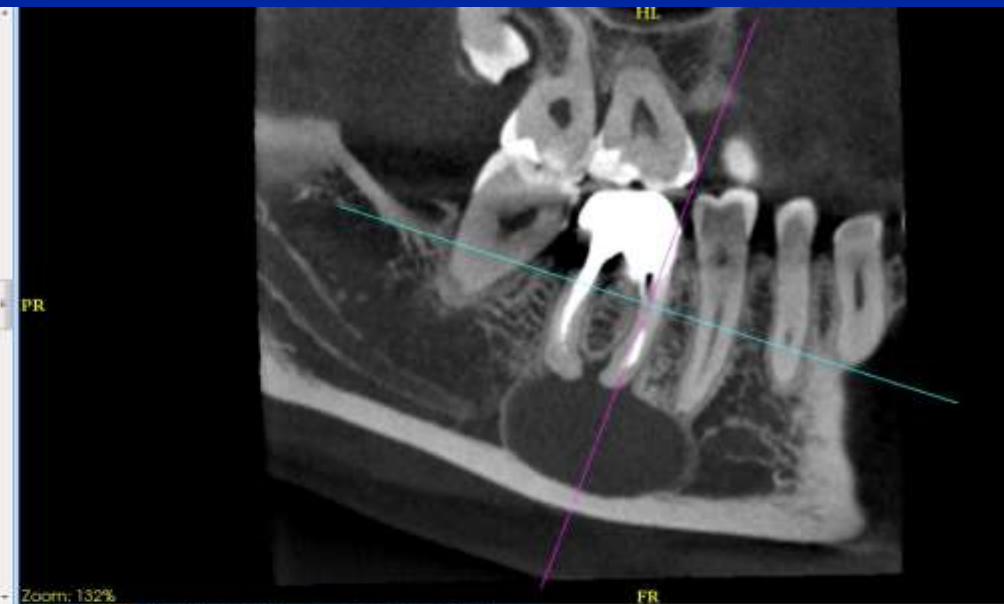
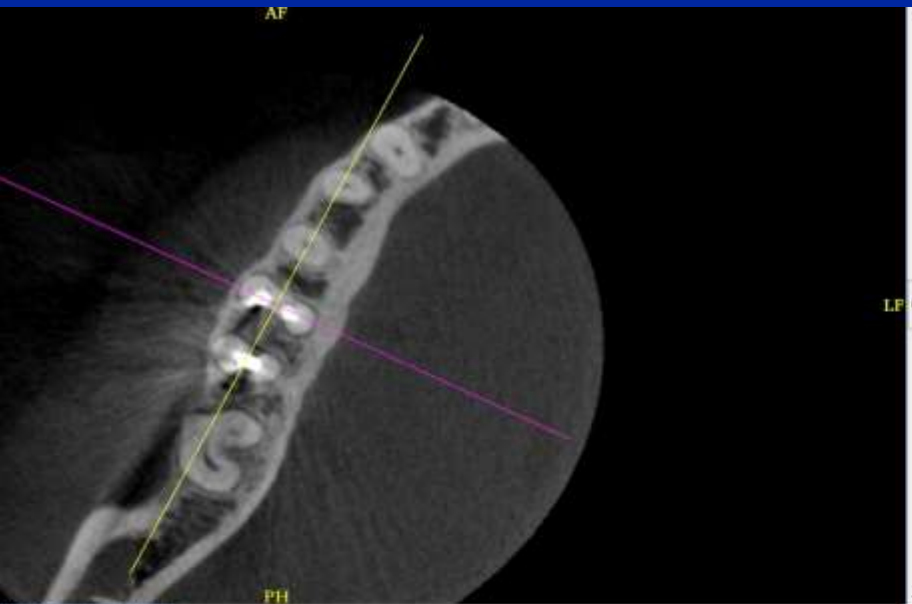
CONE BEAM EN ENDODONTIE ET PARODONTIE



**DOULEURS+++ GRANULOME APICAL DE 35
ENVAHISSANT LE FORAMEN MENTONNIER**

www.conebeamparis.com

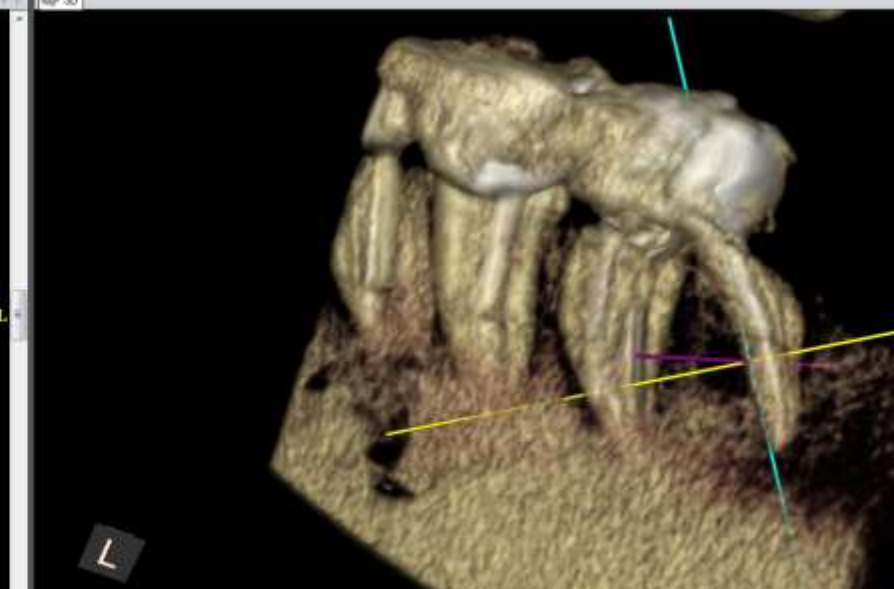
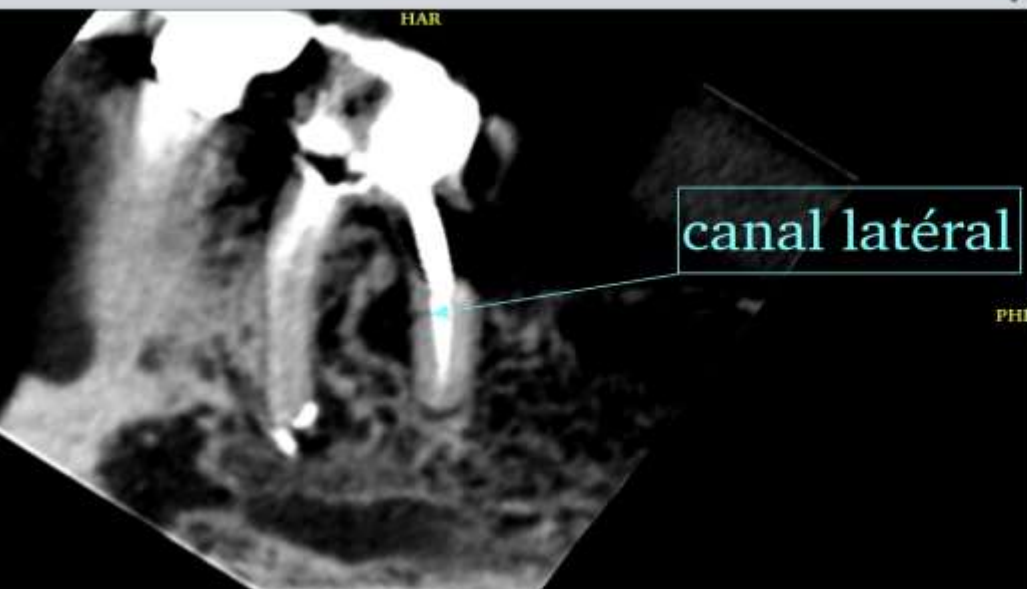
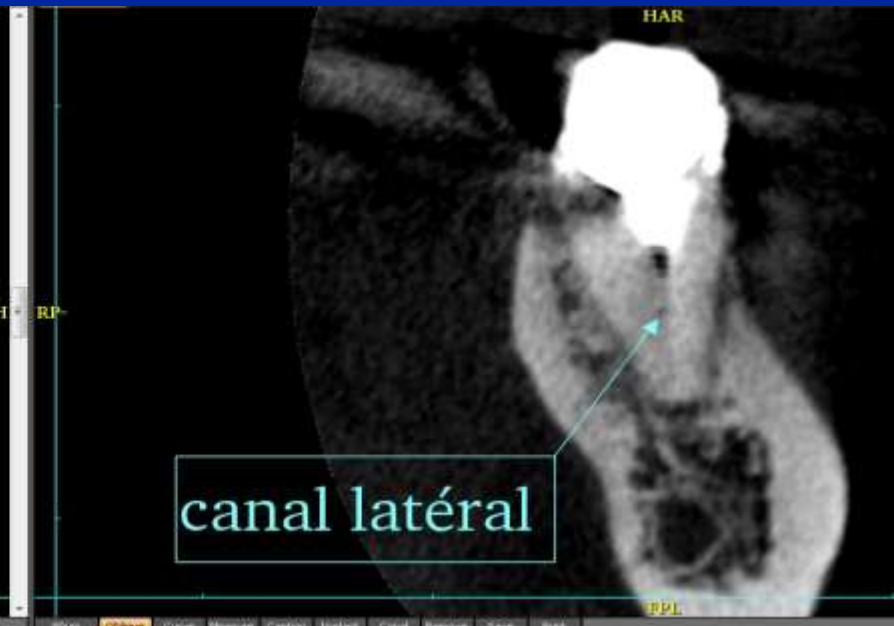
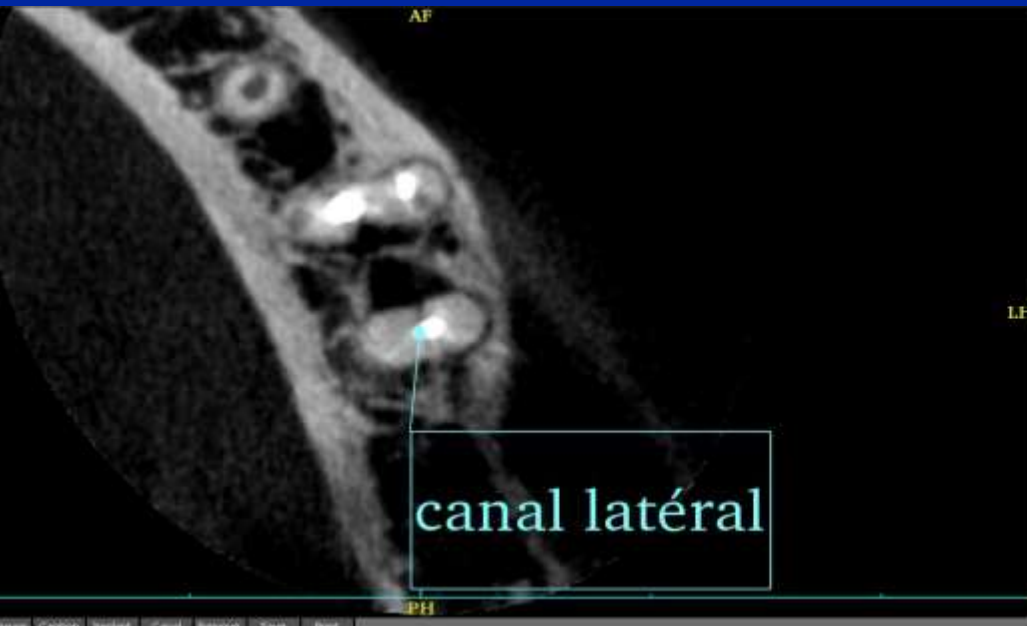CONE BEAM EN ENDODONTIE ET PARODONTIE



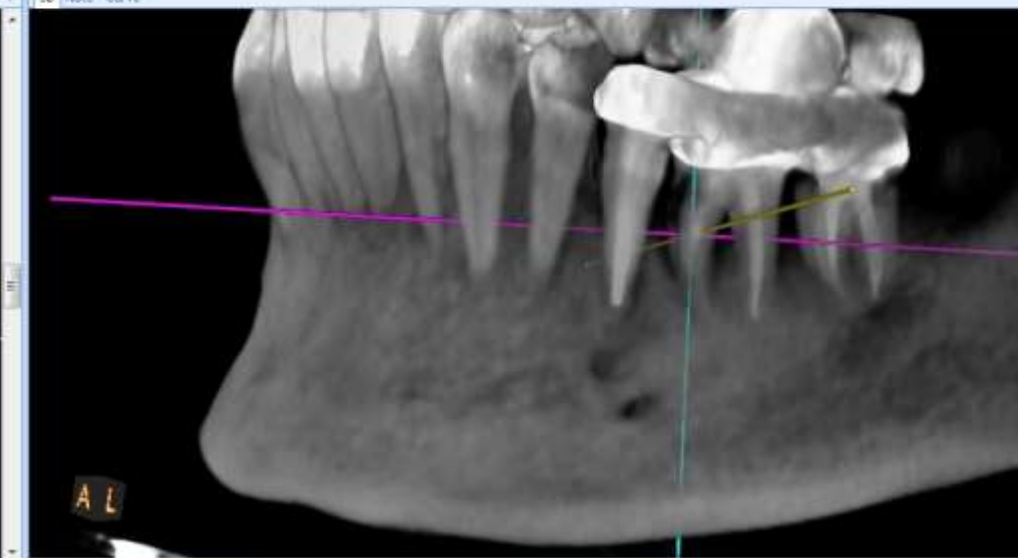
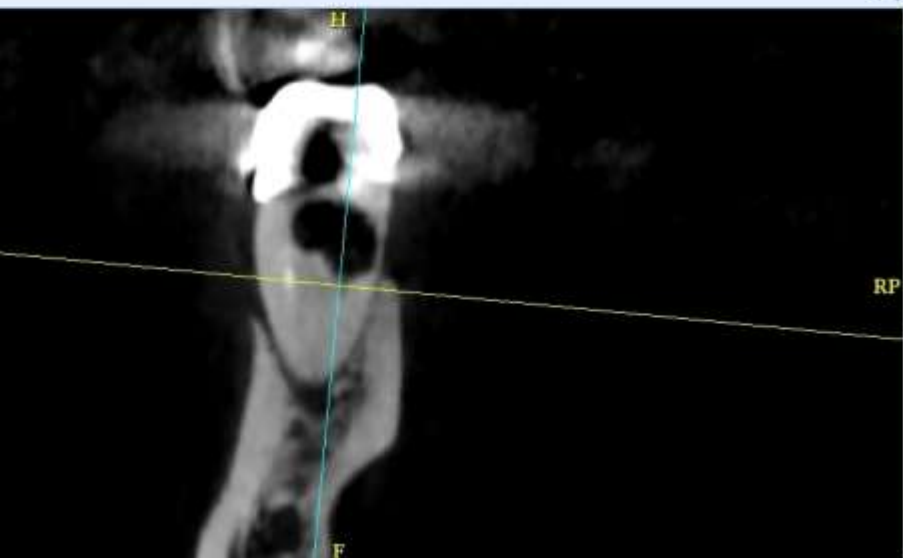
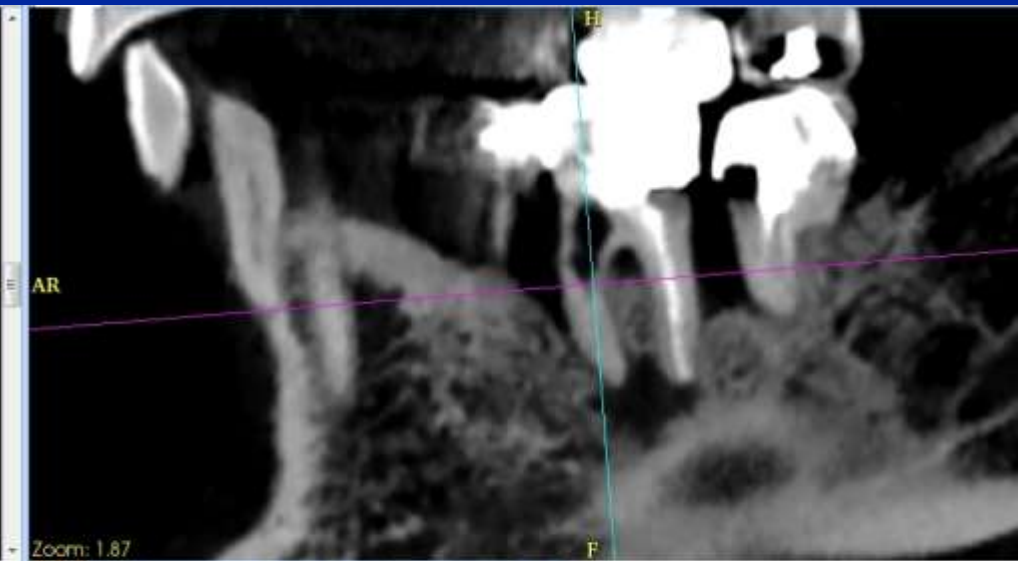
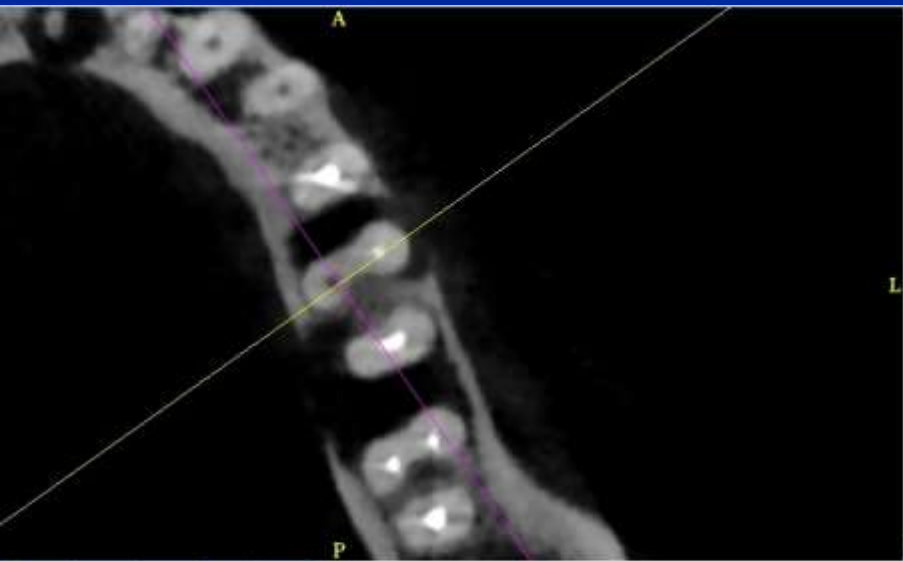
KAD 46 ET CM REFOULE EN LINGUAL

www.conebeamparis.com

CONE BEAM EN ENDODONTIE ET PARODONTIE



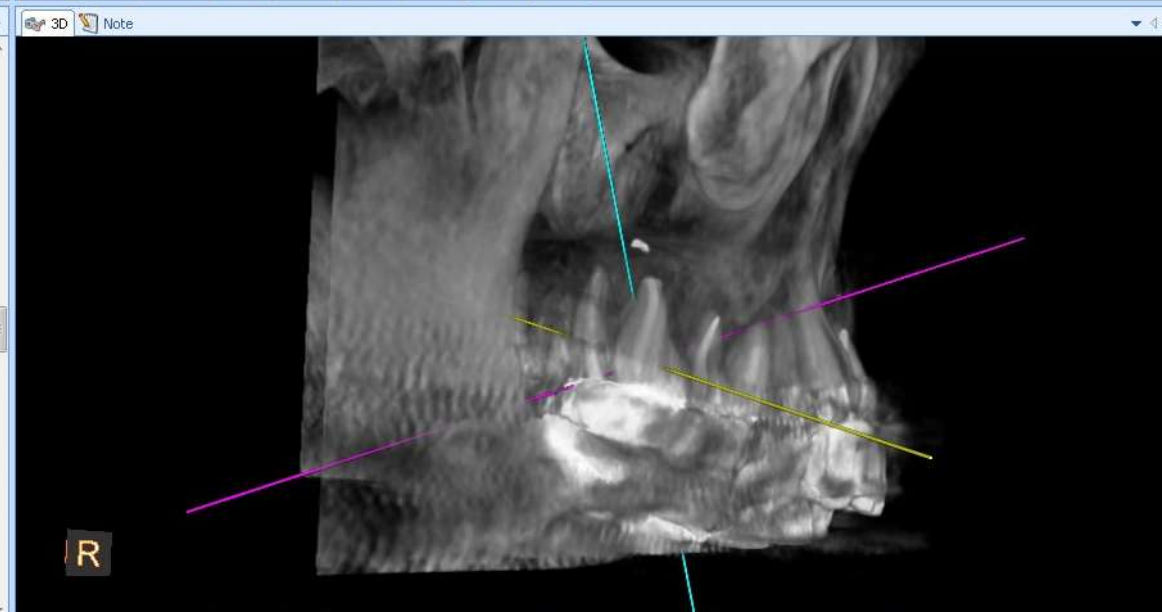
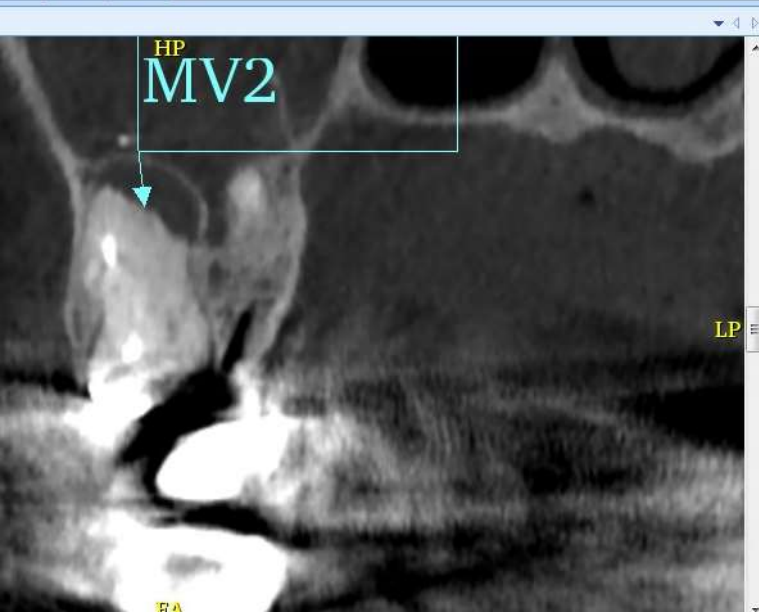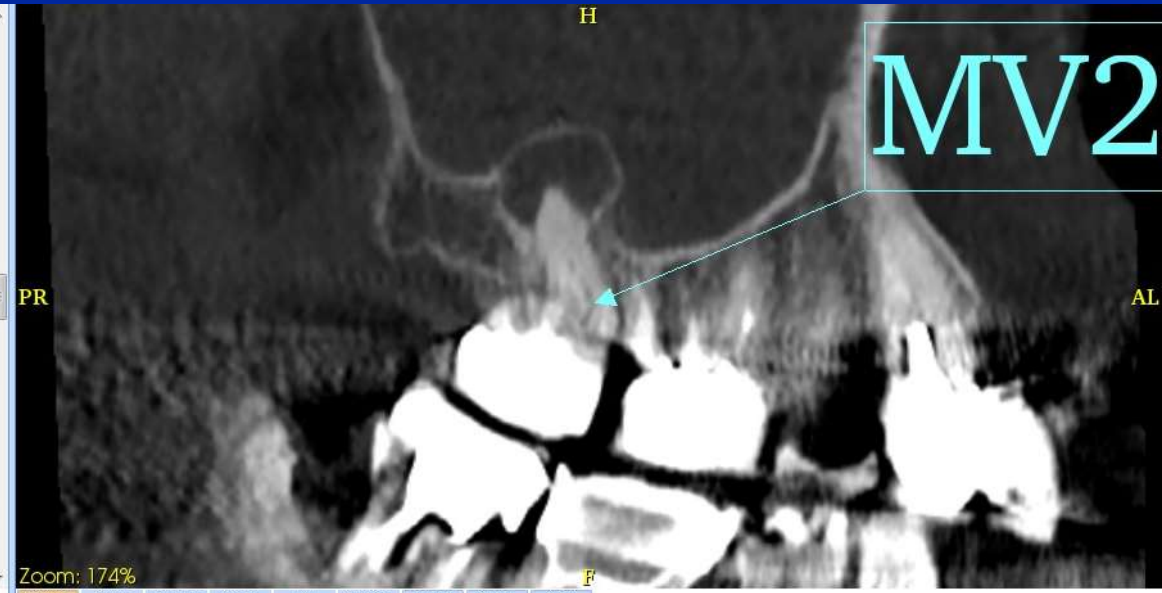
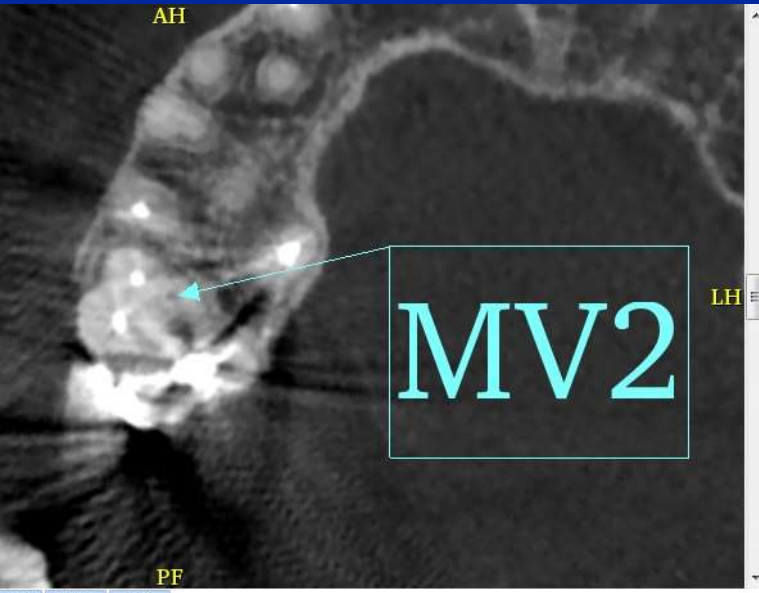
CONE BEAM EN ENDODONTIE ET PARODONTIE



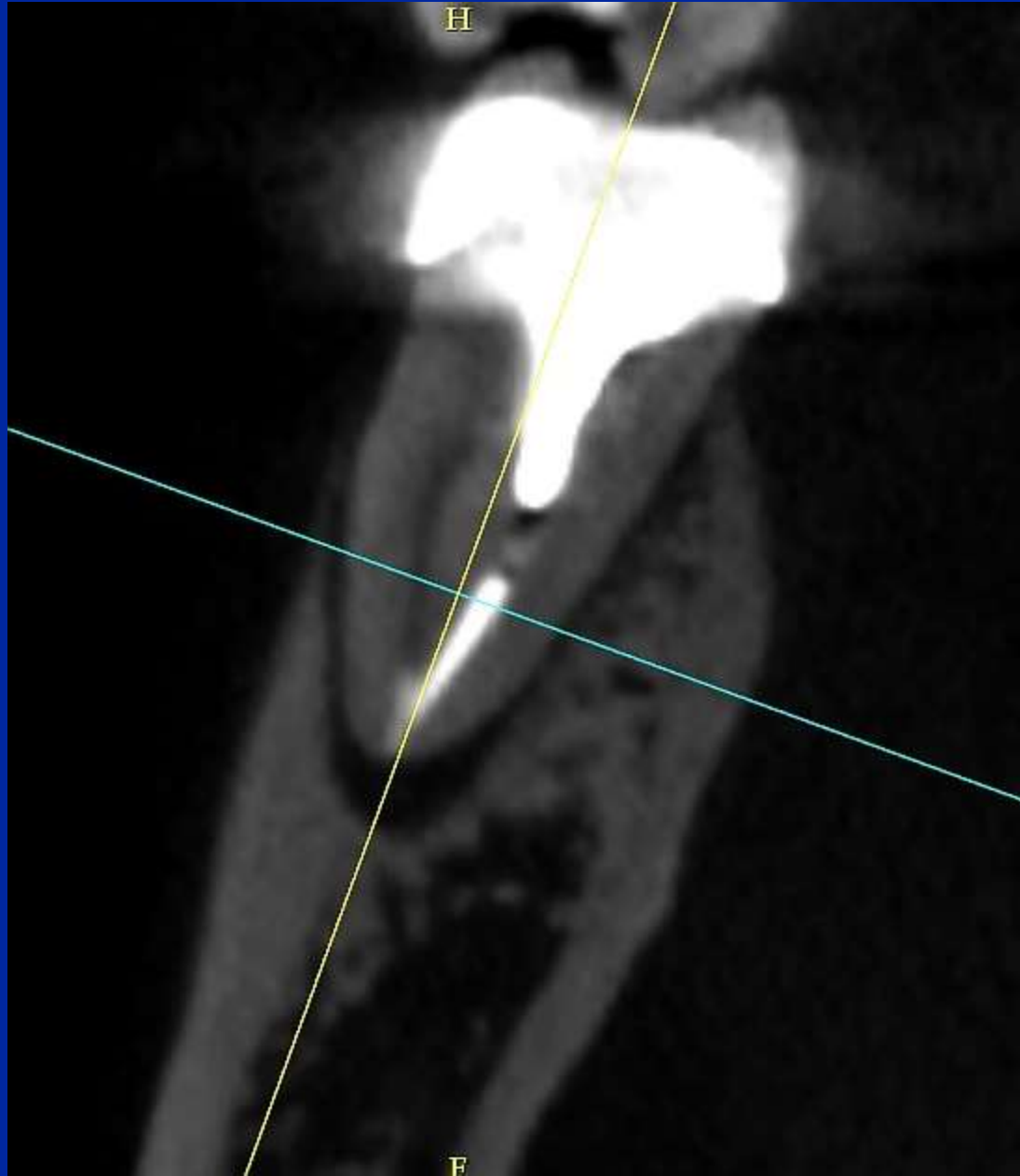
RESORPTON INTERNE

www.conebeamparis.com

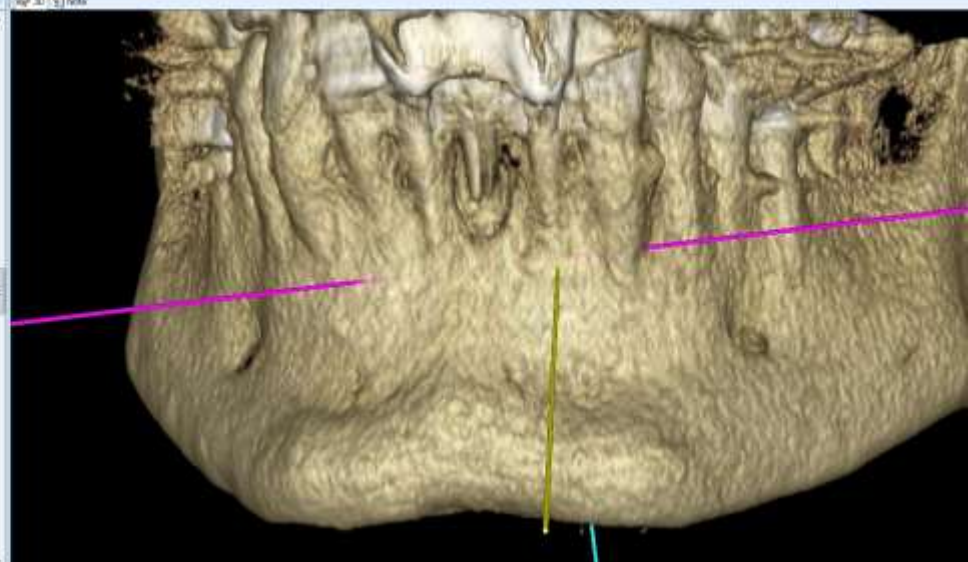
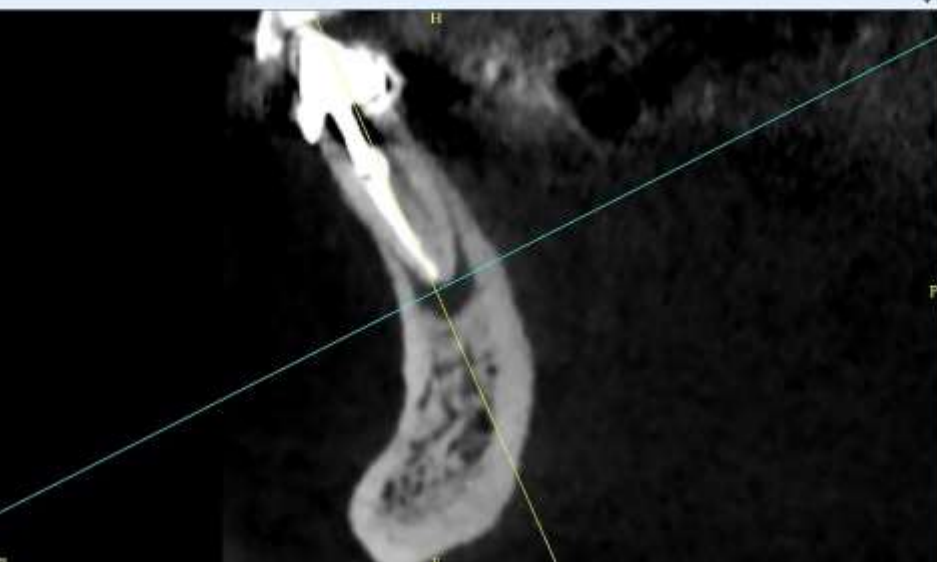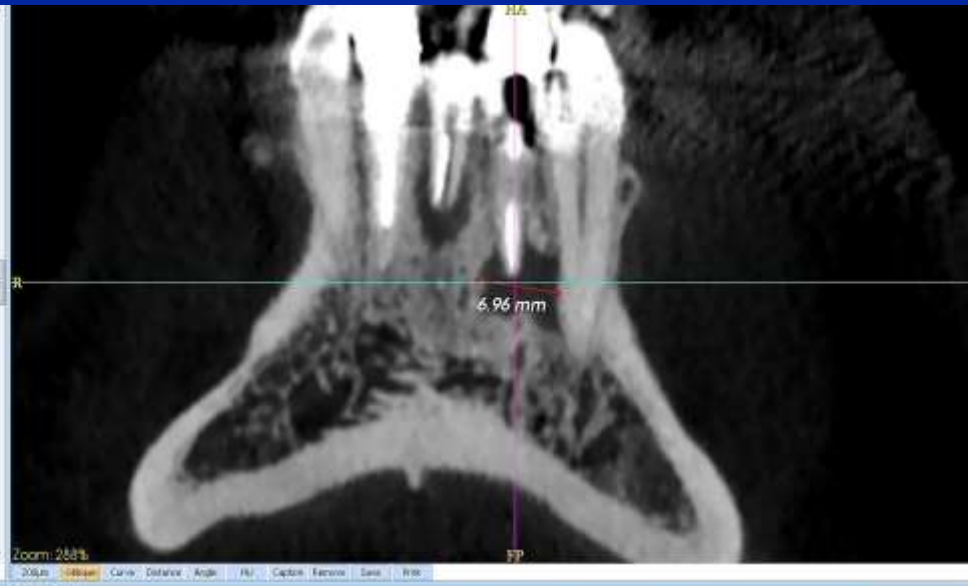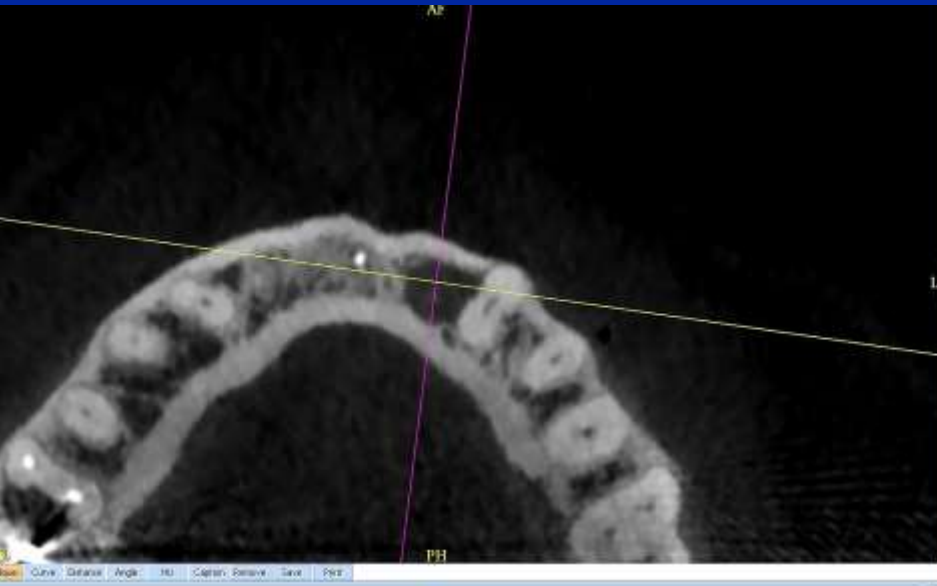
CONE BEAM EN ENDODONTIE ET PARODONTIE



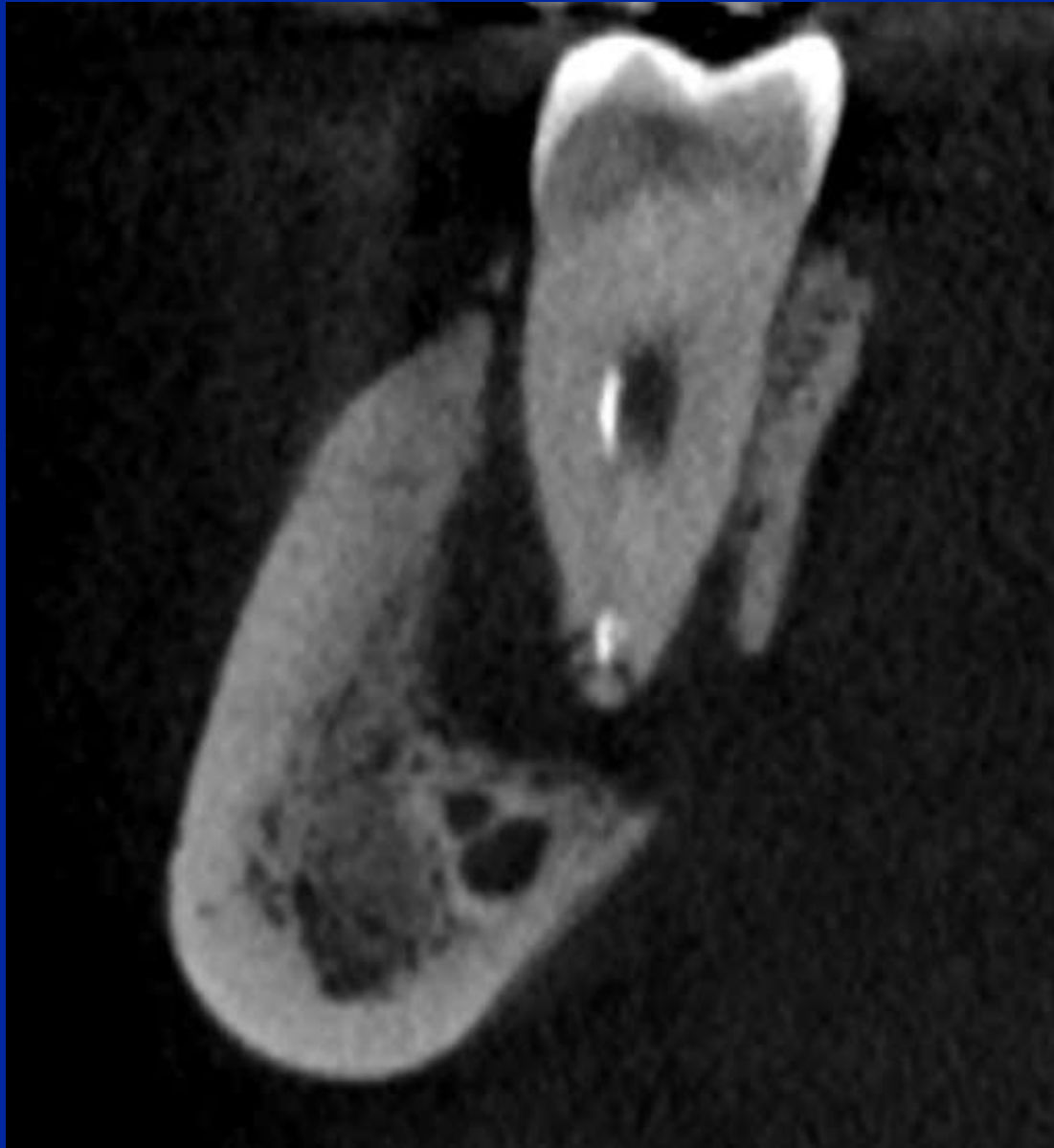
CONE BEAM EN ENDODONTIE ET PARODONTIE



CONE BEAM EN ENDODONTIE ET PARODONTIE



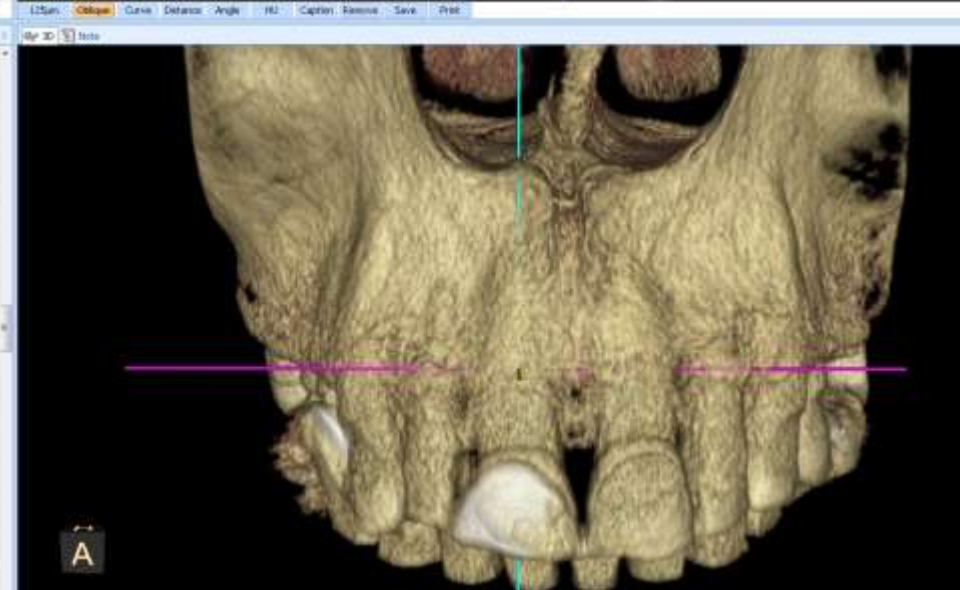
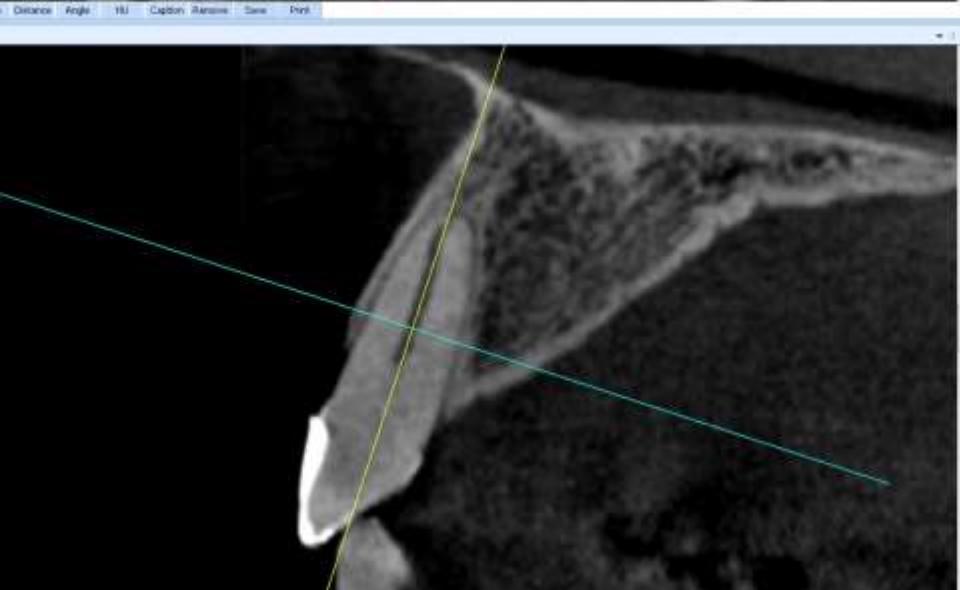
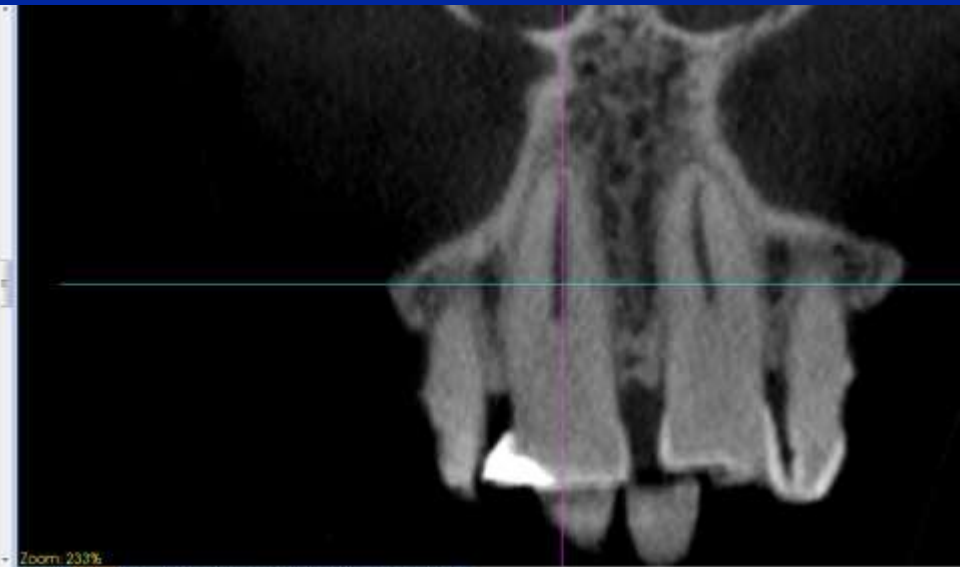
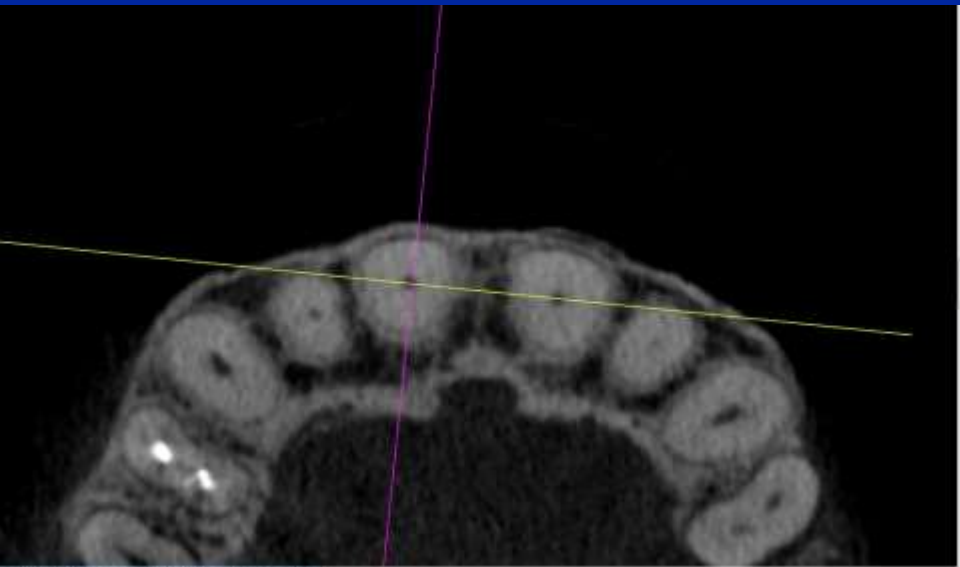
CONE BEAM EN ENDODONTIE ET PARODONTIE



**CANAL TRIFORAMINAL,
ostéite et canal mandibulaire double**

www.conebeamparis.com

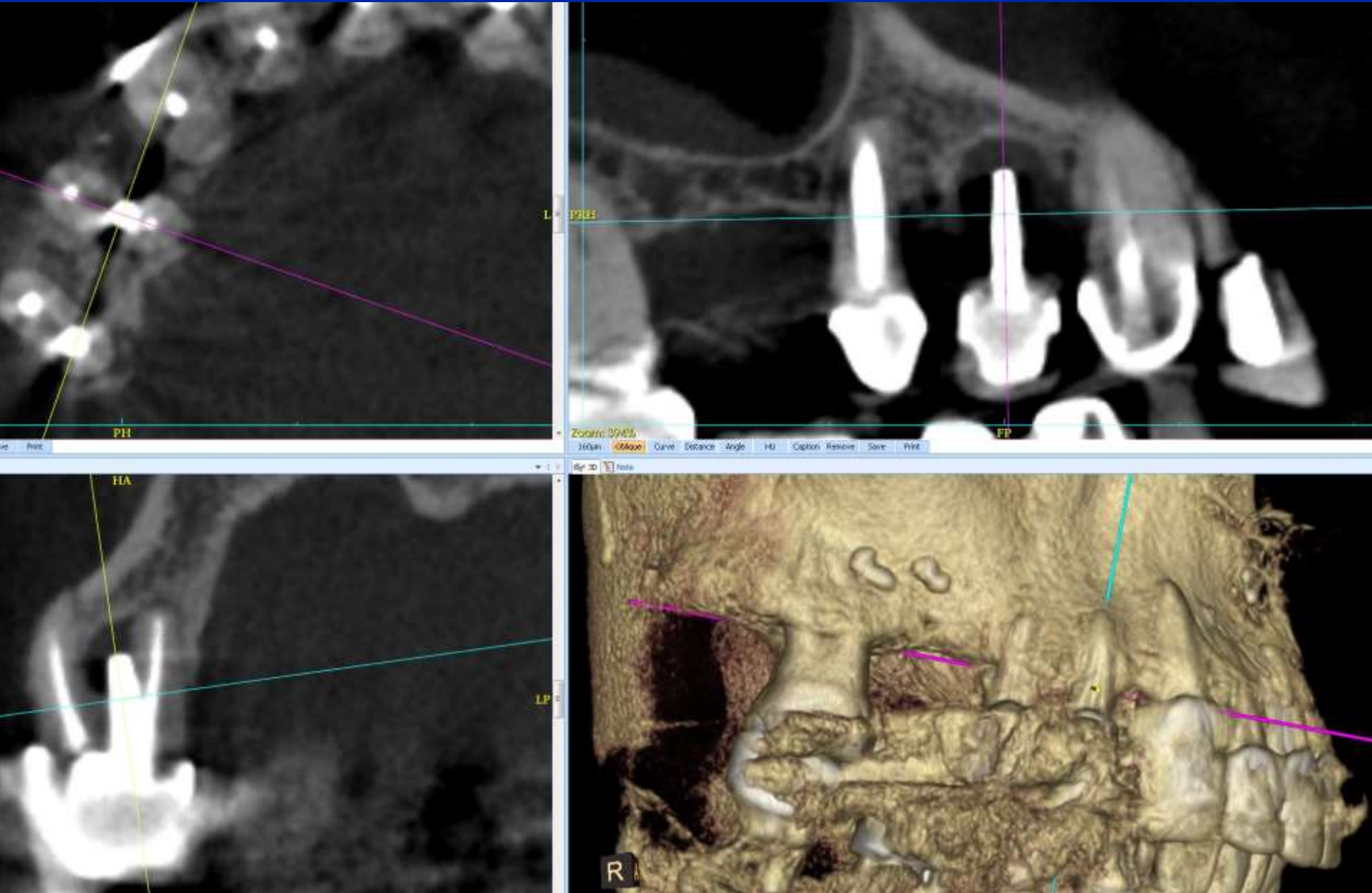
CONE BEAM EN ENDODONTIE ET PARODONTIE



**HYPER-REACTION DENTINAIRE
POST TRAUMATIQUE**

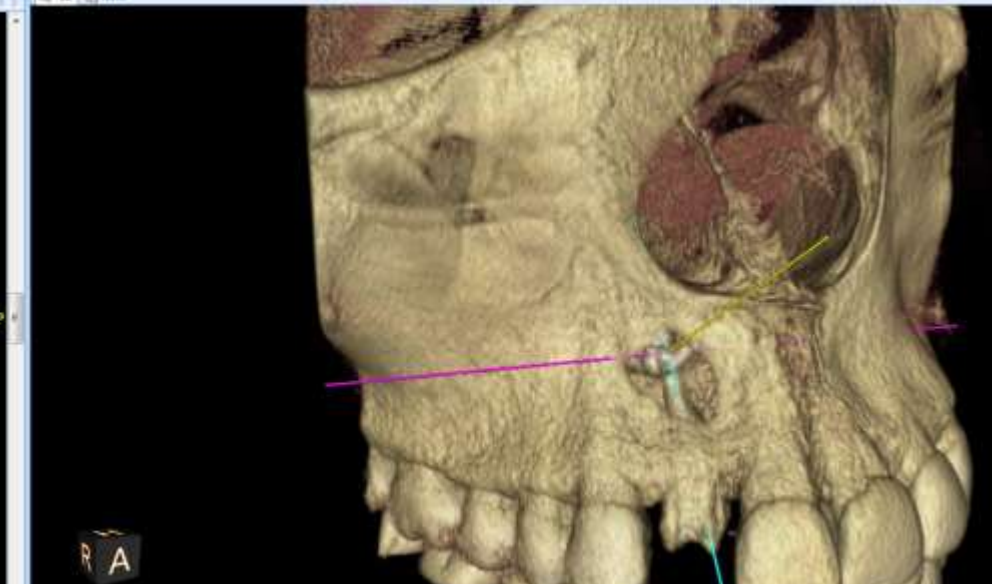
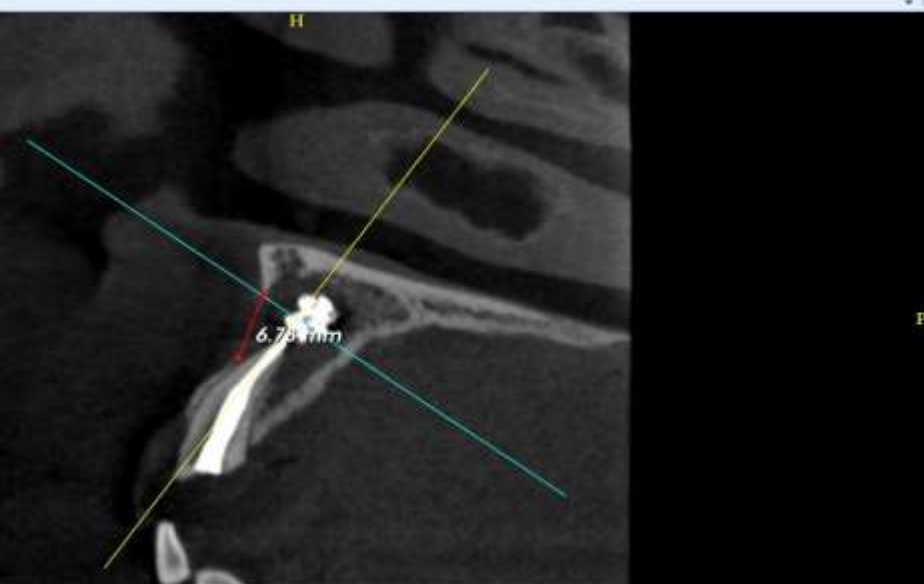
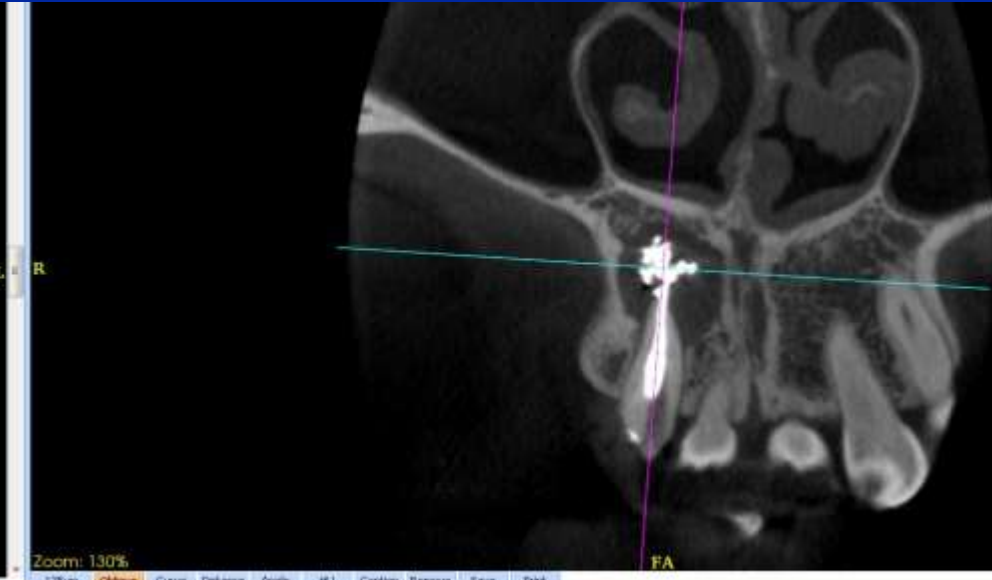
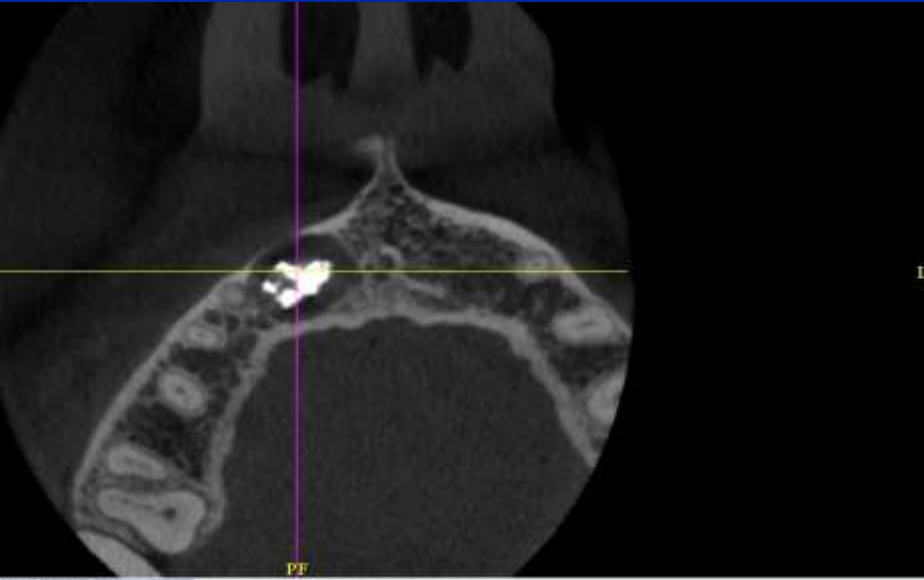
www.conebeamparis.com

CONE BEAM EN ENDODONTIE ET PARODONTIE

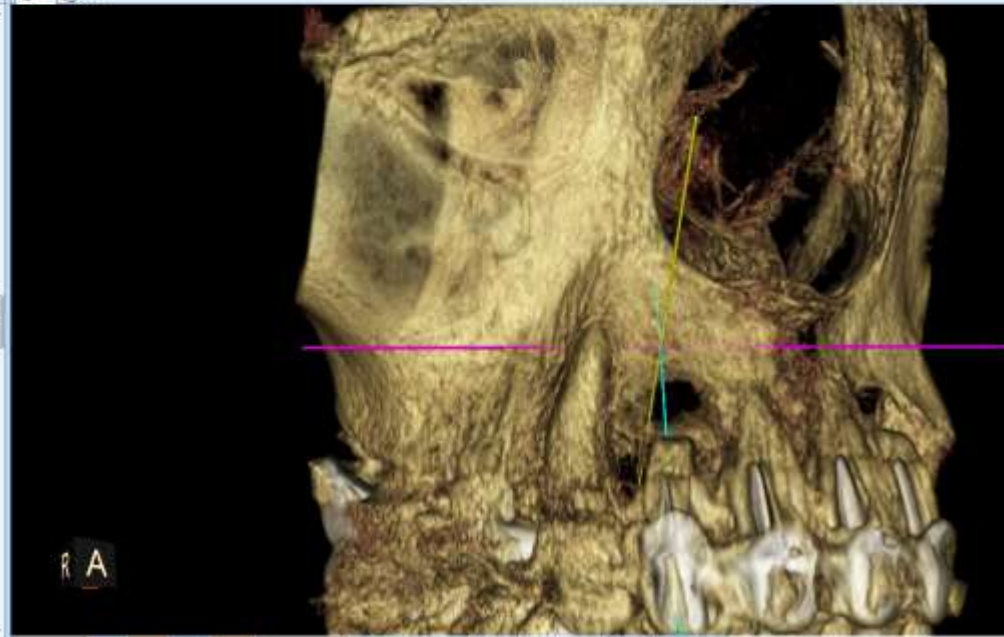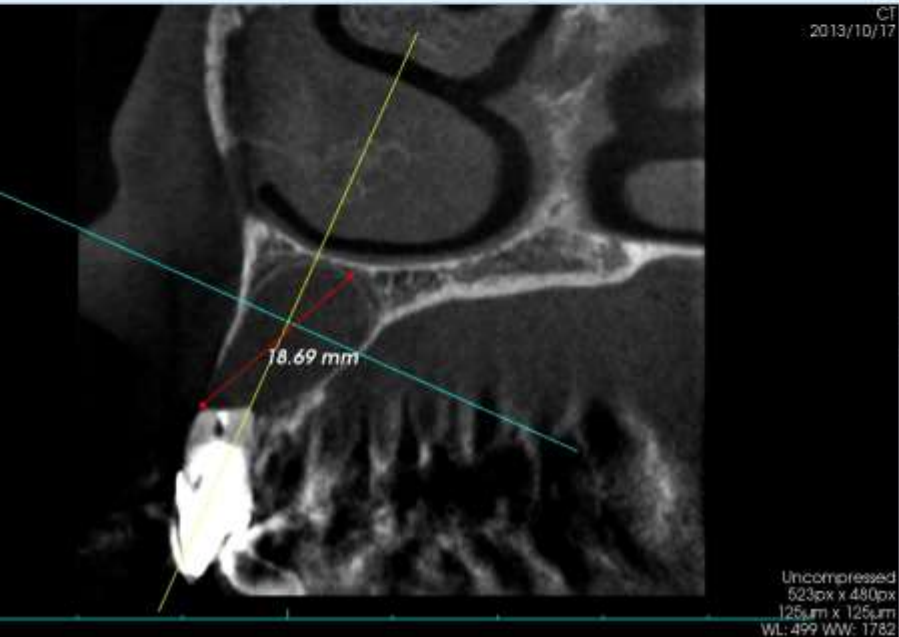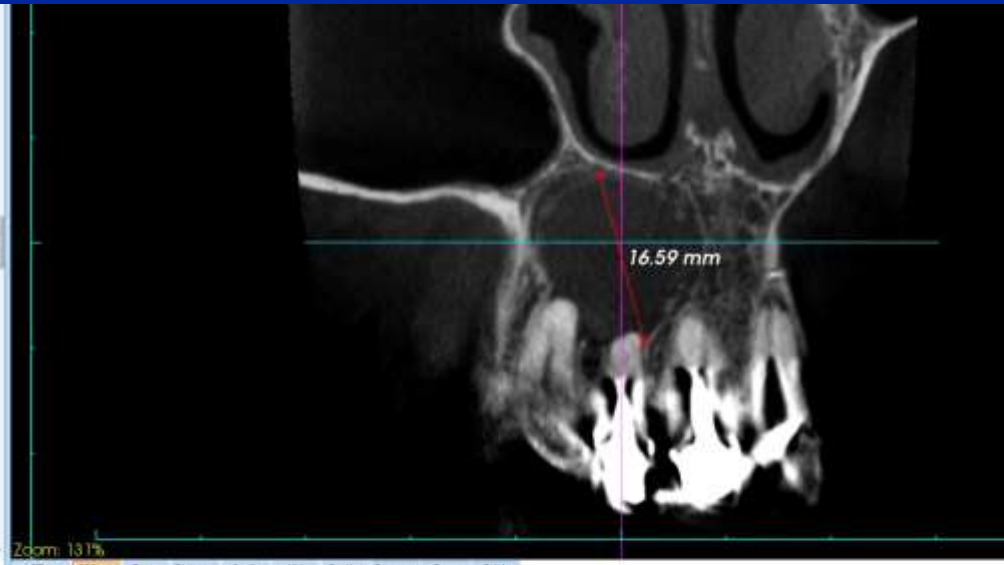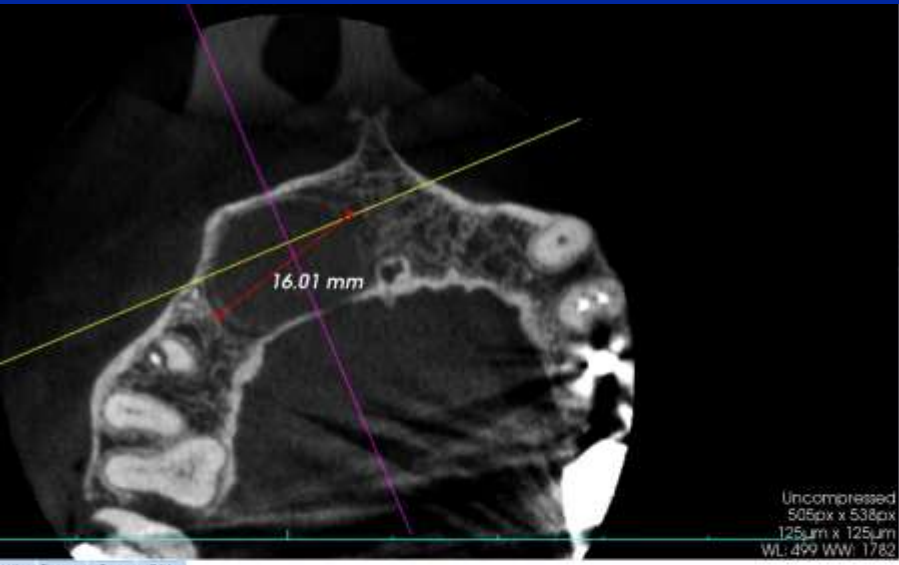


GRANULOME LATERAL IATROGENE (TENON) www.conebeamparis.com

CONE BEAM EN ENDODONTIE ET PARODONTIE



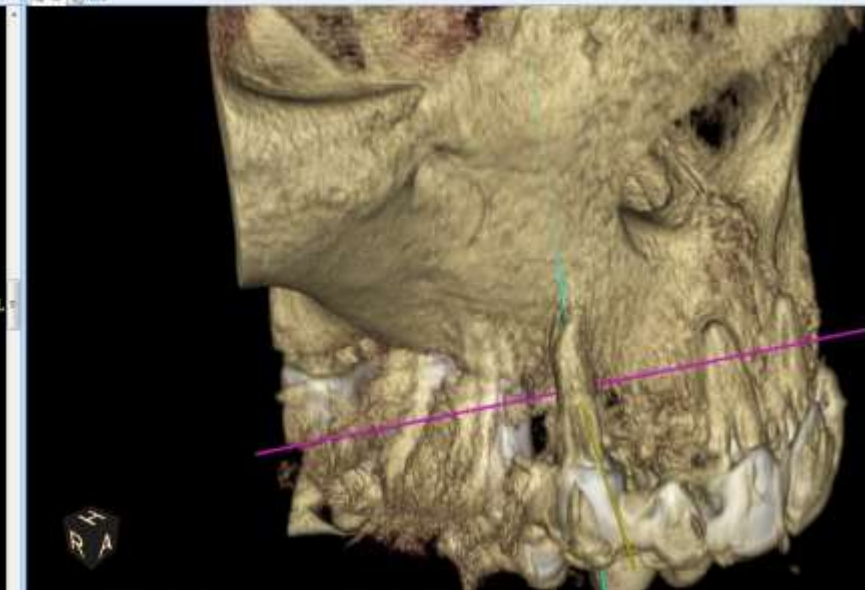
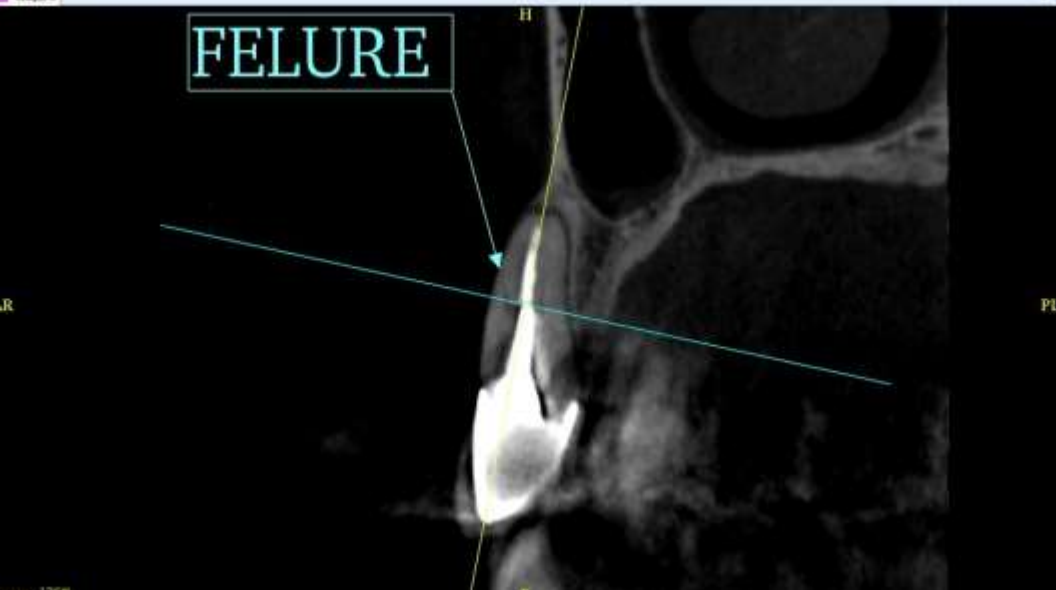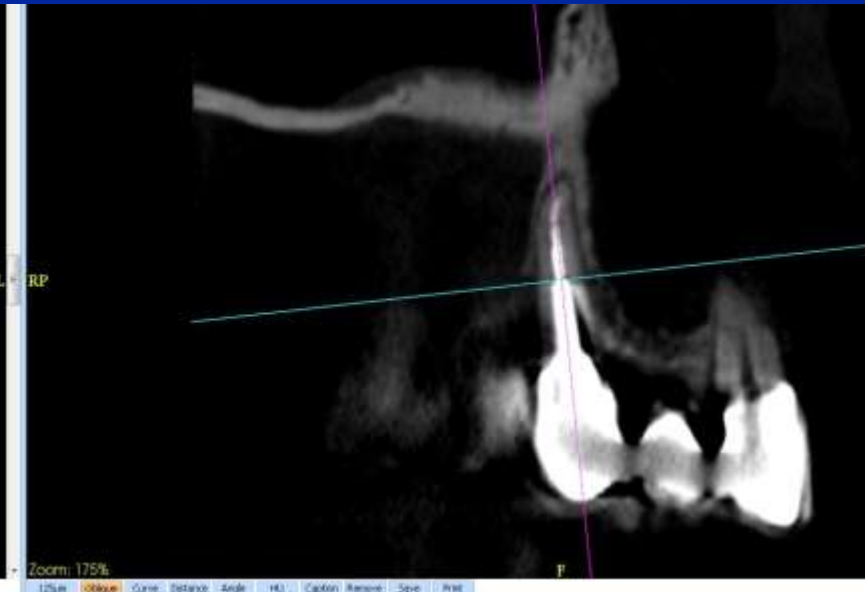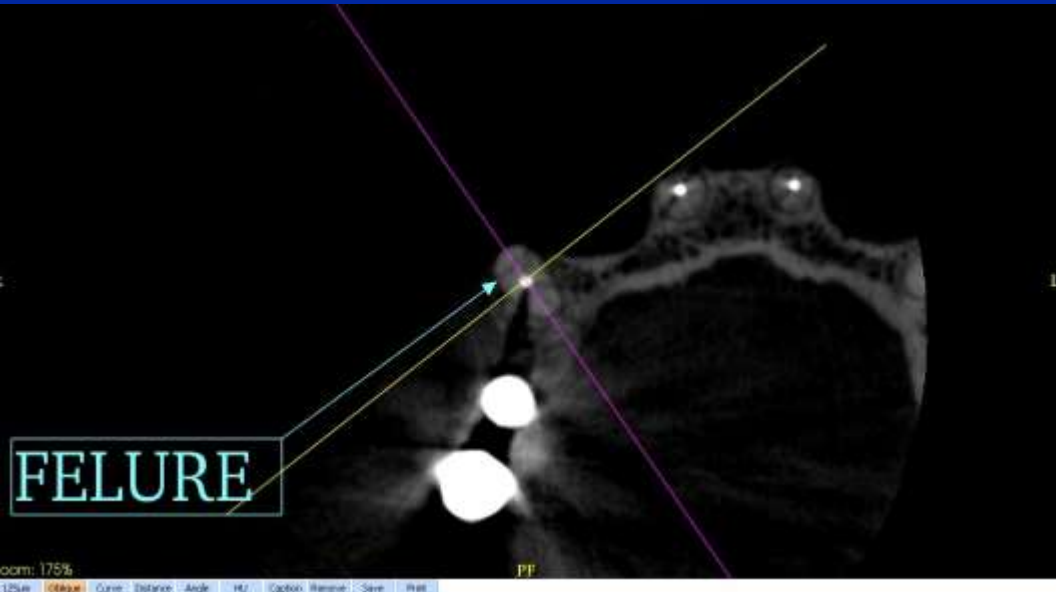
CONE BEAM EN ENDODONTIE ET PARODONTIE



KYSTE SUR RESECTION APICALE

www.conebeamparis.com

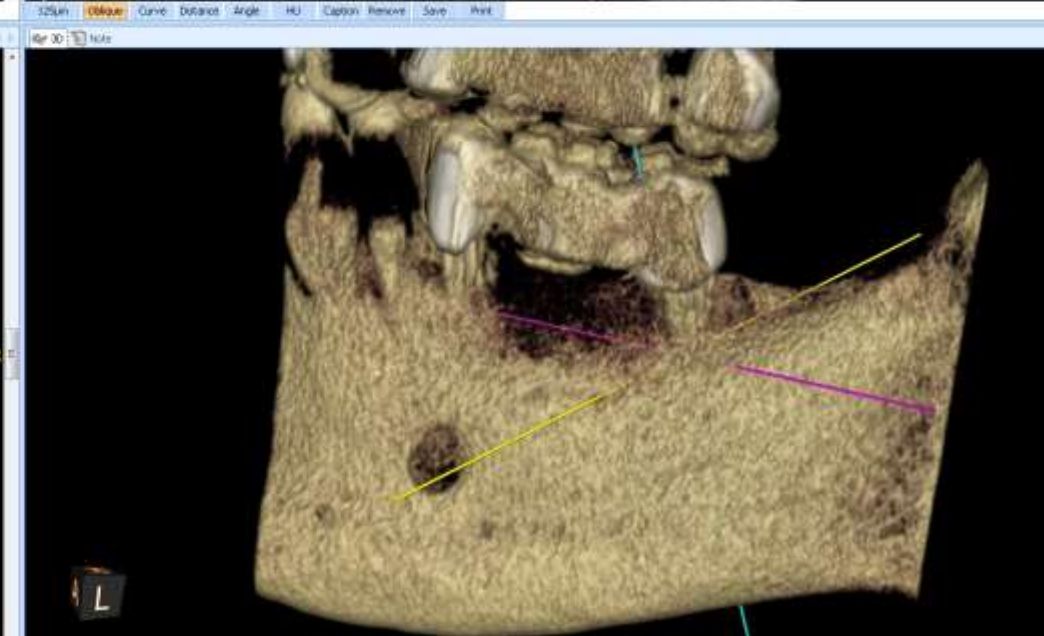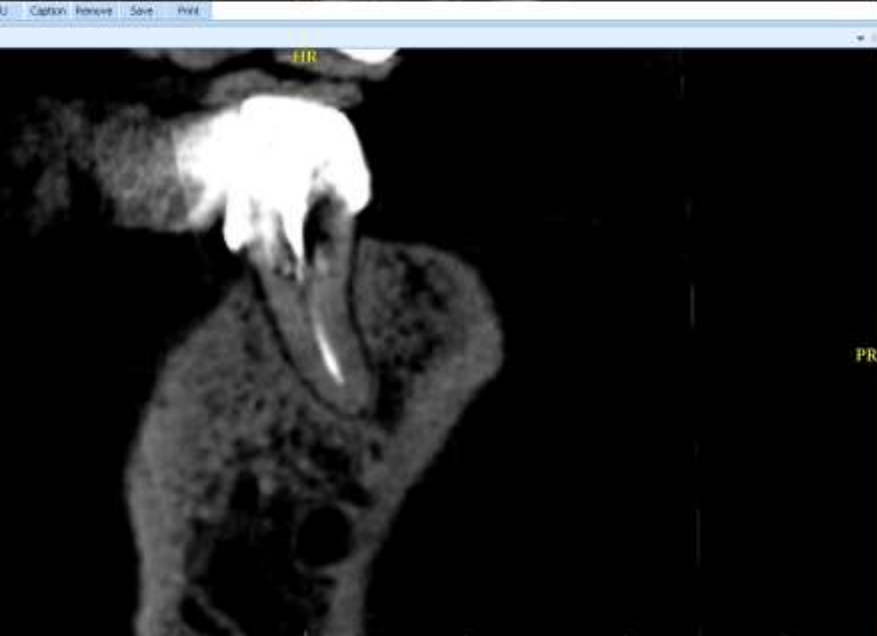
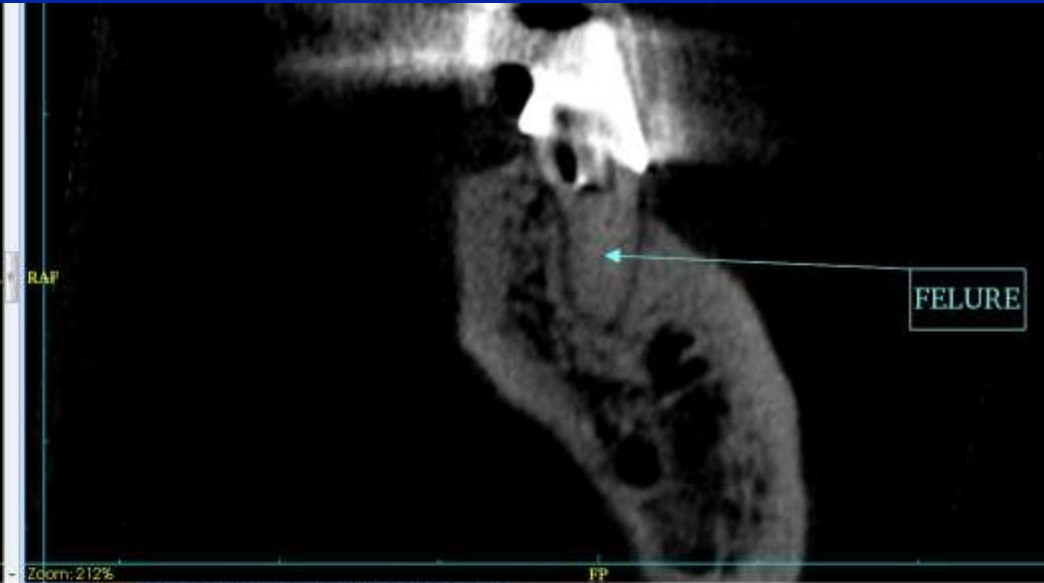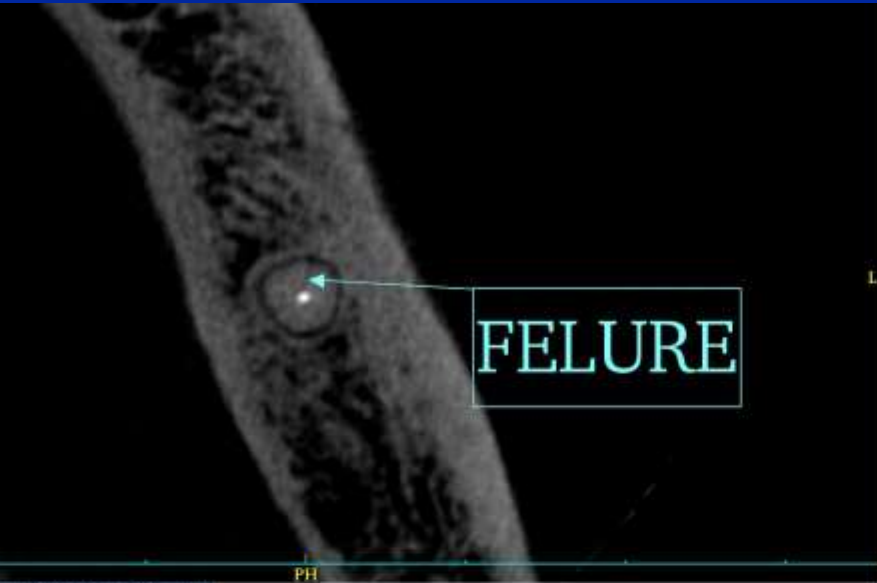CONE BEAM EN ENDODONTIE ET PARODONTIE



FRACTURE OU FELURE VERTICALE RADICULAIRE ?

www.conebeamparis.com

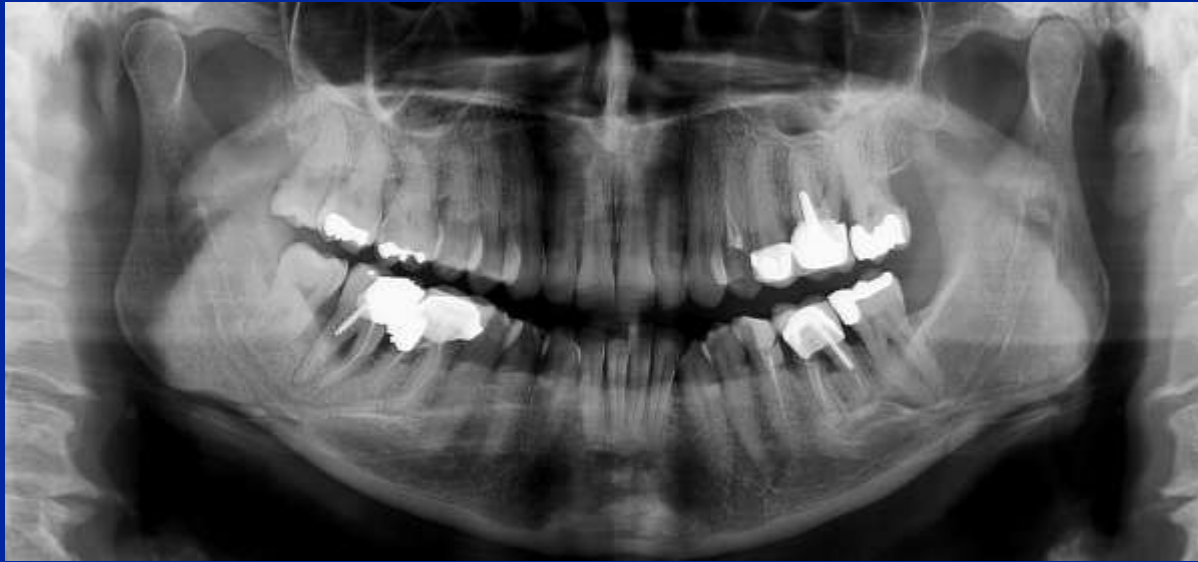CONE BEAM EN ENDODONTIE ET PARODONTIE



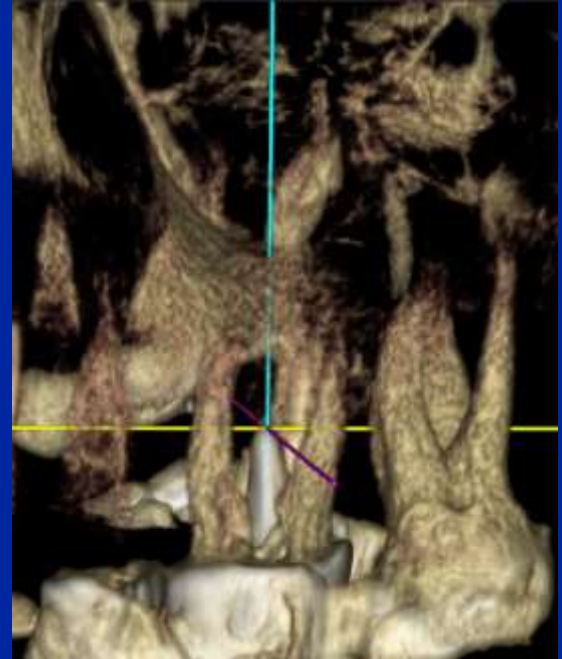
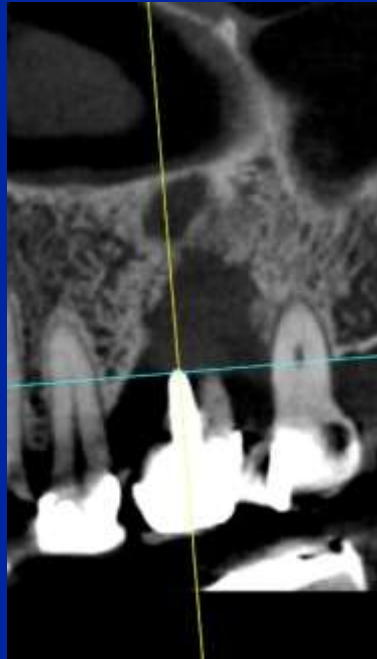
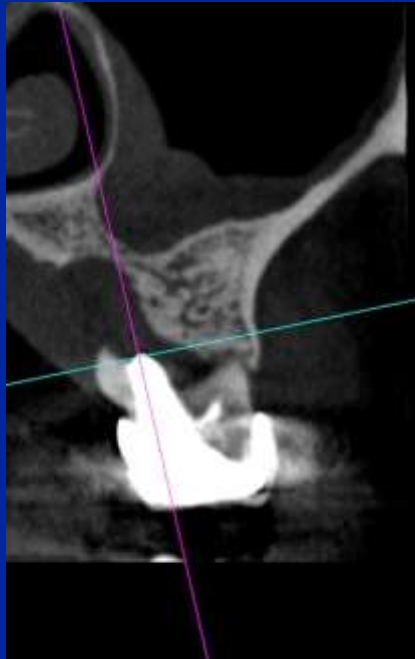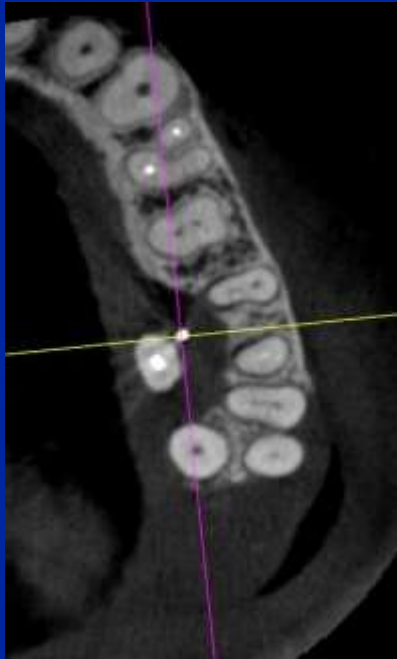
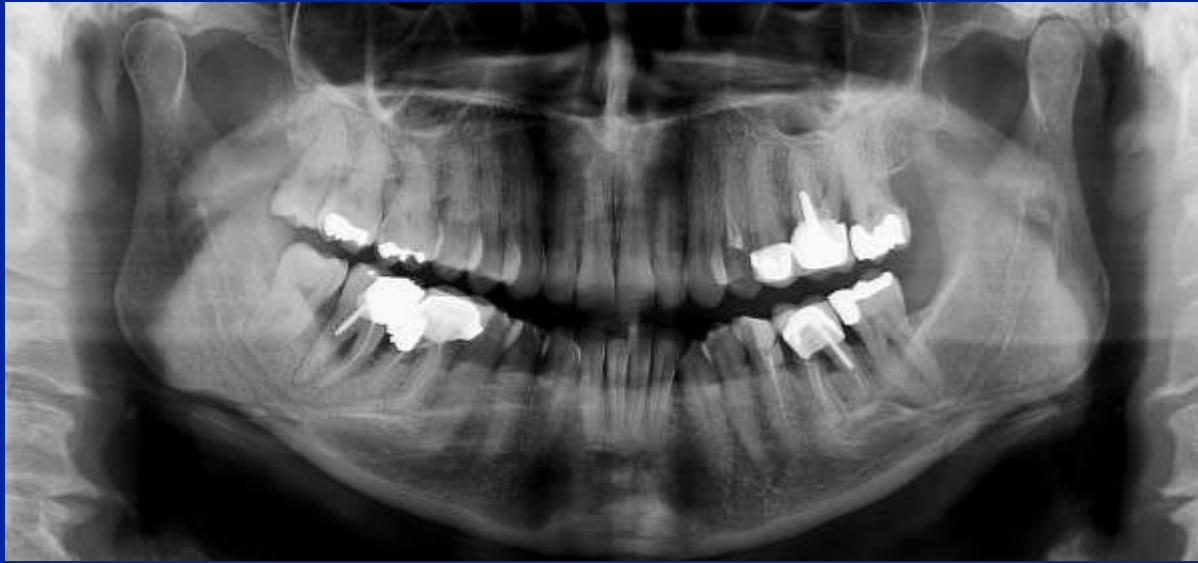FELURE VERTICALE PARTIELLE

www.conebeamparis.com

CONE BEAM EN ENDODONTIE ET PARODONTIE

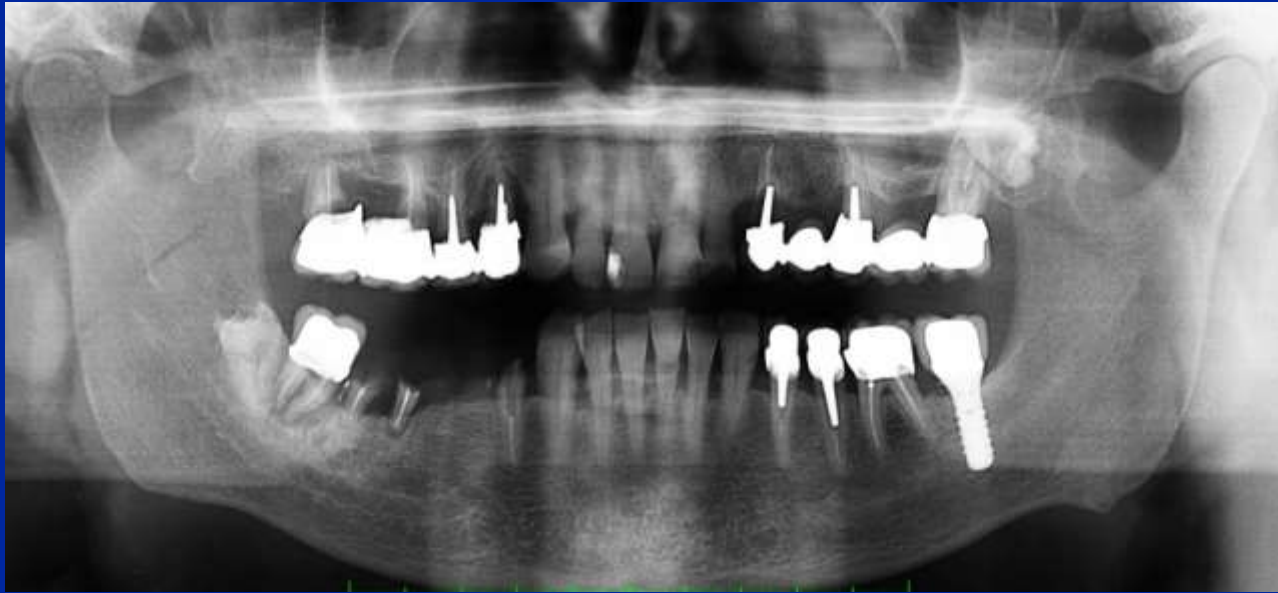


CONE BEAM EN ENDODONTIE ET PARODONTIE

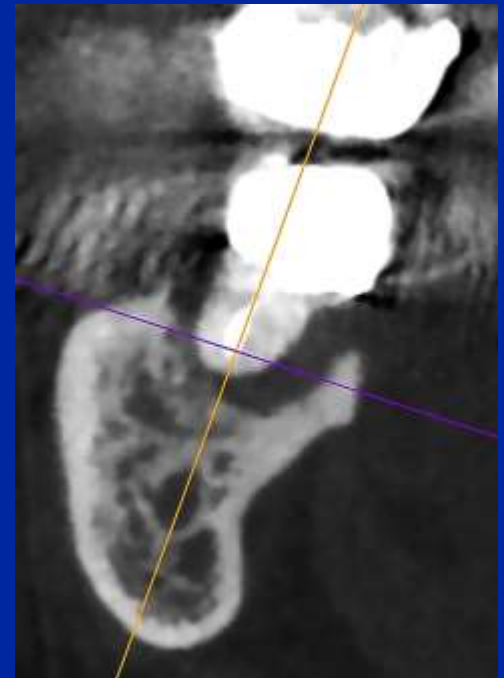
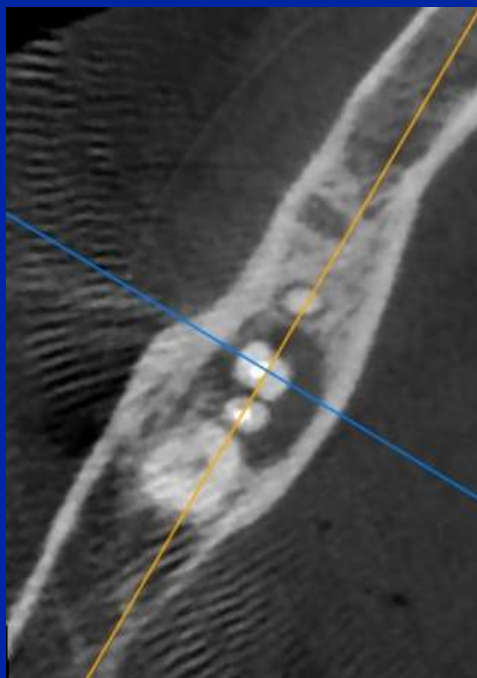
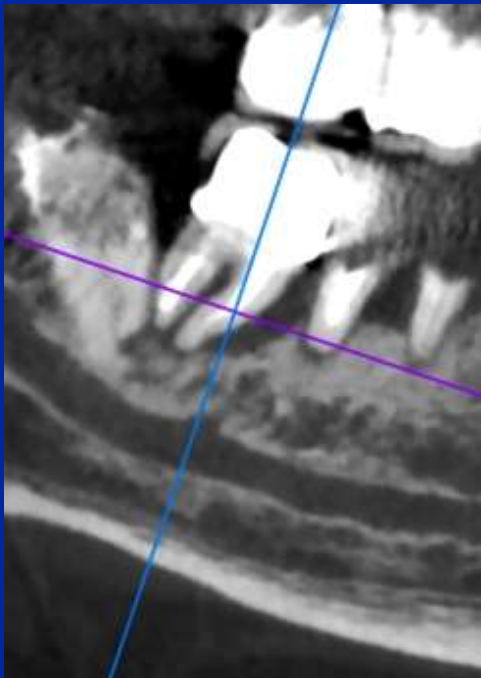
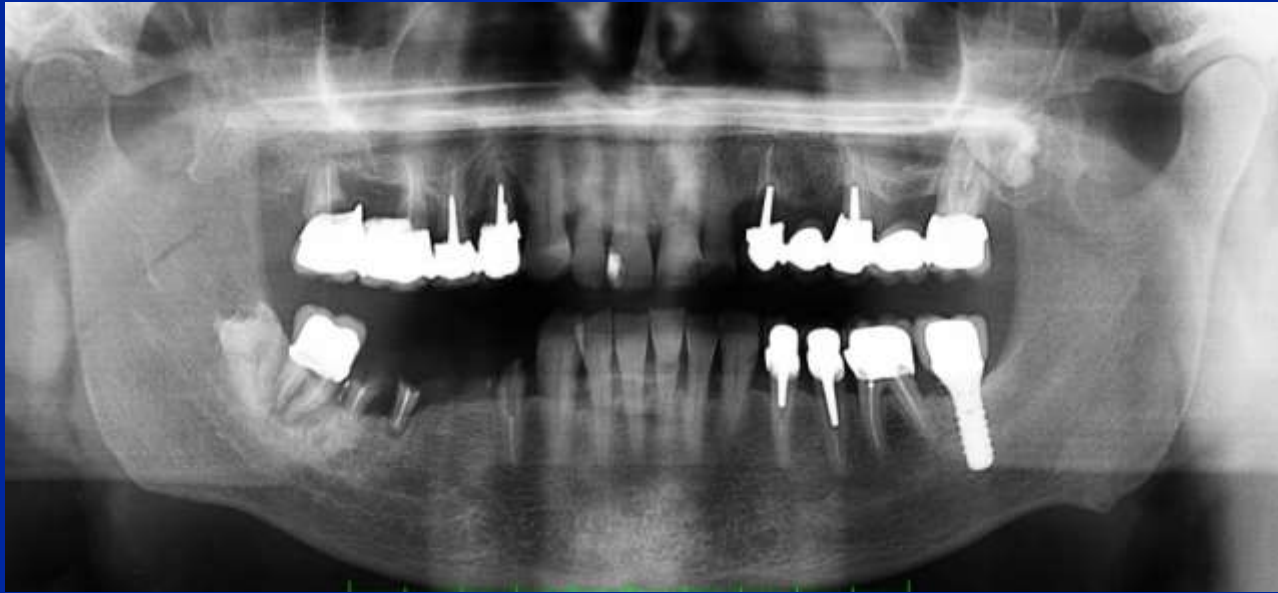


ATTEINTE PARODONTALE
Gêne et tuméfaction palatine en 26

CONE BEAM EN ENDODONTIE ET PARODONTIE




CONE BEAM EN ENDODONTIE ET PARODONTIE



BILAN PARODONTAL, DOULEURS MAND D

www.conebeamparis.com


CONE BEAM DES PARODONTITES ET DES PERI-IMPLANTITES



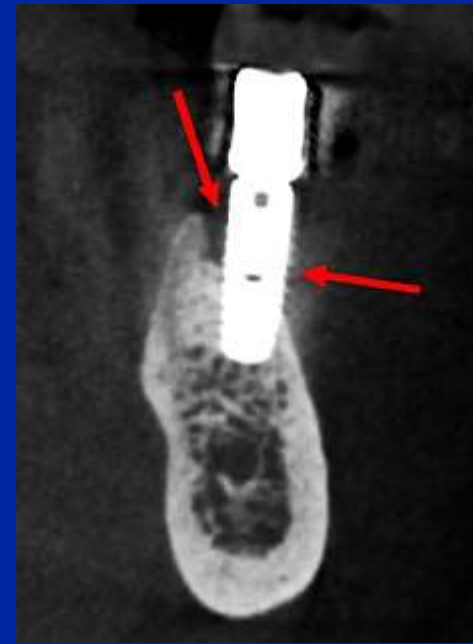
RA

IMPLANT 36 DOULOUREUX

CONE BEAM DES PARODONTITES ET DES PERI-IMPLANTITES



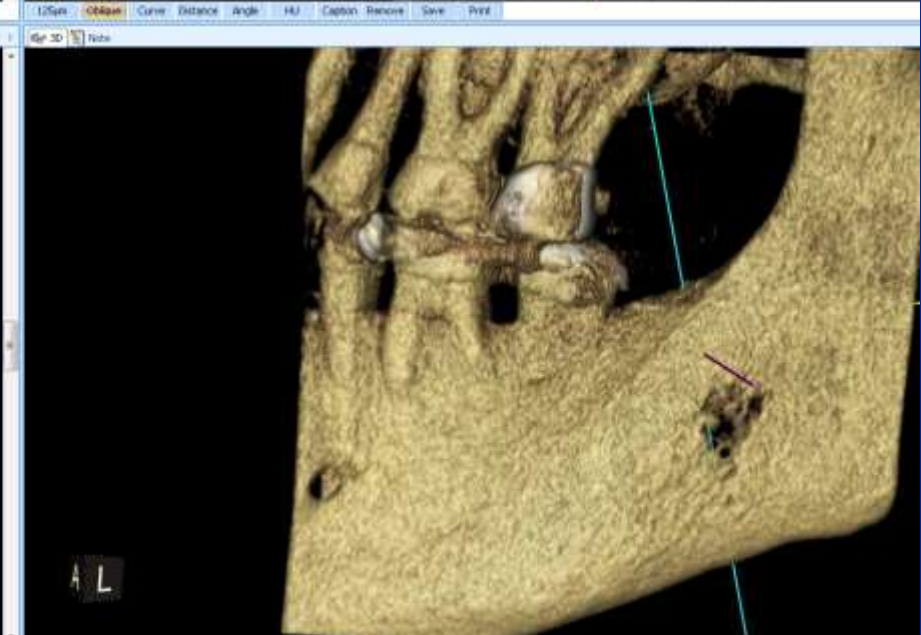
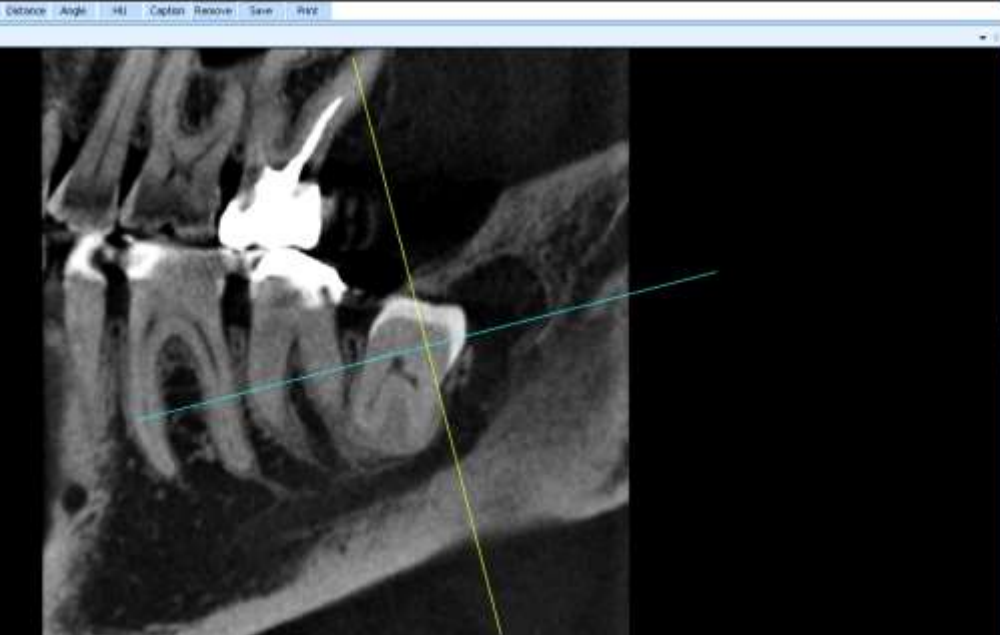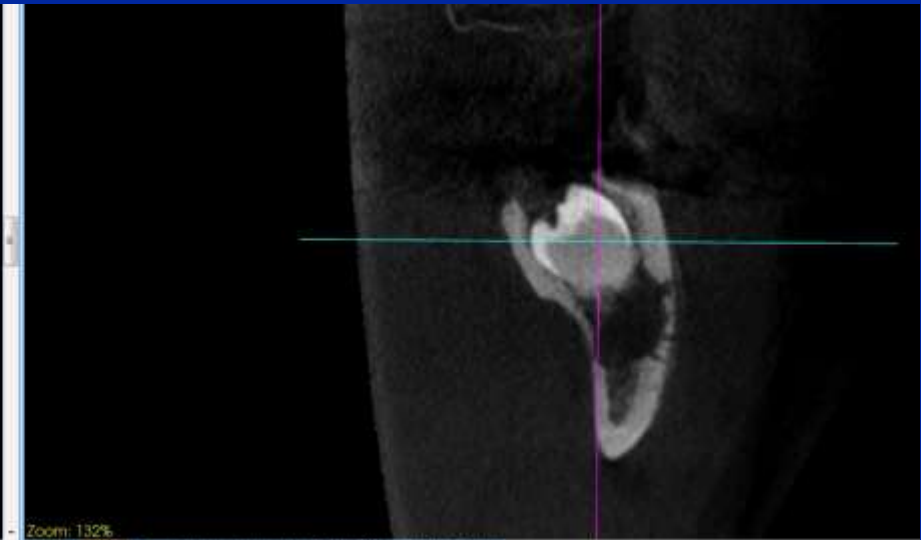
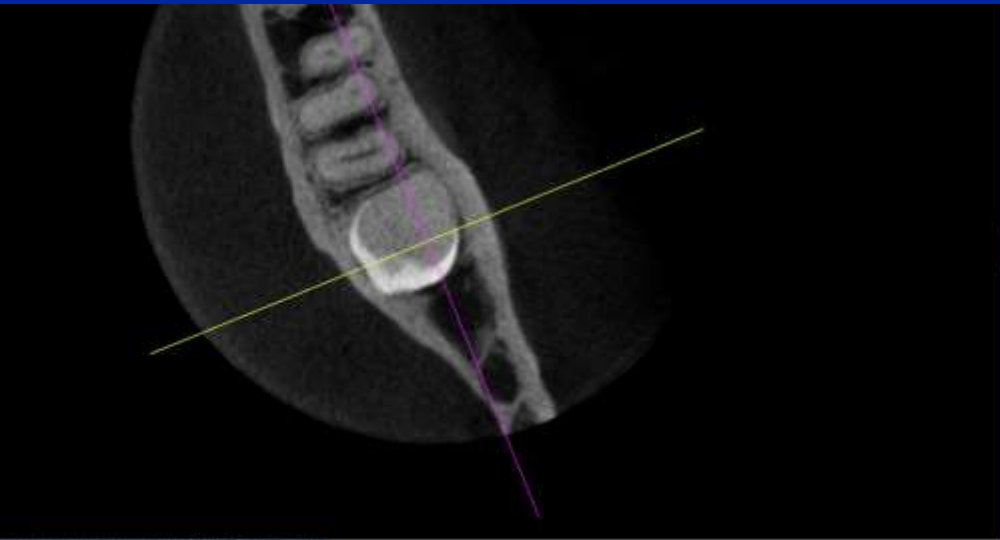
RA



CB

IMPLANT 36 DOULOUREUX

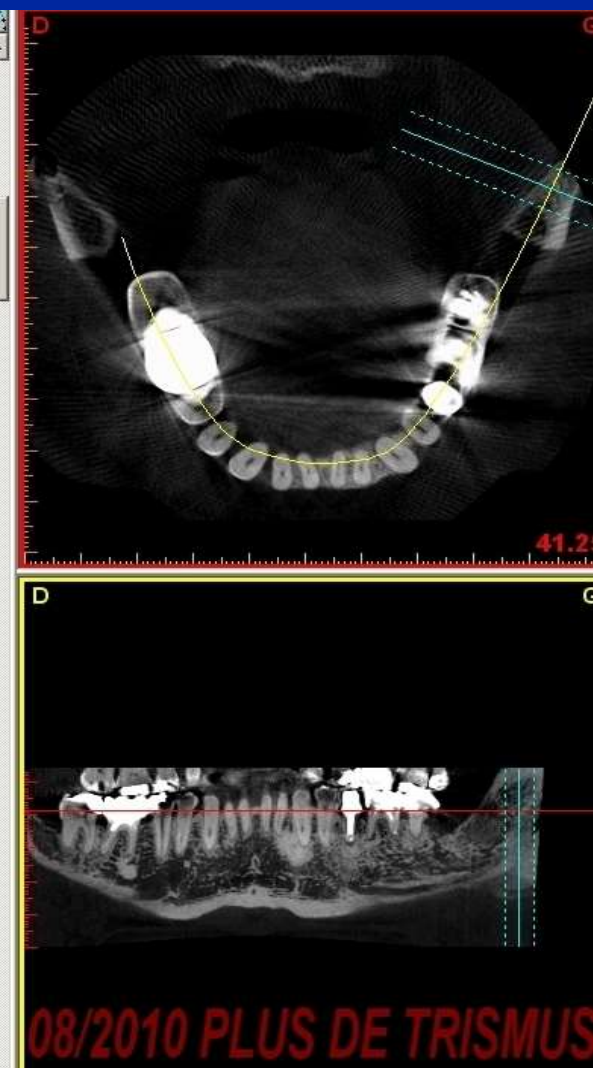
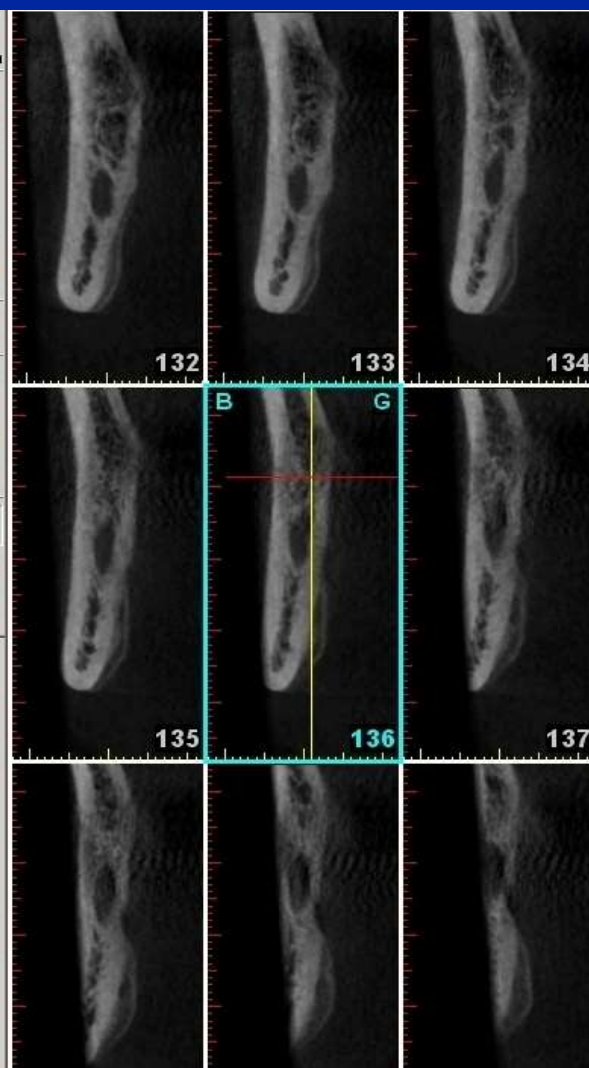
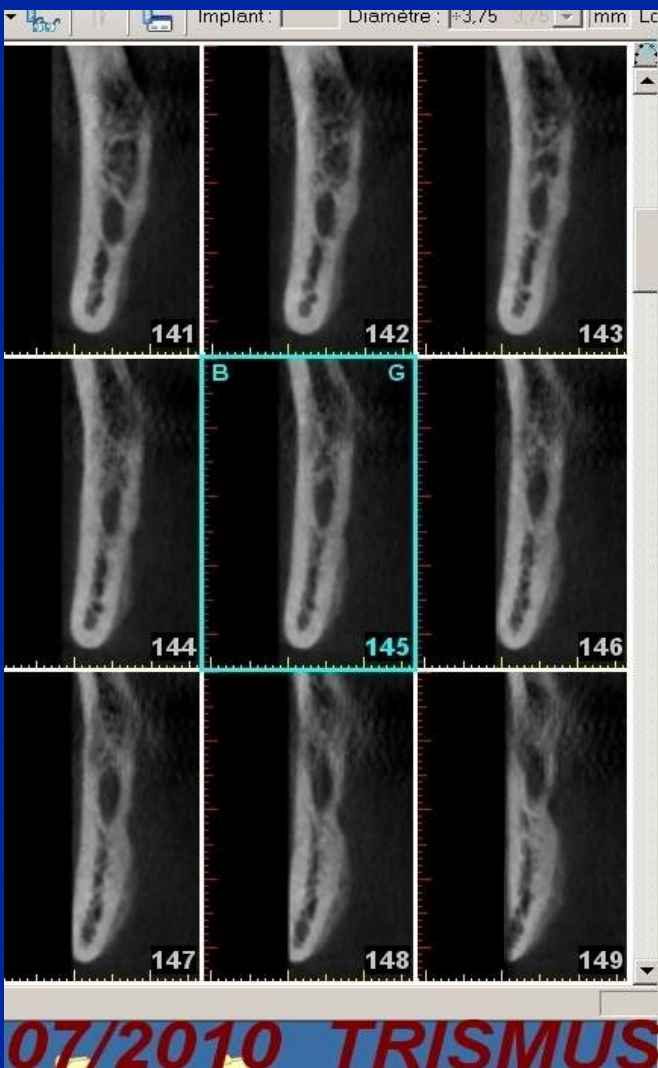
CONE BEAM ET OSTEITES DES MAXILLAIRES



OSTEITE SUBAIGUE DE 38 INCLUSE

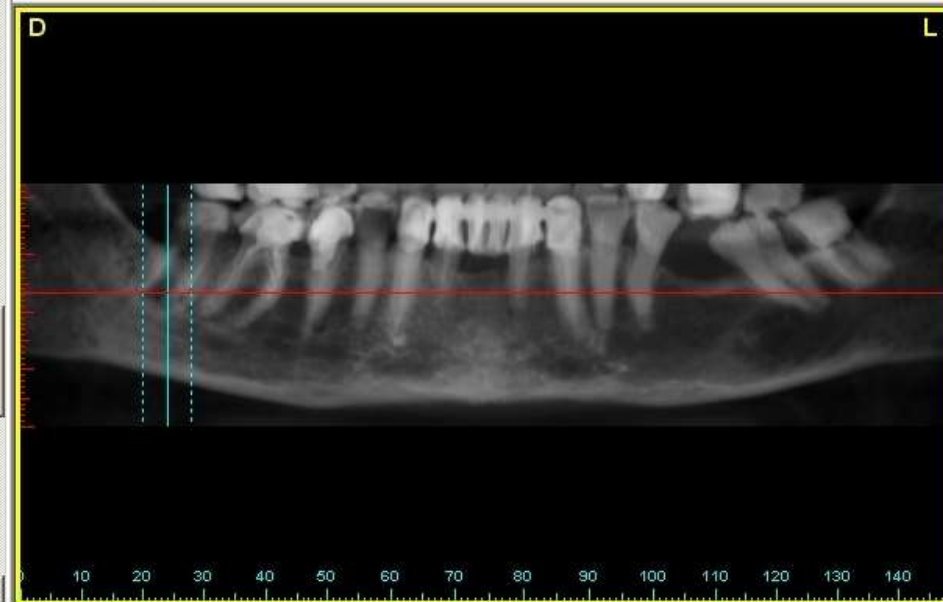
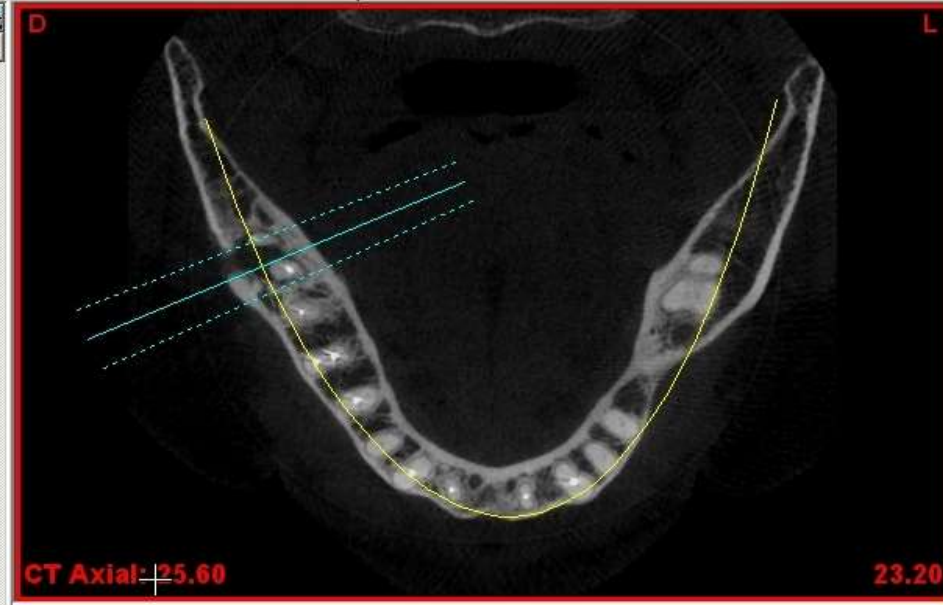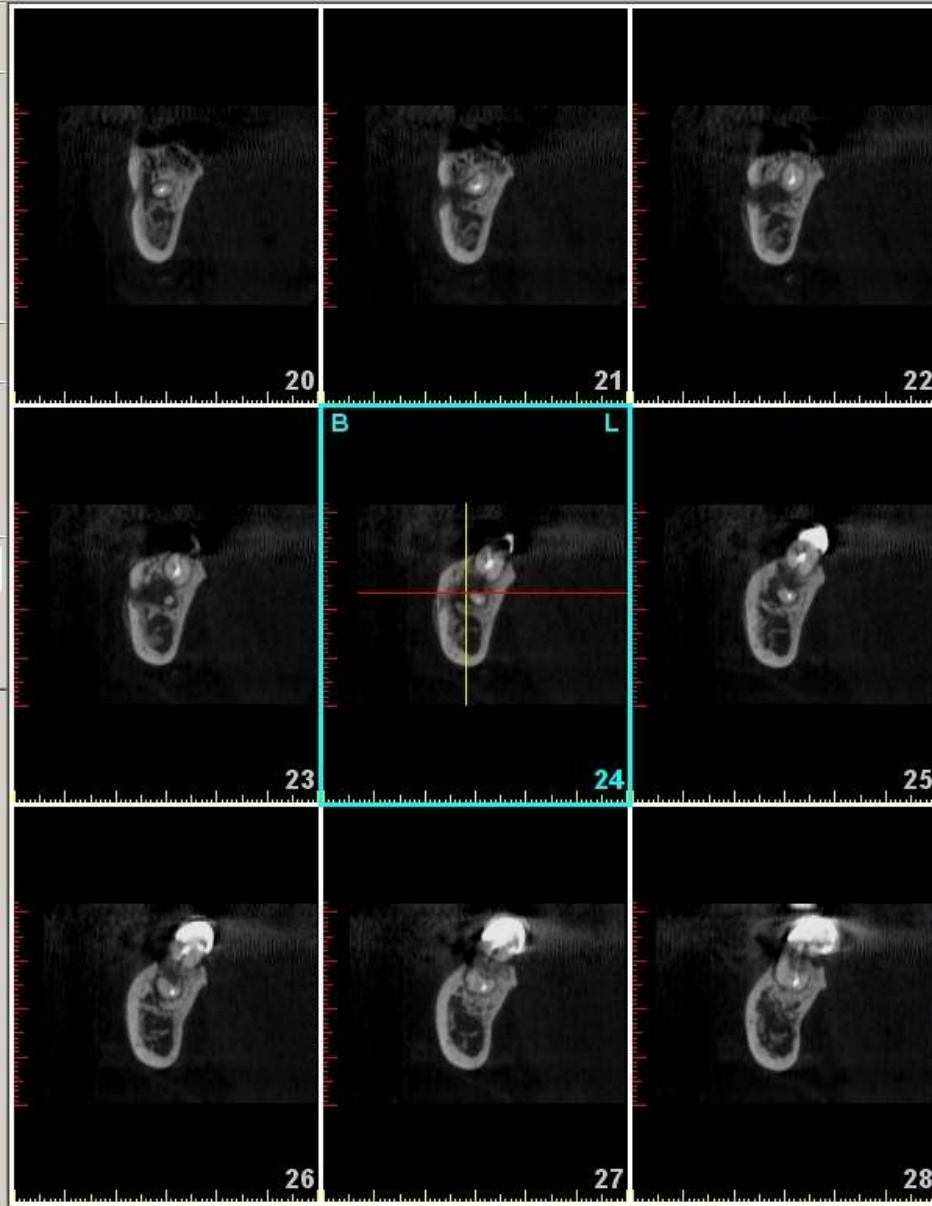
www.conebeamparis.com

CONE BEAM ET OSTEITES DES MAXILLAIRES

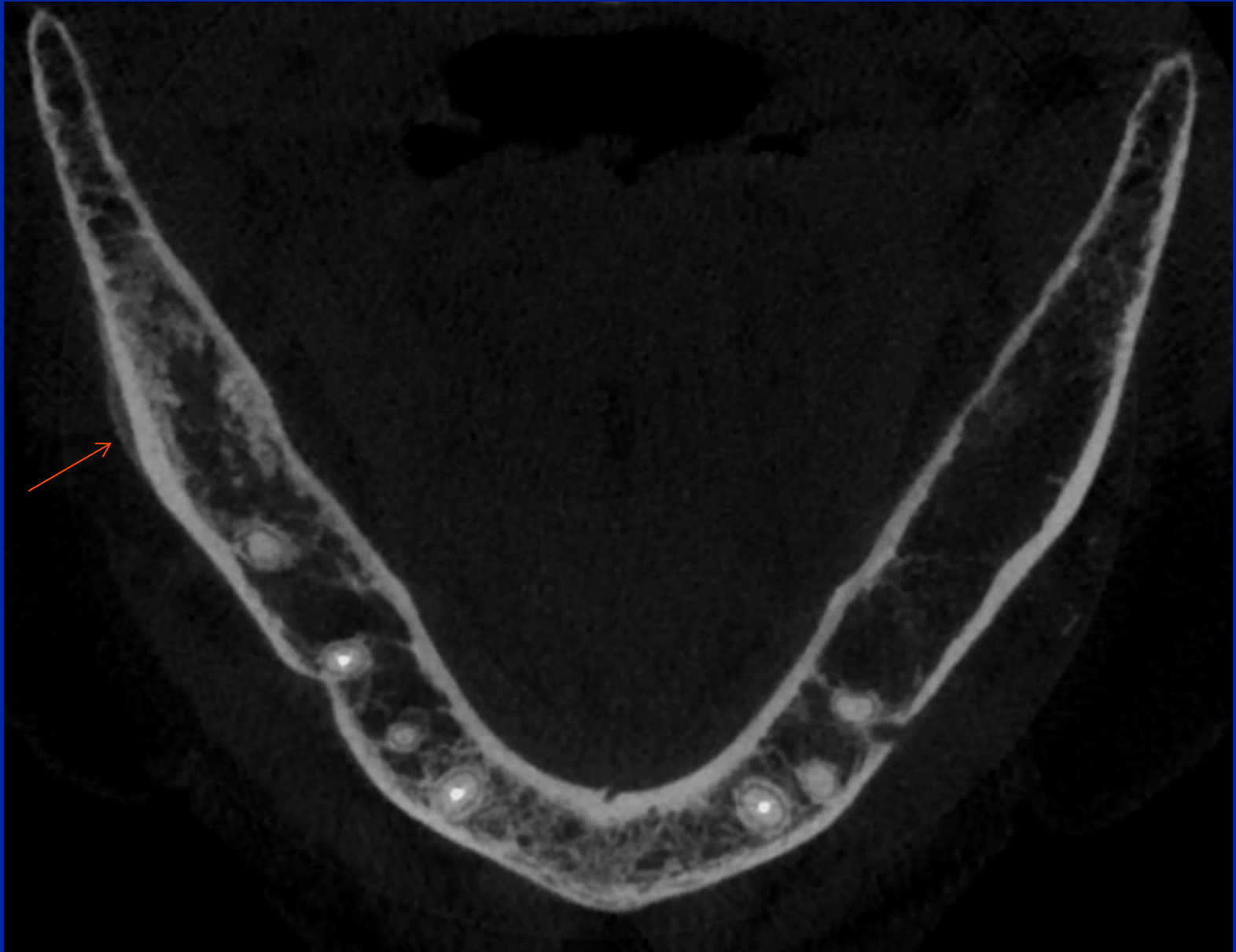


OSTEITE SUBAIGUE POST-EXTRACTIONNELLE DE 38

CONE BEAM ET OSTEITES DES MAXILLAIRES

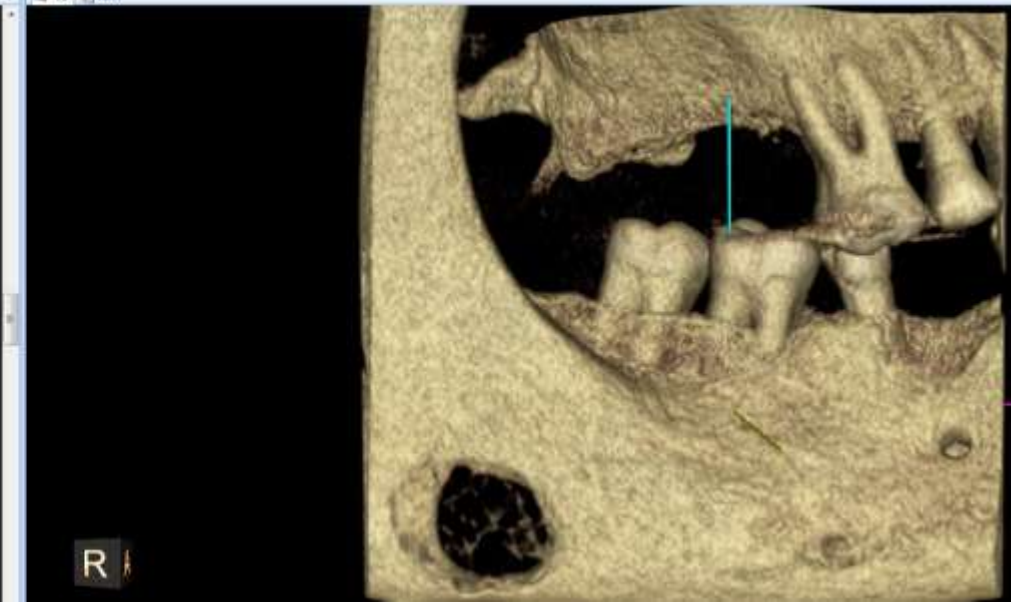
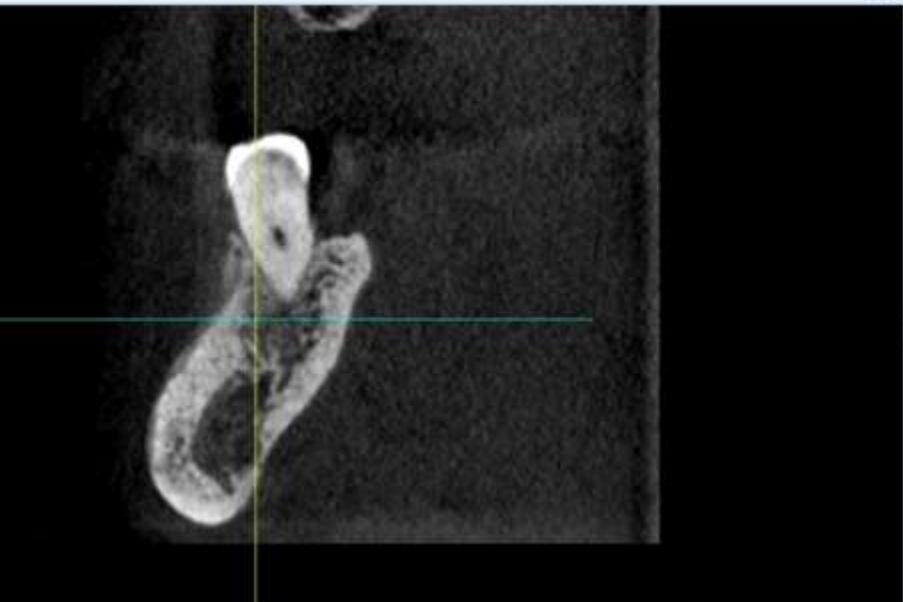
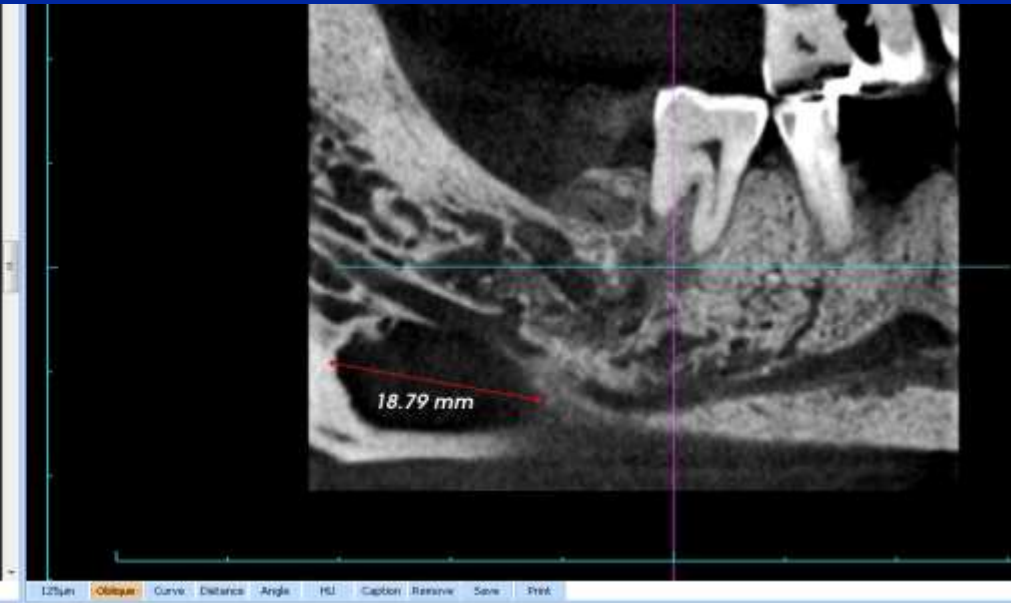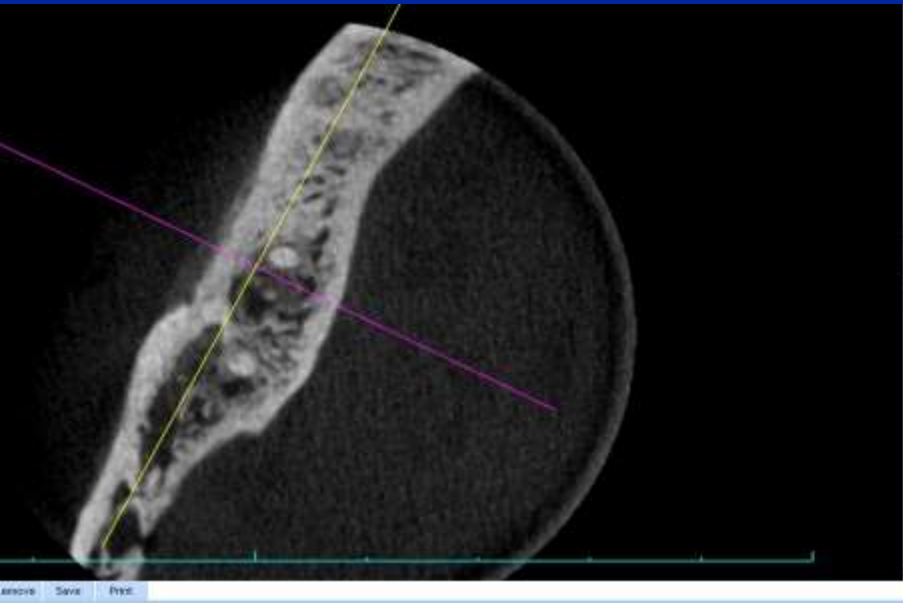


CONE BEAM ET OSTEITES DES MAXILLAIRES

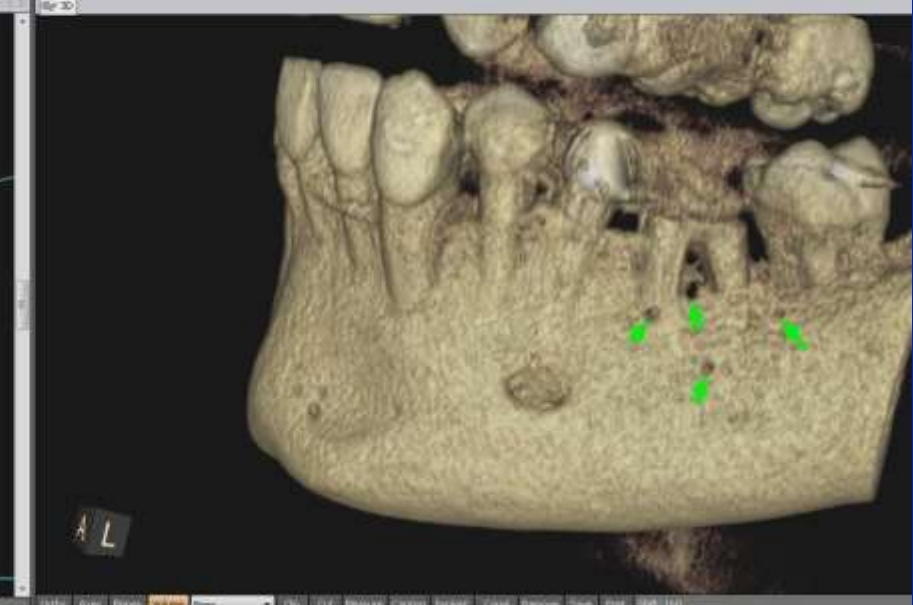
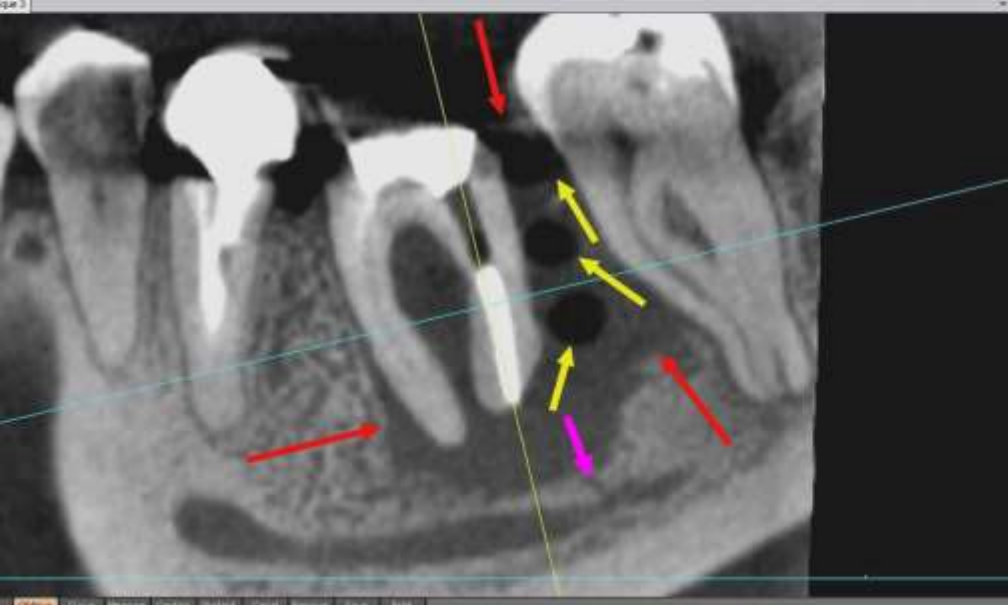
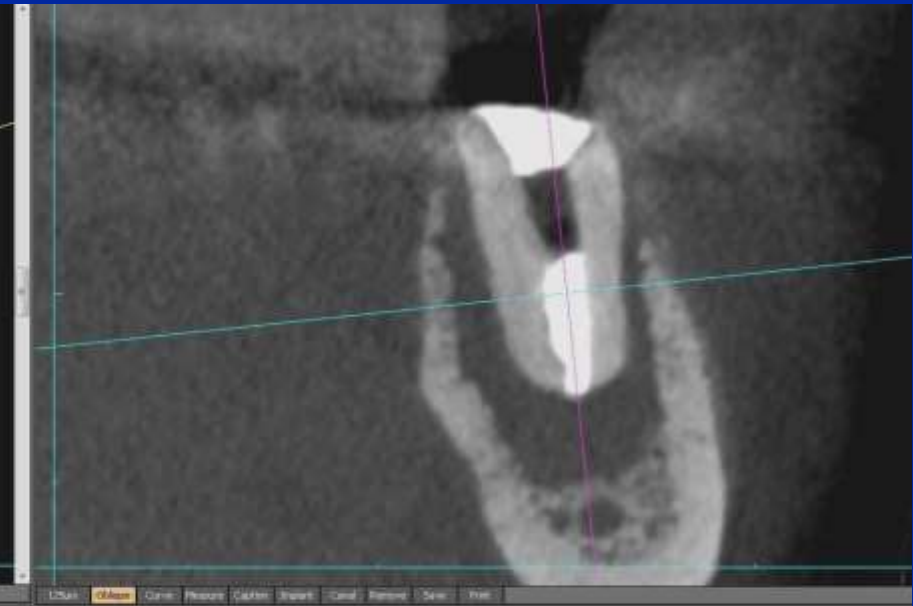
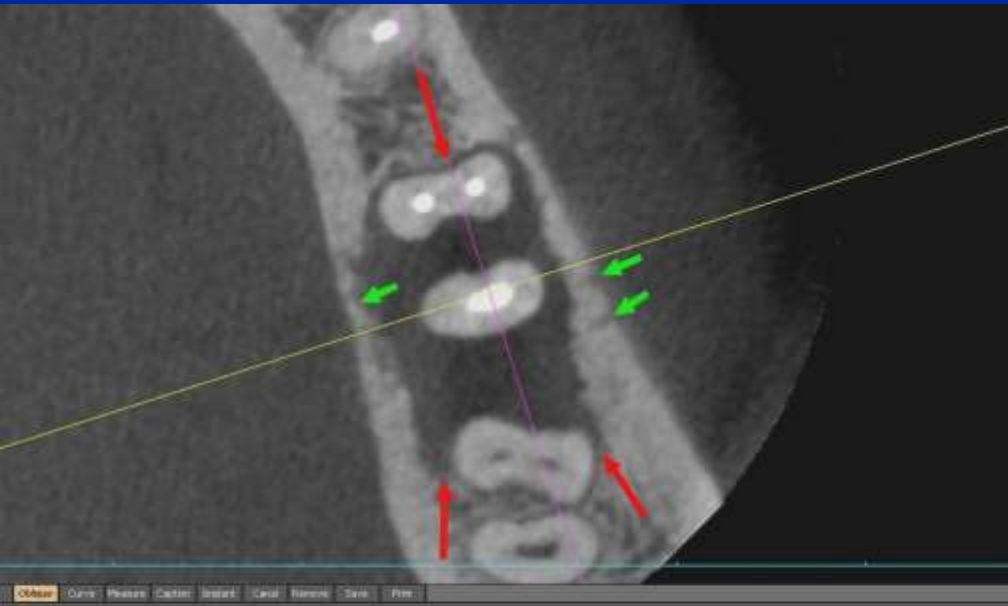

OSTEITE SUBAIGUE www.conebeamparis.com

CONE BEAM ET OSTEITES DES MAXILLAIRES



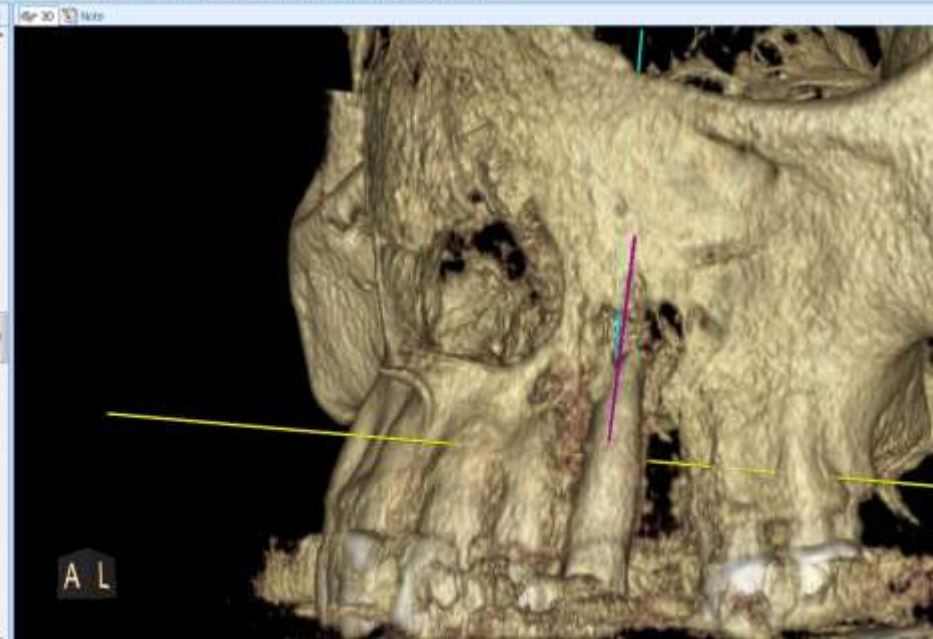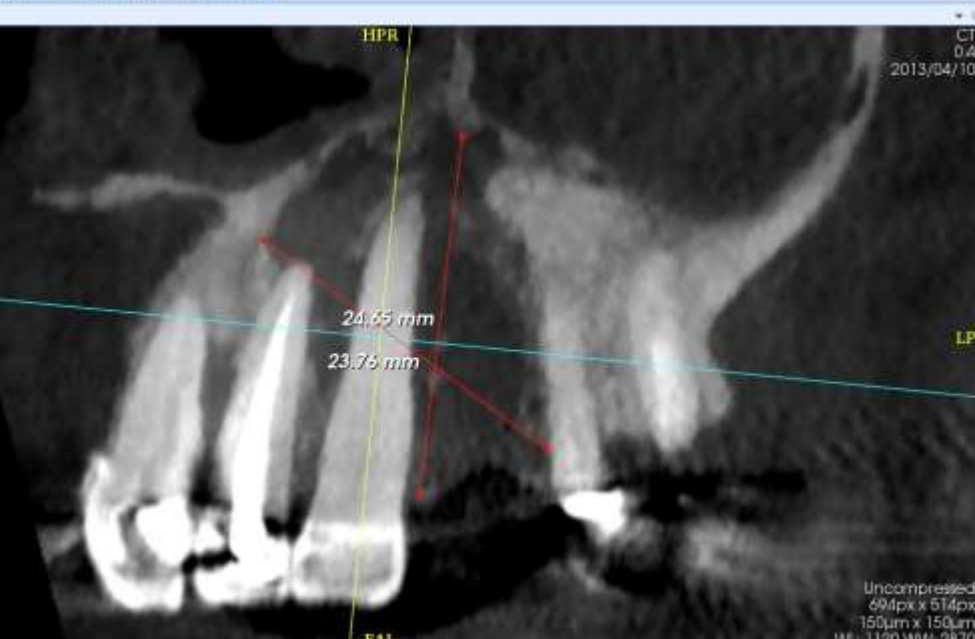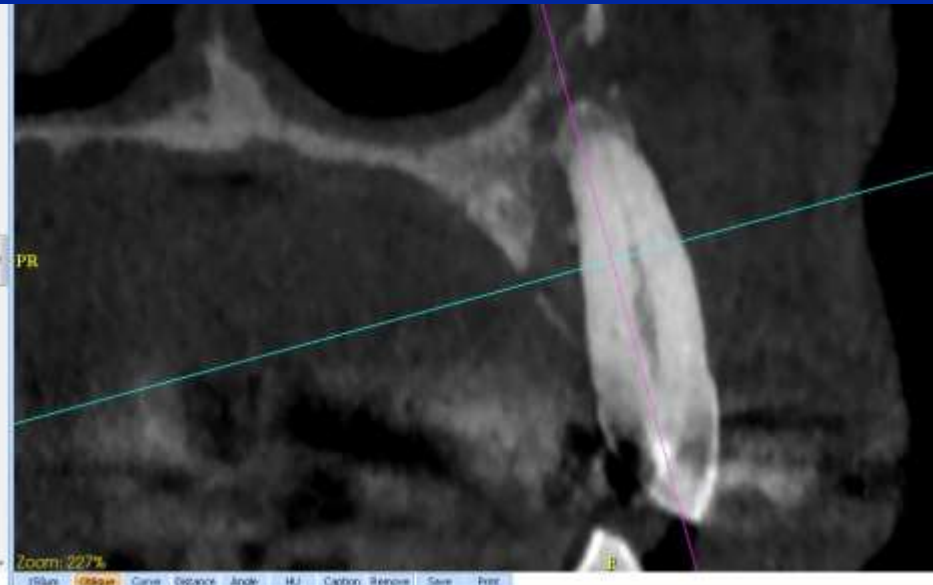
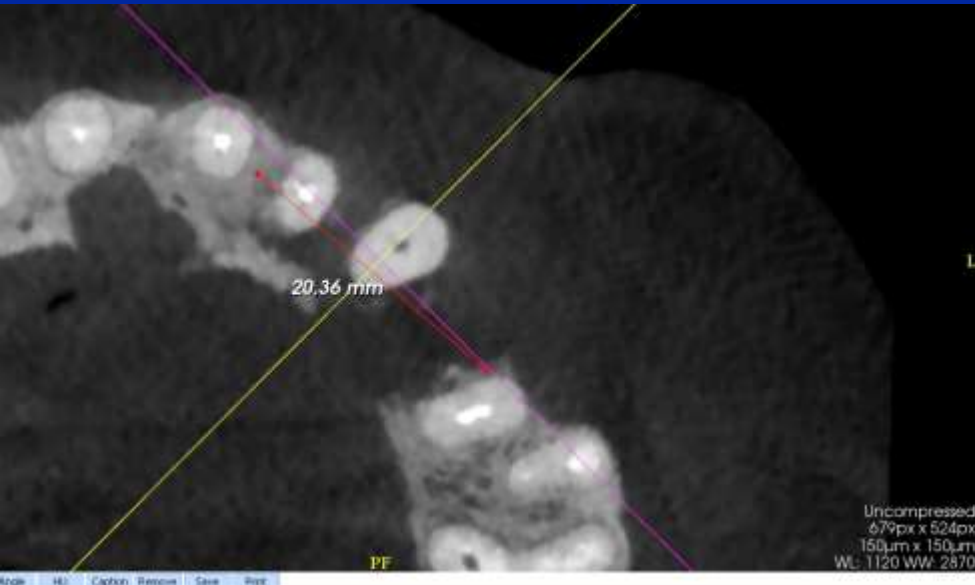
CONE BEAM ET OSTEITES DES MAXILLAIRES



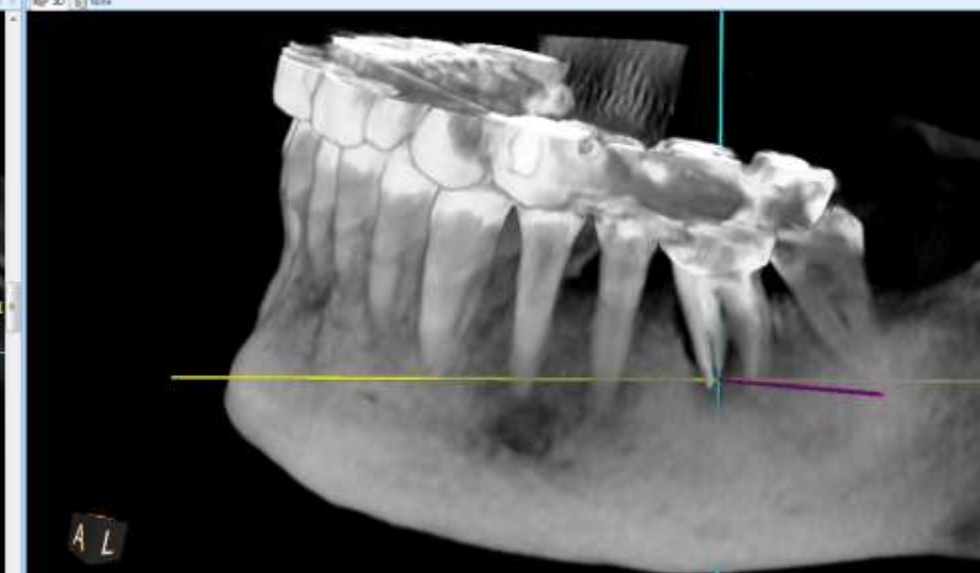
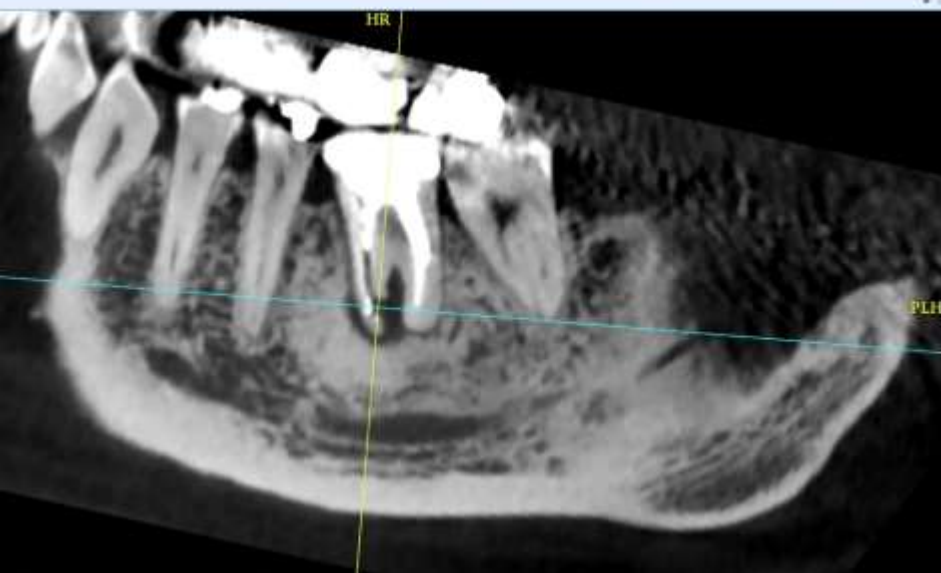
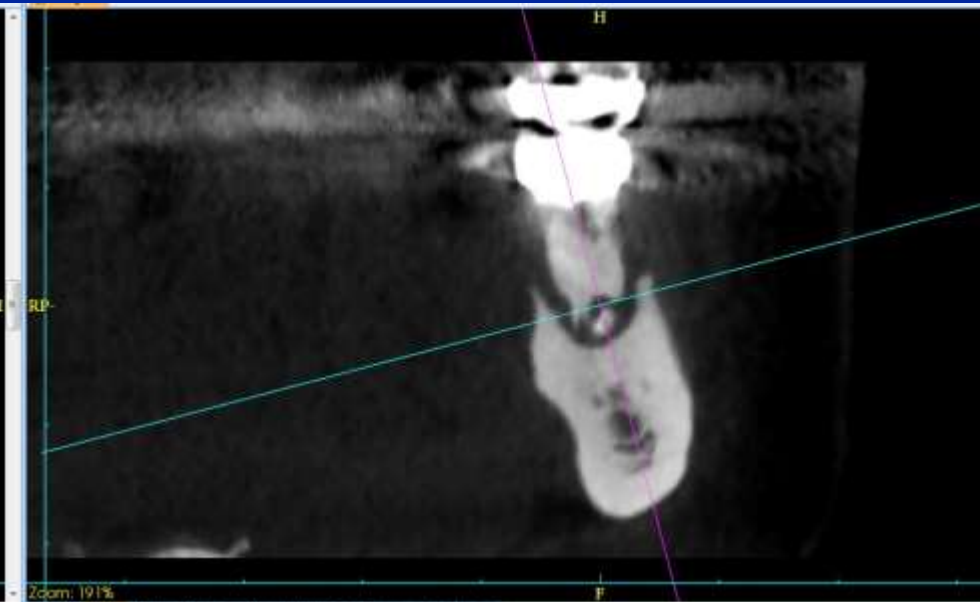
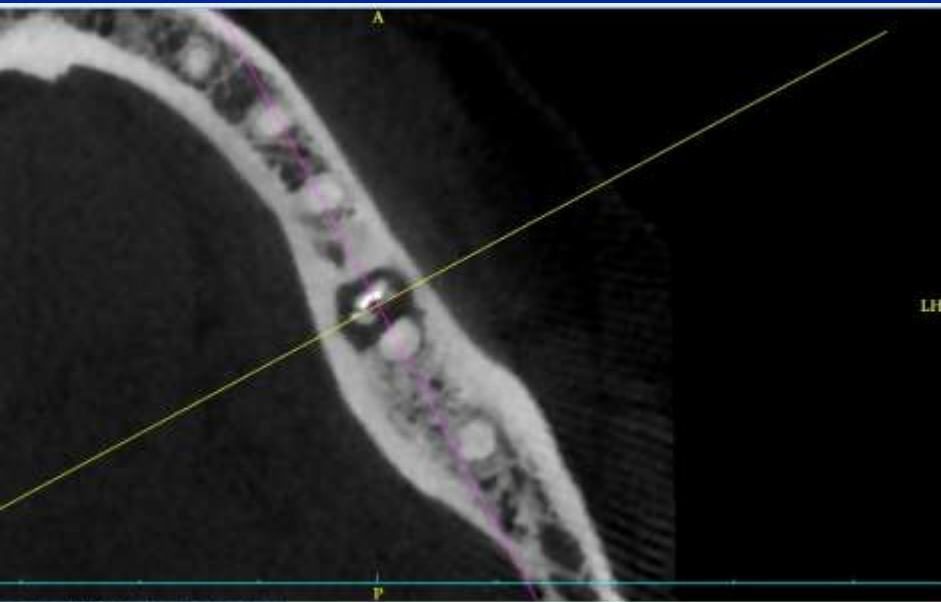
OSTEITE SURAIGUE

www.conebeamparis.com

CONE BEAM ET OSTEITES DES MAXILLAIRES



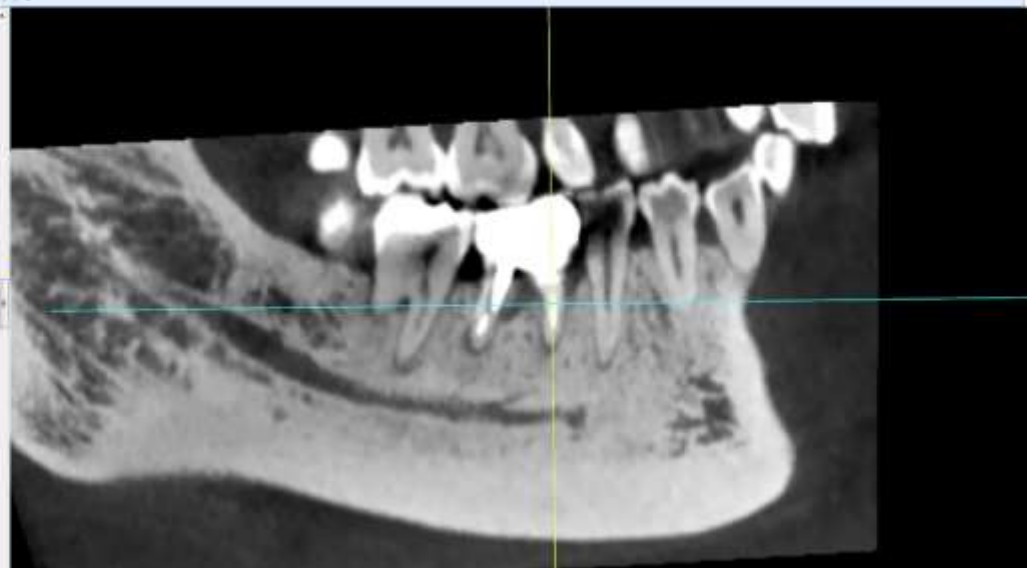
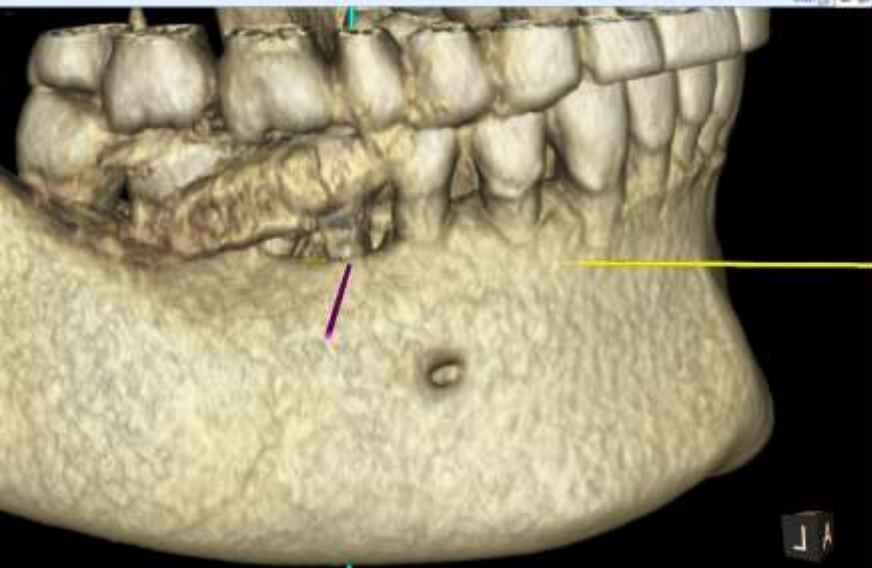
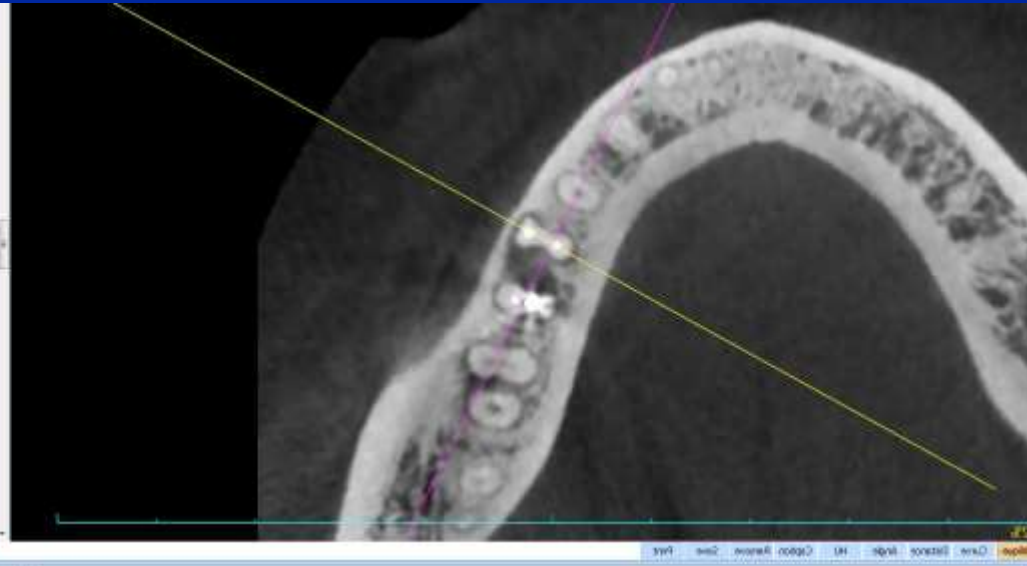
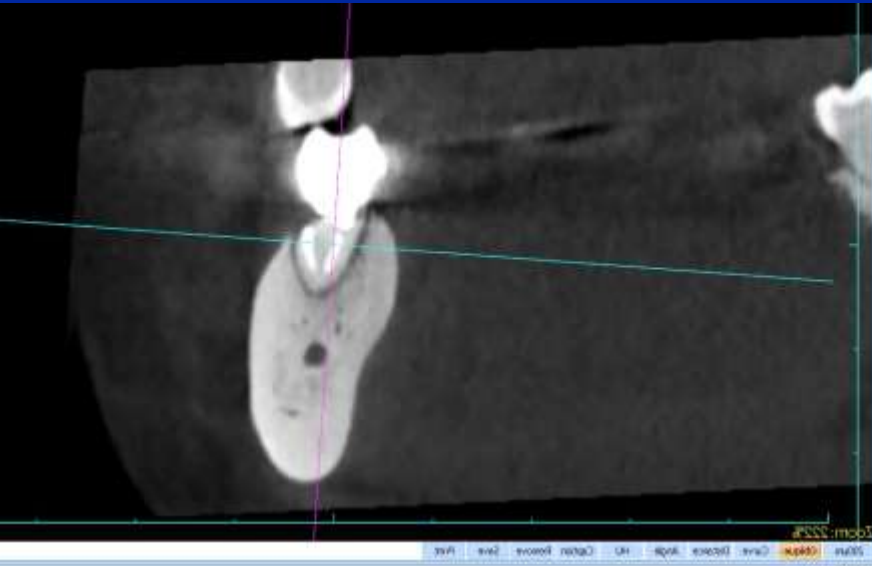CONE BEAM ET OSTEITES DES MAXILLAIRES



OSTEOSCLEROSE REACTIONNELLE

www.conebeamparis.com

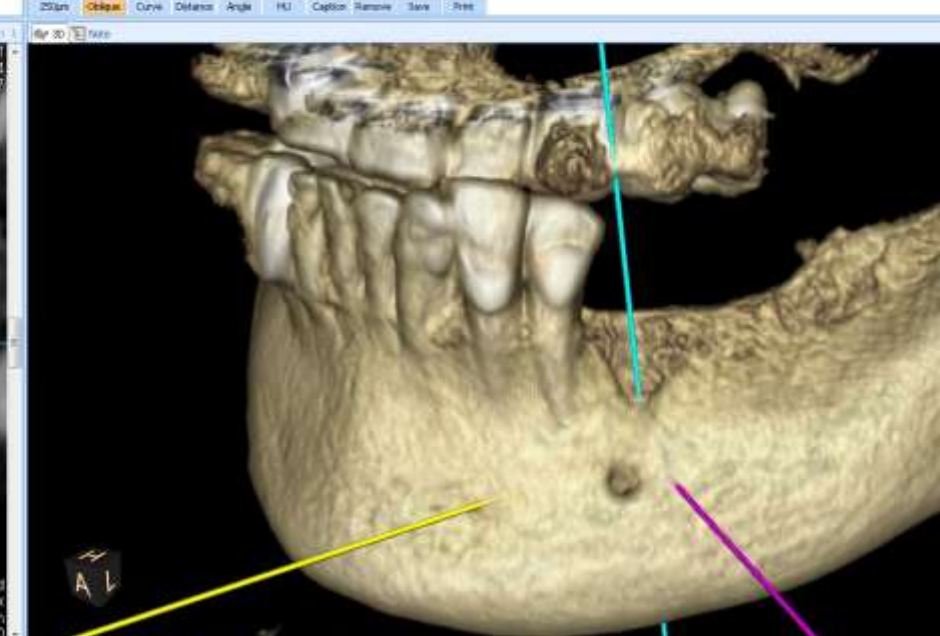
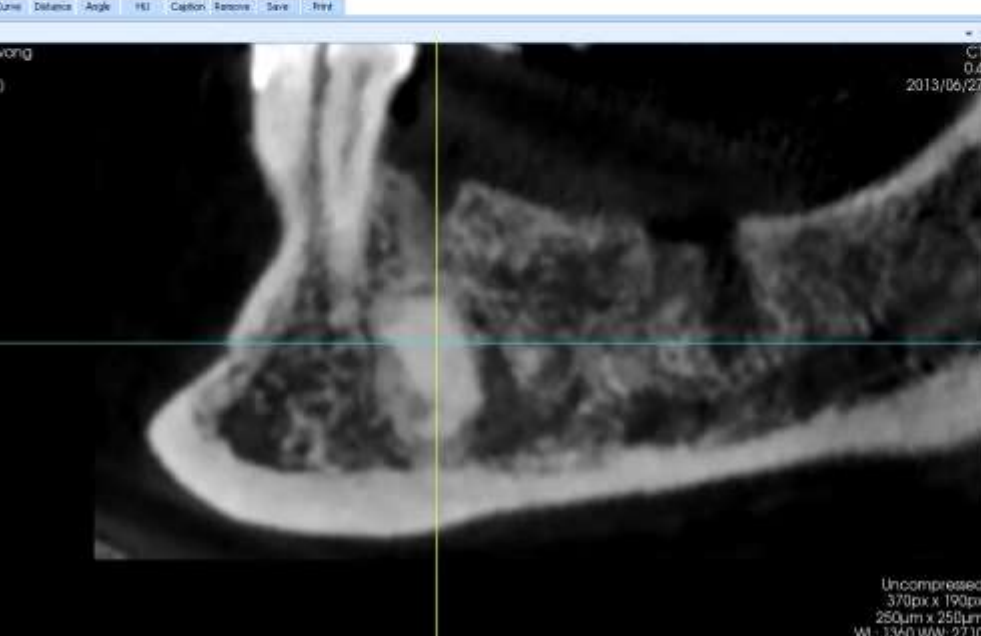
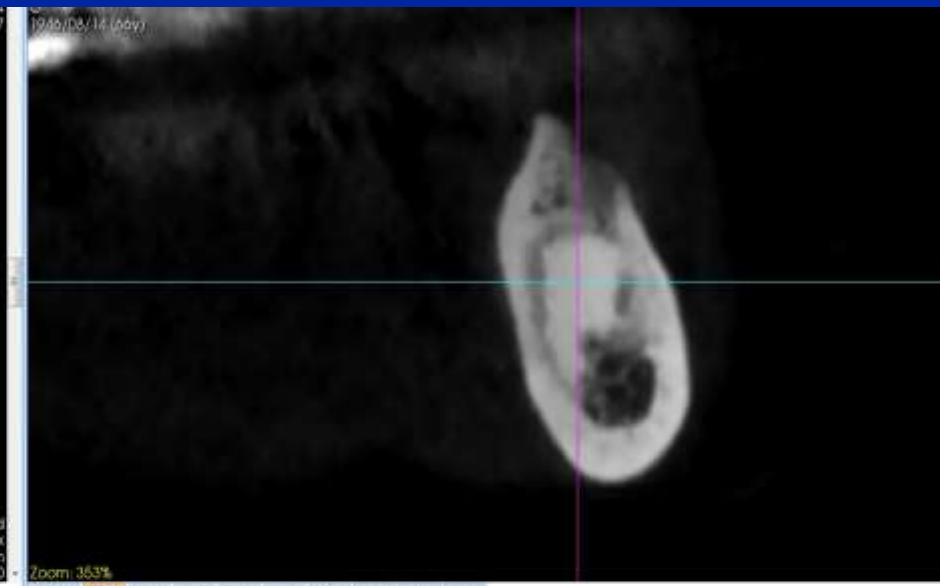
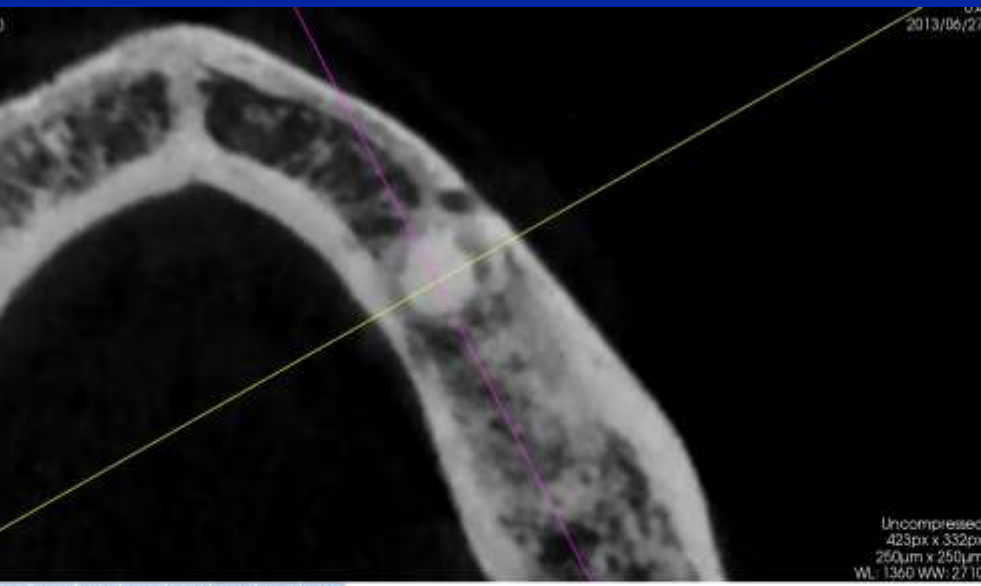
CONE BEAM ET OSTEITES DES MAXILLAIRES



OSTEOMMYELITE CHRONIQUE

www.conebeamparis.com

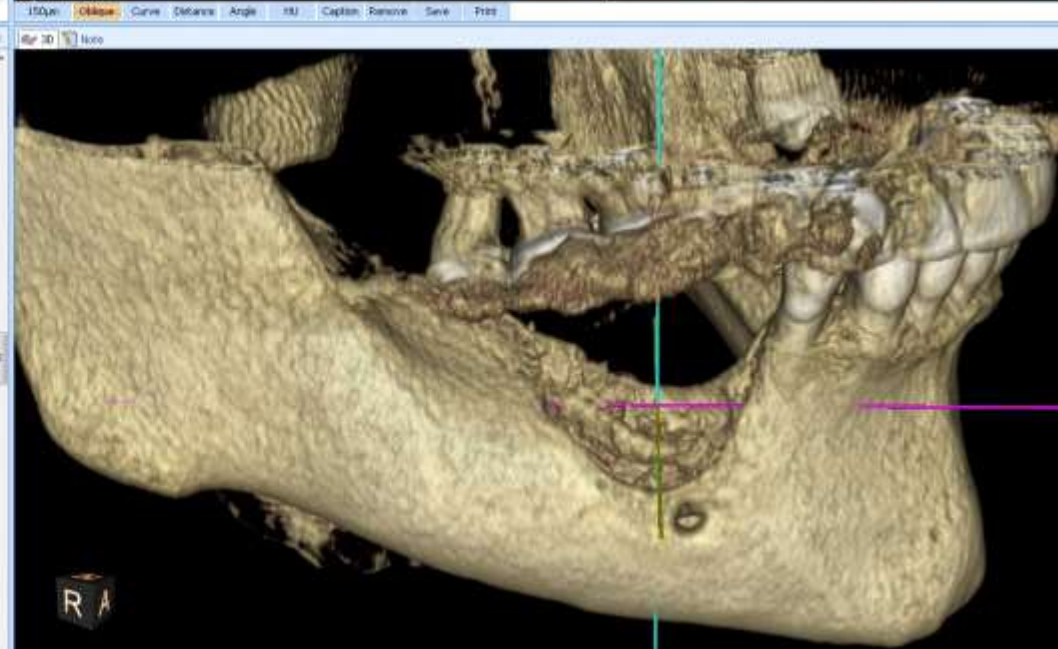
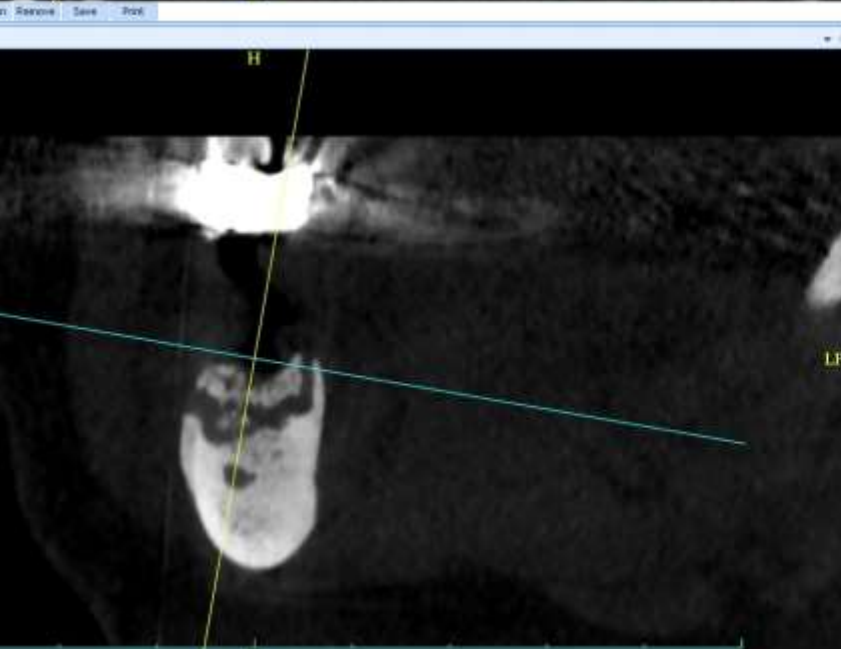
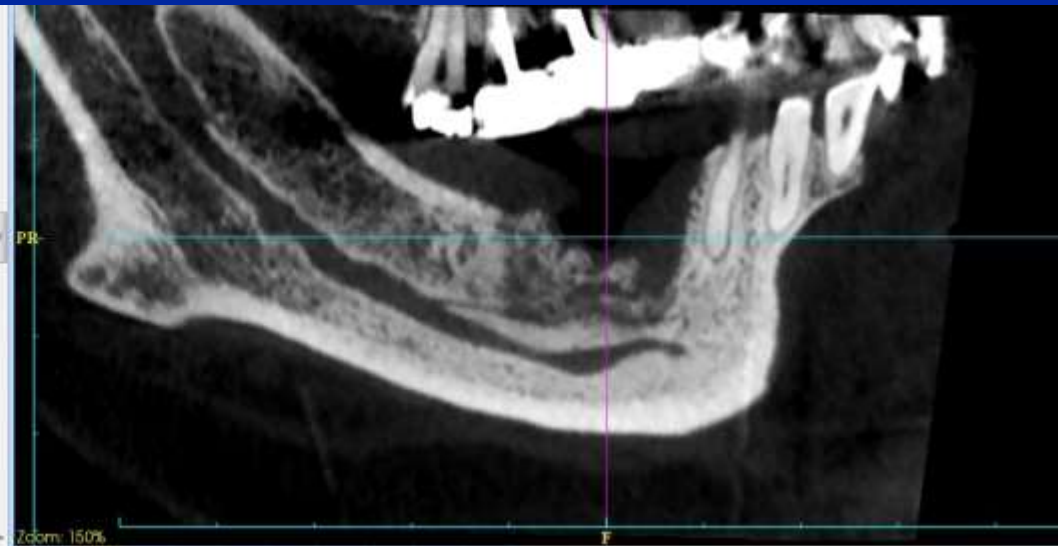
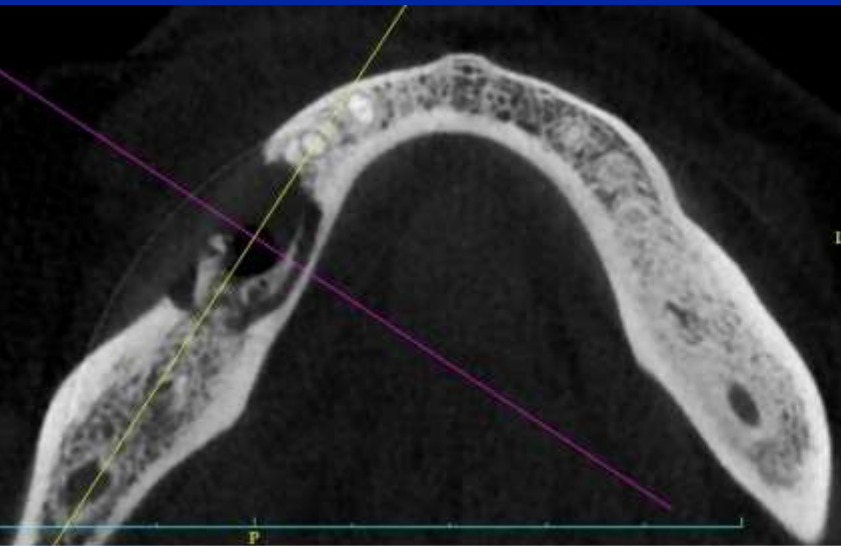
CONE BEAM ET OSTEITES DES MAXILLAIRES



OSTEOSCLEROSE RESIDUELLE ET ENOSTOSE

www.conebeamparis.com

CONE BEAM ET OSTEITES DES MAXILLAIRES



**DIAGNOSTIC DIFFERENTIEL DES OSTEITES:
OSTEONECROSE ASEPTIQUE AUX BIPHOSPHONATES**

www.conebeamparis.com